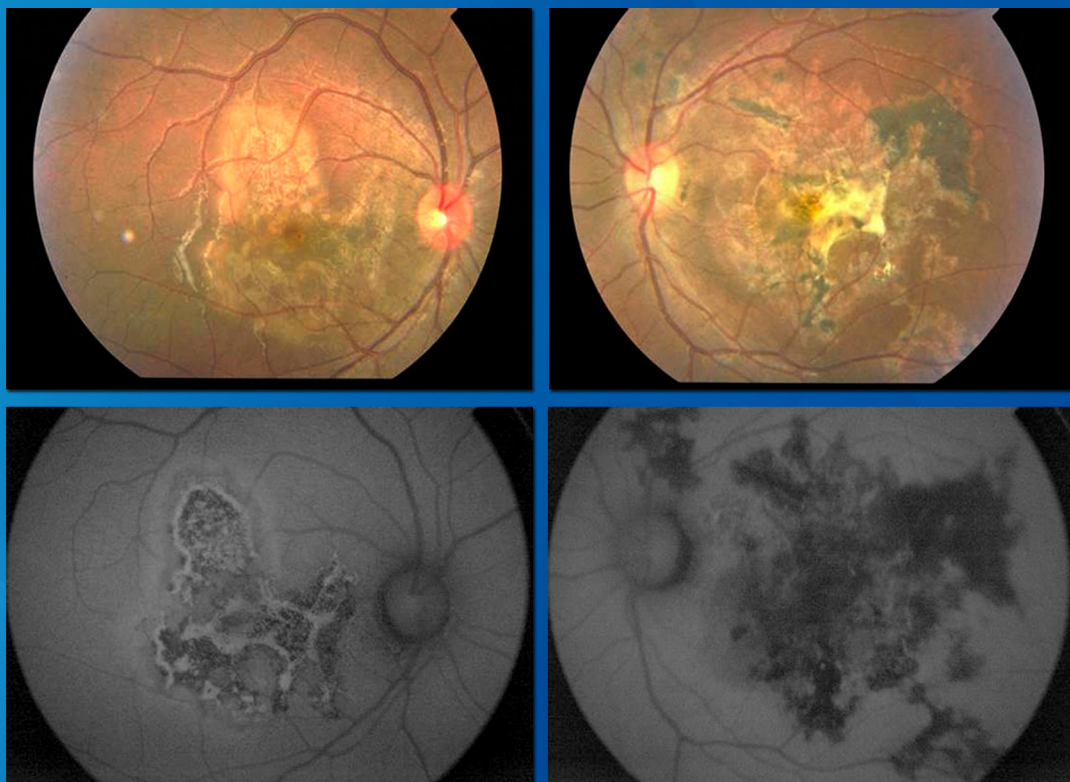




Uveitis Society (India)

*Newsletter*

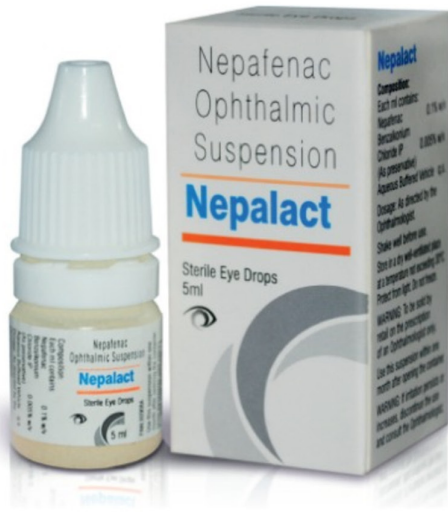

In Pain and Inflammation associated  
with Cataract Surgery

# Nepalact

Nepafenac Ophthalmic Suspension 0.1%

Novel Ocular NSAID



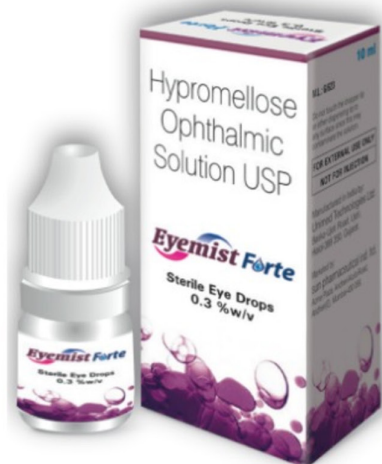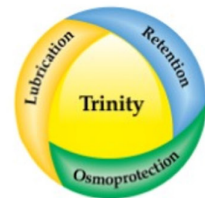
Acts Differently, Acts Effectively



In Chronic Dry Eyes, PRK and LASIK

# Eyemist Forte

HPMC 0.3 % + Dextran (70) 0.1 % + Glycerin 0.2 %



Longer Retention & Excellent Comfort





# Uveitis Society (India)

**NEWSLETTER**

**April 2019**

## **From the Desk of the President Dr. Vishali Gupta**



It gives me great pleasure in bringing out the first official newsletter from the Uveitis Society (India). As we all know, uveitis is the least taught and probably least understood subspecialty of Ophthalmology that is practiced by only handful of experts. One of the major objectives of the newly elected executive committee is to educate and impart knowledge about uveitis to the comprehensive ophthalmologists so that we can collectively manage this potentially blinding disease. To fulfill this objective, we are doing multiple CMEs at various places and have received very encouraging response with great participation. I would especially like to thank our very active secretary Manisha Agarwal who is working hard to organize the smooth conduct of these CMEs.

This Newsletter too is an attempt on our behalf to reach out not only to uveitis experts, but also to comprehensive ophthalmologists as well as ophthalmologists in training. Dr. Balamurugan has worked extremely hard to make it possible to take out the first issue of this newsletter and with the superb team to back him up, I am sure he will continue to take out these newsletters regularly in future. We are humbled by the responses from our mentors, past executive members, seniors and all other members who have taken time out of their busy schedules to contribute to the newsletter.

I sincerely hope that you enjoy reading it. We look forward to your comments and suggestions that shall help us in improving the quality. We would also request you to kindly forward the soft copy of this newsletter to all your students and colleagues so that we can achieve our aim of making Uveitis as one of the lead sub specialty.



# Uveitis Society (India)



**Dr. Narsing A Rao**  
Patron-in-Chief



**Dr. Vishali Gupta**  
President



**Dr. Kalpana Babu**  
Vice President



**Dr. Manisha Agarwal**  
Secretary



**Dr. Sudharshan S**  
Treasurer



**Dr. B Manohar Babu**  
Immediate Past President

## Executive Committee Members



**Dr. Amala E George**



**Dr. Shishir Narain**



**Dr. Padmamalini Mahendradas**

## Advisors



**Prof. Carl Herbort**



**Prof. Amod Gupta**



**Dr. Jyotirmay Biswas**



**Dr. S R Rathinam**



**Dr. Virender S Sangwan**



**Dr. Sudha K Ganesh**

## Scientific Committee Members



**Dr. Reema Bansal**



**Dr. Salil Mehta**



**Dr. S Balamurugan**

## Zonal Representatives

**Dr. Subina Narang – North**  
subina\_navya@yahoo.com

**Dr. Debashish Das - East**  
debashisdas@hotmail.com

**Dr. Samarendra - Central**  
karkhurs@gmail.com

**Dr. Navneet Mehrotra - West**  
navneetmeh@gmail.com

**Dr. Ankush Kawali – South**  
akawali332@gmail.com

## From the Editorial Desk...

Dear friends....

Under the aegis of Uveitis Society (India), we are happy to come out with the first edition of newsletter. It is a fruit of a wonderful teamwork that made things realistically possible. We thank all the contributors for meticulously taking up the task and completing the job in time. The reception of the felt topics in uveitis shall propel us to carry on the job to reach greater altitude in the course of time. We thank the felt-group audience who could critically comment on us to make it much better.

Please feel free to contact the editorial team for any queries and clarifications. We are glad to receive many more contributions from all the family members of Uveitis Society (India). It is true that we have all the resources that need to be channelized in a focussed direction to the benefit of the common cause of popularizing the wonderful field of uveitis. This shall translate into patient-centered care for sure!

Au revoir!

**Dr.S.Bala Murugan,**

Chief of Uveitis services,

Aravind Eye Hospital,

Pondicherry-605007

**Email:** drbalamuruganms@gmail.com



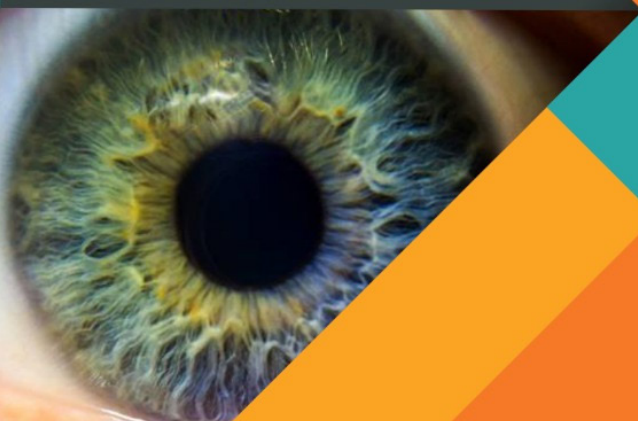## Upcoming CME



**“U WE YA”**

**SADGURU UVEA MEET -2019**  
**18<sup>th</sup> May, 2019**

This meet “U WE YA” ...wherein ya means you so this meet “YOU WE YOU” will be an interactive scientific meet which will benefit an Ophthalmologist to a great extent in dealing with day to day Uvea cases and also a view about some challenging aspects we face at times.



Dear Doctor,

All of us at Sadguru Netra Chikitsalaya are enthralled to extend you a cordial invitation for our very first UVEA Meet - 2019 & basic Uveitis course under the aegis of “Uvea Society of India”, to be held on 18<sup>th</sup> May 2019. The course will benefit the ophthalmologists in diagnosis & management of day to day Uvea cases.

Your Participation will be appreciated in an interactive session on research methodology on 17<sup>th</sup> May, 2019.

Looking forward eagerly for your participation.

Warm Regards,

**Dr. B. K. Jain**  
Director  
Sadguru Netra Chikitsalaya

## HIGHLIGHTS

- BASIC UVEITIS COURSE** Diagnostic Approach | Work up Management | Referral Decision for Comprehensive Ophthalmologist PG's & Fellows
- INTERACTIVE - CASE PRESENTATIONS**
- QUIZ FOR PG's**
- PRE CONFERENCE WORKSHOP ON RESEARCH METHODOLOGY**
- EVENING / TEA WITH PATRON PROF. AMOD GUPTA**

Prof. Vishali Gupta | Dr. Manisha Agrawal | Dr. Samendra Karkhur | Dr. Alok Sen  
President, USI | Hon. Secretary, USI | Exe. Zonal Member, USI | MS, SNC



**Uveitis Society (India)**

# USICON 2019

**19TH ANNUAL CONFERENCE OF  
UVEITIS SOCIETY OF INDIA**

**20TH - 22ND SEPTEMBER  
SHERATON GRAND BANGALORE HOTEL  
AT BRIGADE GATEWAY**

**Bengaluru**

[www.indianuveitis.org](http://www.indianuveitis.org)  
[usi2019blr@gmail.com](mailto:usi2019blr@gmail.com)

welcome to  
**Karnataka**  
One state. Many worlds.

AN AMALGAMATION OF RICH HISTORY  
& MODERN TECHNOLOGY



## Contents

Sl No	Topic	Author	Page No.
1	<b>Challenging case scenarios!</b> Resolved bilateral tubercular vasculitis, now unilateral persisting anterior uveitis - what will you do?	Dr. Ankush Kawali	07
2	<b>Rarity does not rule out the diagnosis!</b> Lupus Choroidopathy	Dr. Ankush Kawali Dr. Jaya Vohra Dr. Padmamalini Mahendradas	11
3	<b>Hot! Hotter! Hottest! Panel discussion on a felt topic in uveitis!</b>		15
	TB or not TB! A never ending enigma by the eminent stalwarts in practice...	Prof. Jyotirmay Biswas Prof. S.R.Rathinam Prof. Amod Gupta Prof. Vishali Gupta Prof. Soumyava Basu	
4	Kaun Banega Uveopathy! Quiz-Take five!	Dr. Parthoprati Dutta Majumder	27
5	Delineating the differential! CSCR versus Serous RD	Dr. Anand Rajendran Dr. Eliza Anthony	29
6	Journal scan! Necrotizing scleritis	Dr. S Bala Murugan	37
7	Smart study in short time! Constellation of diagnostic criterias in uveitis	Dr. Bharat Gurnani Dr. Annamalai Odaiappan Dr. S.Bala Murugan	55
8	CME Program		68
9	Answers to Quiz		73



## **Title**

**Resolved bilateral tubercular  
vasculitis, now unilateral  
persisting anterior uveitis -  
what will you do?**

**Author: Dr. Ankush Kawali**  
*Consultant - Narayana Nethralaya  
Bengaluru*

## Resolved bilateral tubercular vasculitis, now unilateral persisting anterior uveitis- what will you do?

A systemically healthy 41-year-old gentleman, with positive Mantoux (13mm) and quantiferon TB gold test was treated as bilateral tubercular occlusive vasculitis with oral steroids and 9 months course of Anti-tubercular therapy (ATT) and also underwent Pan-Retinal Photocoagulation (PRP) for both the eyes. (Figure 1a, b) After 5 months of ATT, Azathioprine was added as a steroid sparing agent as the inflammation was persisting. Eventually, his vasculitis resolved, best corrected visual acuity (BCVA) vision improved from 20/60 to 20/20 in OU and steroids were discontinued. At 14<sup>th</sup> month of his initial presentation while still on Azathioprine, on a regular follow up visit, patient was found have few medium sized keratic precipitates (KPs) in his left eye. (Figure 2 a, b, c) Repeated fundus fluorescein angiography (FFA) did not show active vasculitis. BCVA was 20/20, intraocular pressure (IOP) was normal, patient had white eye, 1+ cells in anterior chamber, normal iris pattern, clear lens, 0.5 vitritis and status post PRP with resolved vasculitis in OS. Examination of OD was unremarkable with evidence of resolved vasculitis. Patient had no fresh complaints neither ocular nor systemic and reported doing well with Azathioprine monotherapy.

What would you do next?

- A. Anterior chamber tap for viruses (HSV, VZV, CMV) and Mycobacteria Tuberculosis
- B. Serum Angiotensin converting enzyme (Sr. ACE) and high-resolution computer tomography (HRCT) of chest
- C. Restart steroids and increase dose of Azathioprine
- D. Observe closely

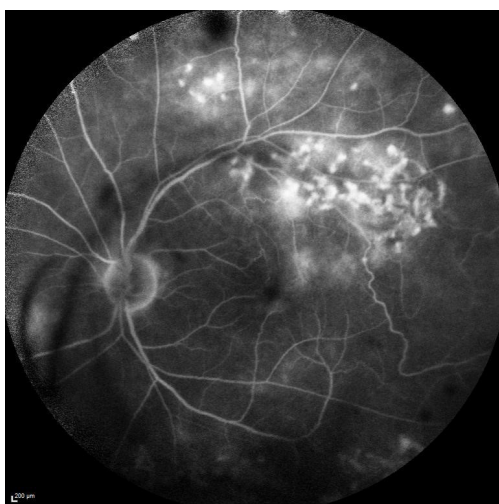


Figure - 1a

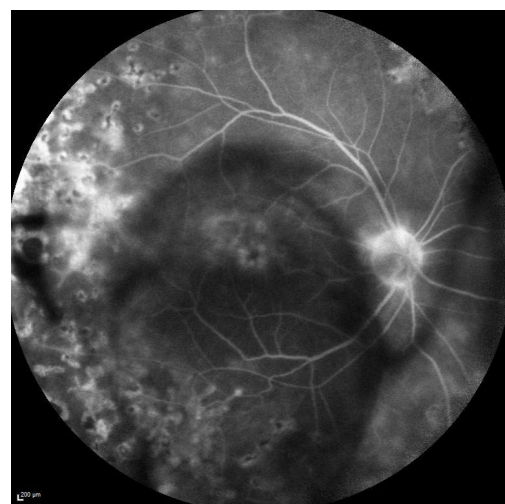


Figure - 1b

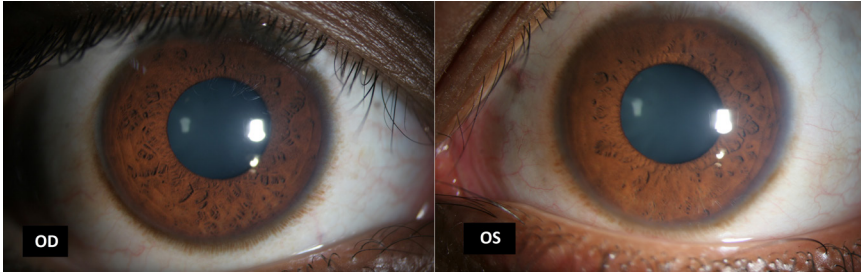


Figure - 2 a & b

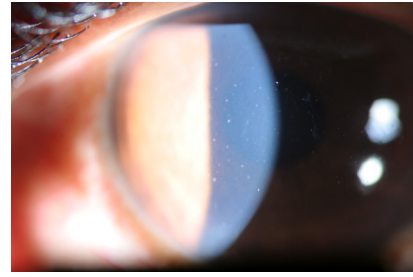


Figure - 2 c

**Answer and explanation:**

Ideally, anterior chamber (AC) tap, to rule out viral (HSV, VZV, CMV) and mycobacterial infections by PCR, Serum ACE and HRCT-chest should be done. Our patient declined proposed AC tap procedure but agreed for plan B. Sr. ACE and HRCT chest were normal. As the patient was asymptomatic, we opted for plan D. Patient was followed up closely on Azathioprine. Repeated subsequent FFA revealed no vascular leakage. Iris infrared autofluorescence (IR-AF) showed subtle alteration of iris pattern in the affected eye. (Figure 2 d) Diagnosis of evolving Fuchs' uveitis (FU) in OS on the background of resolved bilateral vasculitis was considered. Azathioprine was gradually tapered off. KPs, cellular reaction in AC and vitreous remained unchanged after 26 months of follow up and patient remained asymptomatic confirming the diagnosis of Evolving Fuchs' uveitis.

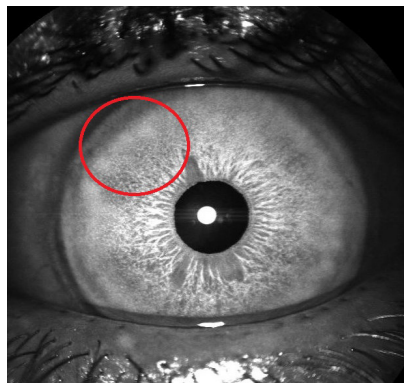


Figure - 2 d

**Discussion:**

It is now known that in FU characteristic iris heterochromia described in Caucasian population is not evident in pigmented races. But still subtle iris atrophic changes compared to healthy eye can be identified by a vigilant ophthalmologist. Perhaps, near IR-AF could possibly a new technique to demonstrate subtle subclinical changes of iris in FU.<sup>2</sup> Tappeiner et al studied FU in children and concluded that characteristic features of FU may not be present at onset of the disease and iris changes could be a sign of chronicity.<sup>3</sup> In our case iris atrophic changes were absent clinically but were picked up by iris

IR-AF. (Figure 2) Other typical features of FU such as diffuse microgranulomatous KPs, mild-moderate AC reaction and cataract can also remain absent initially or KPs may even disappear during follow up or with high dose steroid treatment.<sup>1,4</sup> Our case was not on any treatment before presentation to us, hence ruling out pre-existing FU with masking effects of steroids over KPs.

Although our case did not undergo PCR study of aqueous, we feel isolating a virus would have not changed course of the disease and the management in our case. The diagnosis of FU remains based on its phenotype and the course of the disease regardless viral etiology.

To conclude, evolving FU is a diagnostic challenge and may led to mismanagement. We suggest a conservative approach in otherwise asymptomatic patients with white eye, mild to moderate vitreous inflammation without pars planitis, absent posterior synechiae and normal fundus examination or fundus examination suggestive of resolved uveitis. Such cases can be observed closely without treatment, after ruling out subclinical retino-choroidal inflammation (not suggestive of FU) with imaging and then allowing FU to evolve. Inflammation in full-fledged FU remains stable and so does patient's symptoms unless explained otherwise. This approach for evolving FU will prevent unnecessary investigations and treatment which otherwise will require cataract and/or glaucoma management only.

#### **References:**

1. Bouchenaki N, Herbort CP. Fuchs' Uveitis: Failure to Associate Vitritis and Disc Hyperfluorescence with the Disease is the Major Factor for Misdiagnosis and Diagnostic Delay. *Middle East African Journal of Ophthalmology*. 2009;16(4):239-244.
2. Liu Q, Jia Y, Zhang S et al. Iris autofluorescence in Fuchs' heterochromic uveitis. *Br J Ophthalmol*. 2016; 0: 1-6.
3. Tappeiner C, Dreesbach J, Roesel M et al. Clinical manifestation of Fuchs uveitis syndrome in childhood. *Graefes Arch Clin Exp Ophthalmol*. 2015 Jul;253(7):1169-74.
4. A Kawali, A Ayyar, A Ahuja et al. Topiramate-induced hypertensive uveitis and evolving Fuchs' uveitis: A case report. *JCOR* 2016. 4 (1), 46-8.



**Title**

# **Lupus Choroidopathy**

**Author: Dr. Ankush Kawali**

*Consultant - Narayana Nethralaya*

*Bengaluru*

## Lupus Choroidopathy

**Authors:** Ankush Kawali, Jaya Vohra, Padmamalini Mahendradas.

**Case report:** A 25-year-old lady was referred to us as a case of steroid induced giant central serous chorio-retinopathy (CSCR). At presentation she complained of painless blurring of vision in both eyes for 3 weeks. Patient was a known case of systemic lupus erythematosus (SLE) with Antiphospholipid antibody syndrome (APS) and lupus nephritis. Patient was on T. Mycophenolate Sodium 360mg BD, T. Hydroxychloroquine (HCQ) 200mg OD, ecosprin 75mg OD and oral steroids (T. Prednisolone) 20mg OD.

On examination best corrected visual acuity (BCVA) was CF@1/2 mts in OU and IOP was 15mmHg and 20mmHg in OD and OS respectively. Blood Pressure was 150/90mmHg. Patient also gave history of generalized tonic clonic seizure started 3 weeks back for which she was on phenytoin 300mg OD.

Ocular examination revealed normal anterior segment, clear anterior vitreous face, but fundus examination showed mild blurring of disc margin, few retinal hemorrhages, multiple yellowish subretinal placoid lesions in OU with shallow subretinal fluid in OD and a large inferior exudative retinal detachment (ERD) in OS. (Fig 1 a, b) Following Differential diagnoses were considered: 1. Lupus choroidopathy, 2. Hypertensive choroidopathy, 3. Infectious (Tubercular) choroiditis in immunocompromised, 4. ERD secondary to protein losing nephropathy, 5. Posterior scleritis 6. Atypical CSCR.

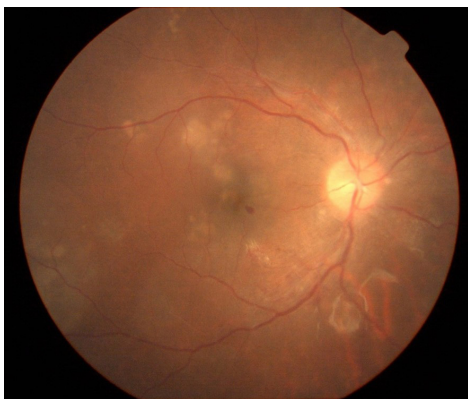

Figure - 1a

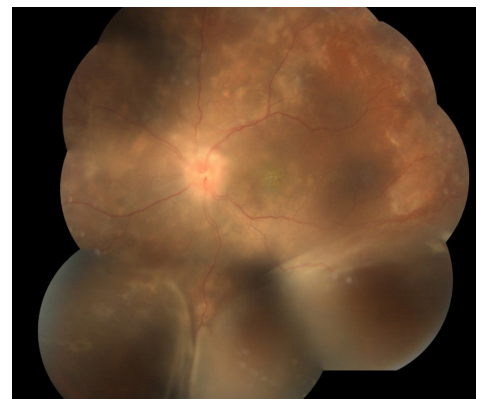

Figure - 1b

Further probe into history was negative for high BP in recent past, contact with TB personnel, cough, cold, fever, weight loss, pain on eye movement or redness in eyes.

Imaging study: FFA showed profuse disc leak, multifocal scattered spotty leaks, mild staining of peripheral vessels with peripheral capillary non-perfusion areas in OD and similar disc leak, scattered hypo and hyperfluorescent lesions and a large choroidal hypofluorescence in supero-temporal quadrant suggestive of choroidal infarct in OS. (Fig 2 a, b, c) EDI OCT showed mild subretinal fluid, few hyperreflective intra and subretinal lesions and loss of ellipsoid zone in OU. EDI OCT also showed a subretinal hyperreflective

lesion suggestive of a fibrin ball. (Fig 3 a, b) OS B SCAN showed retinal detachment with shifting fluid, no subtenon's fluid and no scleral thickening. (Fig. 4) Considering 1, 2, 3 and 4 as possible etiological diagnosis further lab work up was advised and steroids were withheld for investigations and patient was advised to come after 3 days. Patient returned after 2 weeks with following reports: ESR -30mm/hr, Hb-6.9%, TPHA-Negative, VDRL -Negative, Mantoux-8mm, Serum Proteins - Normal. No improvement in vision was noted. Clinical examination remained status quo. After physician's clearance oral steroids 40mg. After a week BCVA improved to 6/60 in OU. Rheumatologist had asked our clearance for i.v. MethylPrednisolone (IVMP) to treat her haemolytic anaemia, high creatinine levels and low C3/C4 ratio. We proceed with posterior subtenon's injection for her left eye and had given clearance to rheumatologist for IVMP. Patient was reviewed periodically while on tapering dose of oral steroids and immunosuppressive agents. Disc edema and subretinal fluid resolved completely but choroidal hypopigmented lesions persisted. (Fig. 5 a, b; Fig 6) After 3 months her BCVA improved to 6/36 in OD and 6/18 in OS.

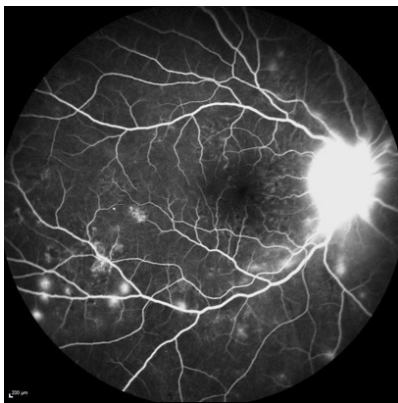

Figure - 2a

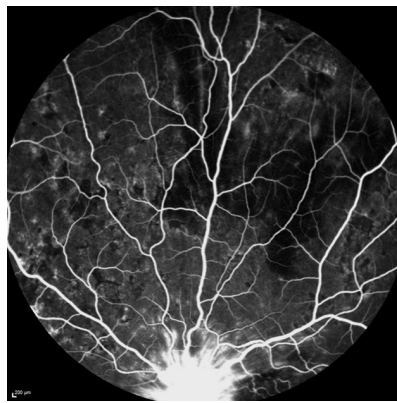


Figure - 2b

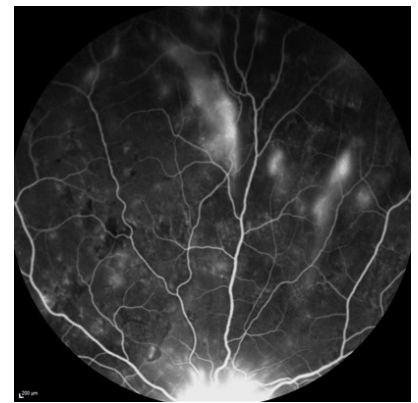


Figure - 2c

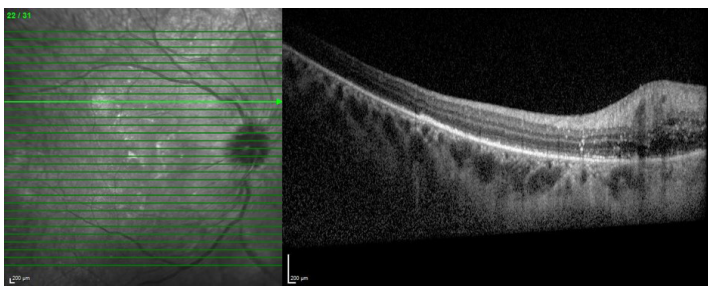


Figure - 3a

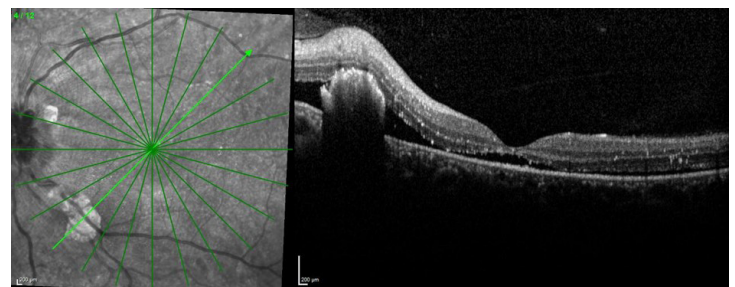


Figure - 3b

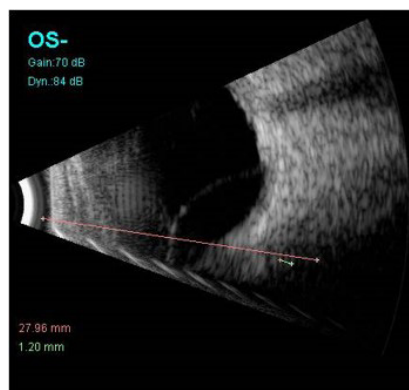


Figure - 4

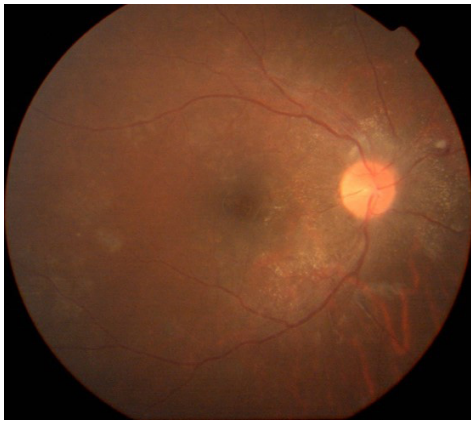

Figure - 5a

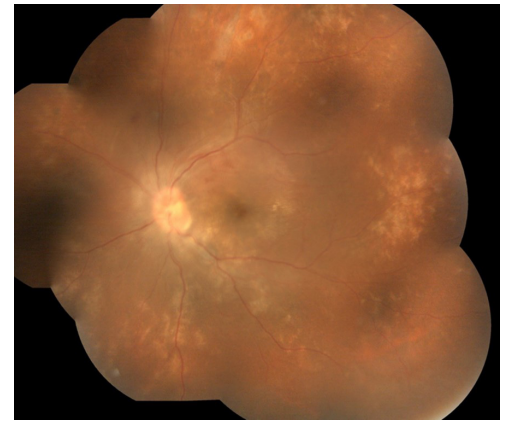


Figure - 5b

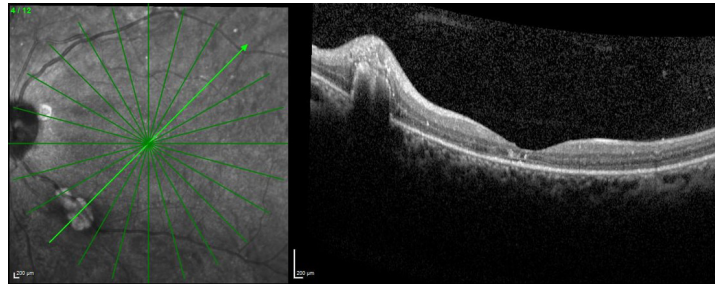


Figure - 6

### Discussion:

Although retinopathy in SLE has been widely reported, Lupus choroidopathy is a rare manifestation of the disease. It presents with exudative retinal detachment, multiple grayish yellow spotty choroidal lesions, retinal pigment epitheliopathy, clumping and atrophy.<sup>1</sup> Delayed choroidal perfusion, choriocapillary nonperfusion are key findings on FFA,<sup>1</sup> as seen in our patient. (Fig 2b) Choroidal vasculopathy could be secondary to hypertension resulting from lupus nephritis, vasculitis, or a combination of these processes.<sup>2,3</sup> In our case other differential causes such as protein losing nephropathy, tubercular choroiditis in immunocompromised and pure hypertensive choroidopathy were less likely as serum proteins were normal, no choroidal granuloma was evident on imaging and the patient improved dramatically after IVMP. Presence of choroidal infarcts on FFA, scattered grayish-yellow deep choroidal lesions on fundus examination, presence of lupus nephritis, low C3/C4 ratio and dramatic response to increase in steroid doses prompted diagnosis of lupus choroidopathy in our patient.

### Conclusion:

Lupus choroidopathy is a diagnostic challenge, choroidal imaging has invaluable role in the diagnosis. Although rare, presence of lupus choroidopathy is an indicator of severe underlying systemic vascular disease and requires additional immunosuppression as highlighted in our report.

1. Nguyen QD, Uy HS, Akpek EK, Harper SL, Zacks DN, Foster CS. Choroidopathy of systemic lupus erythematosus. *Lupus*. 2000;9(4):288-98.
2. Kinyoun J, Kalina R. Visual loss from choroidal ischemia. *Am J Ophthalmol* 1986; 101: 650-656.
3. Jabs D, Hanneken A, Schachat A, Fine S. Choroidopathy in systemic lupus erythematosus. *Arch Ophthalmol* 1988; 106: 230-234.



# Panel Discussion

## TB Or Not TB?

## TB Or Not TB?

Ocular Tuberculosis[TB] is an enigma marred with so many controversies. The practicing clinician has so many queries when handling in a practical scenario. The valuable insights by experts in the field with tonnes of experience serve us a limelight to traverse the tunnel. Hope there is some light at the end of it.

1. Given a scenario of bilateral granulomatous panuveitis and bilateral nongranulomatous panuveitis with 4 probabilities...

Mantoux/IGRA>	Positive	Negative
HRCT-Thorax positive for TB		
HRCT-Thorax negative for TB		

### How do you proceed?

A. Dr.J Biswas

Bilateral granulomatous panuveitis

Mantoux/IGRA>	Positive	Negative
HRCT-Thorax positive for TB	Anti TB+Steroids+Immunosuppression	Anti TB+Steroids+Immunosuppression
HRCT-Thorax negative for TB	Anti TB+Steroids+Immunosuppression	Steroids+Immunosuppression

### How do you proceed?

Bilateral Nongranulomatous panuveitis

Mantoux/IGRA>	Positive	Negative
HRCT-Thorax positive for TB	Anti TB+Steroids+Immunosuppression	Anti TB+Steroids+Immunosuppression
HRCT-Thorax negative for TB	Steroids+Immunosuppression	Steroids+Immunosuppression

### B.Dr.S.R.Rathinam

Whatever be the results of investigation report, the complete clinical scenario decides on the course of treatment .

1. Bilateral granulomatous panuveitis with positive Mantoux and CT thorax suggestive of TB , even then if the complete picture is more in favour of sarcoid, (ex : probability being presence of angle kps )then maybe we will need PCR TB to rule in TB.
2. In contrast, if the patient has a chorio retinal scar but rest of investigations negative, patient gives history of contact with TB- Then we may give a ATT Trial.
3. Non granulomatous pan uveitis- still if other features are suggestive of TB, we can go for ATT trial.

### **C. Dr.Amod Gupta**

a. A patient with bilateral granulomatous panuveitis who has +Mx/IGRA, and a HRCT Chest suggestive of TB would merit a full course of ATT treatment. A patient with bilateral granulomatous panuveitis with a negative Mx but evidence of TB on CT chest may be immune compromised due to HIV infection, disseminated TB or immunosuppressive therapy. Such a patient would merit full ATT treatment.

b. Since ~70 % of chest X-ray and ~30% of CT chest may not have findings suggestive of TB, patients with ocular TB with a +Mx/IGRA and bilateral granulomatous panuveitis would merit a full course of ATT.

c. A patient with bilateral granulomatous panuveitis with negative Mx and negative CT chest for TB needs investigation for syphilis, VKH etc. By and large a patient with Sarcoidosis would show hilar lymphadenopathy with a negative Mx test. I would not put such a patient on ATT in the first place.

d. HRCT + and +Mx/IGRA with bilateral non-granulomatous panuveitis is a less likely scenario, I have seen it as a paradoxical reaction on institution of ATT for pulmonary TB. Such patients would certainly require ATT.

e. HRCT + and - Mx/IGRA with bilateral non-granulomatous panuveitis is again a less likely scenario, would suggest a trans bronchial lung biopsy or EBUS to confirm the lung pathology.

f. A patient with bilateral nongranulomatous panuveitis with a negative Mx and negative CT chest should be investigated especially for Syphilis. I would treat such a patient on steroids and immunosuppressive therapy.

g. Bilateral non- granulomatous panuveitis with a + Mx but negative CT chest would require further investigations to elucidate the cause of inflammation and not ATT in the first place.

### **Dr.Vishali Gupta**

In a setting of panuveitis, if one immunological and one radiologic test or both immunological tests are positive, I would initiate ATT, provided the clinical phenotype is suggestive of ocular tuberculosis. In case only one immunological test is positive, I may get ocular fluid analysis or treat recurrent disease.

### **Dr.S.Basu**

The essence of diagnosis of TB-associated uveitis (TBU) lies in our ability to *exclude non-TB conditions*. Once we have done that (by clinical evaluation/ tailored investigations), we derive the combined weightage of the following factors: clinical presentation (signs predictive of TB), past PTB/EPTB, past h/o TB contact, immunological tests for TB (TST/IGRA), and radiological evidence of PTB/EPTB (healed, active). My decision to start anti-TB therapy is based on this combined weightage. For example, the TST/QFT may be negative, but say if the patient is a migrant worker, and presents with serpiginous-like choroiditis, I would be inclined on starting ATT. Conversely, when I find non-granulomatous anterior uveitis with fibrin, and history of inflammatory joint pain – even a TST of 40 mm, wont tilt me towards ATT. Finally, it is important to remember any granulomatous uveitis starts as non-granulomatous – so it may not be possible to distinguish between the two in the early stages.

**2. What are the scenarios you give trial of anti TB drugs? If so do you prefer 3 drugs or 4 drugs. When do you consider the trial is a success or failure?**

**A. Dr.J Biswas**

I do not give any trial and give anti TB drugs only when there is evidence of TB.

**B. Dr.S.R.Rathinam**

If the clinical picture is more in the favour of Ocular TB, (Ex: occlusive vasculitis in a young patient with chorioretinal scars along the vascular arcade), then even in the absence of other positive investigations we can go for ATT Trial.

It is always preferable to give 4 drug regime to avoid drug resistance and after 4-6 weeks looking at the clinical response, we can decide whether the trial is successful

**C. Dr.Amod Gupta**

I think only under exceptional circumstances one would consider a therapeutic trial in a TB endemic country. If at all you consider this option patient must receive at least 6 months of therapy with 4-drug for 2 months and 3 drug- for the next 4 months. One would assess clinically at 2 months for the efficacy of ATT.

**D. Dr.Vishali Gupta**

I do not give any trial of ATT. If I decide, it is complete course

**E. Dr.S.Basu**

My decision for starting ATT is based on factors mentioned above. Once started, I complete the full course, which for me is 6 mon. Therapeutic trial with ATT is generally discouraged, as it facilitates drug resistance. On a different note, Rifampicin itself has anti-inflammatory properties and may confound the results of a therapeutic trial

### 3. How long do you prefer to give anti Tb drugs with anti inflammatory medications?

#### A. Dr.J Biswas

-9 MONTHS

#### B. Dr.S.R.Rathinam

The amount of inflammation and the position of lesion decide on the mode, dosage and duration of the anti-inflammatory medication

#### C. Dr.Amod Gupta

For the Extra pulmonary TB, and the ocular TB is a part of this scenario, ATT should be considered for 9-12 months. The extra pulmonary sites are relatively hypoxic compared to the lungs and 6 months treatment is not adequate to eliminate the organisms. Corticosteroids can be tapered once the uveitis has resolved and need to be continued for as long as the ATT.

#### D. Dr.Vishali Gupta

Currently we are administering it for 9 months. First two months of INH, Rifampicin, ethambutol and pyrazinamide and then next 7 months of INH and Rifampicin

#### E. Dr.S.Basu

While there is no clear evidence for duration of ATT in TBU, we chose a 6-month course, based on the following factors:

1. TBU is a paucibacillary disease (as per current understanding), and if a 6-month course works for multibacillary PTB, it should work for paucibacillary disease too
2. The blood-retinal barriers are disrupted during ocular inflammation, so they should not restrict distribution of drugs
3. The only comparative study on duration of ATT (Ang et al, 2012) in TBU has insufficient data to compare between 6- and 9-mon ATT.
4. In an earlier study (Bansal et al, 2007), ~16% patients had recurrent inflammation after  $\geq 18$  months ATT
5. The pathomechanisms of intraocular inflammation in TBU also include autoimmune response (Tagirasa et al., 2017), and it may account for some of the delayed/ recurrent inflammation after ATT.

#### 4. Is the diagnostic criteria for ocular TB practically applicable in your real time practice?

##### A. Dr.J Biswas

Very much,classification given by Prof Amod Gupta

##### B.Dr.S.R.Rathinam

Yes , it helps in few cases to make diagnosis of ocular tb.

##### C. Dr.Amod

I am very sure we always followed the criteria in our clinical practice.i.e. patients in TB- endemic countries who have a phenotype consistent with TB uveitis namely Broad based posterior synechiae, retinal vasculitis with or without choroiditis, choroidal granulomas, multifocal serpiginoid choroiditis and who show some corroborative evidence of TB in the form of +immunological reaction, +X-ray or CT chest or +Biopsy from extraocular site would merit full course of anti-TB treatment. We did not entirely depend upon PCR results since the sensitivity of TB-PCR is rather low and as of now cannot be used to diagnose ocular TB per se but certainly it helped us in characterizing the phenotype of ocular TB.

##### D. Dr.Vishali Gupta

No

##### E. Dr.S.Basu

We follow the INDEX TB guidelines for ocular TB, and they are generally applicable in real-life scenarios. [<https://tbcindia.gov.in/showfile.php?lid=3245>]

#### 5. When do you consider ANTI TB drugs as a therapy without anti inflammatory medications?

##### F. Dr.J Biswas

-Never

##### B.Dr.S.R.Rathinam

In patient with HIV infection and low CD4 count, uncontrolled DM with high blood sugar levels

##### C. Dr.Amod

ATT alone may be considered in the rare event of a choroidal abscess or choroidal granulomas as a component of disseminated TB.

##### Dr.Vishali

I always combine it with standard of care anti inflammatory therapy

##### Dr.S.Basu

We consider 'solo' anti-TB therapy in the following scenarios:

- Focal/ multifocal choroiditis – not involving macula
- Retinal vasculitis with active/healed subvascular lesions, but no macular edema

Again, the anti-inflammatory effect of Rifampicin cannot be ruled out.

## 6. When do you revisit the diagnosis of TB after treatment initiation?

### A. Dr.J Biswas

-At 1 month

### B. Dr. S.R.Rathinam

Uveitis is a dynamic disease,

The following may make me rethink my diagnosis

- No response even after a month
- Development of a sign not co-relating with diagnosis

### C. Dr.Amod Gupta

if it is due to TB, it should resolve by 2 months. Keep in mind that the MTB may be drug resistant in almost 15% of patients and would require PCR and gene sequencing to diagnose.

### D. Dr.Vishali Gupta

If the patient is not responding in 6-8 weeks time

### E. Dr.S.Basu

We revisit the diagnosis, if there is worsening or no improvement after at least 2 weeks of treatment. The approach to early and late treatment failure in ocular TB is given in the INDEX-TB guidelines

## 7. Do you consider priming of steroids before anti TB drugs in ocular TB helps in reducing paradoxical reactions?

### A. Dr.J Biswas

-No I don't do that

### B. Dr.S.R.Rathinam

No, we have never tried priming with steroids before ATT Trial.

### C. Dr.Amod Gupta

No

### D. Dr.Vishali Gupta

Sometimes yes, especially when lesions are very close of fovea as in patients with Serpiginous-like choroiditis.

### E. Dr.S.Basu

Priming with steroids before anti-TB drugs is an option in large serpiginous-like lesions that are threatening the fovea. However, we do not follow it in our practice.

## 8. When do you consider different types of PCR and the molecular tests for TB in your real time practice?

### A. Dr.J Biswas

-In cases of granulomatous anterior uveitis,panuveitis,anterior uveitis with multifocal serpginous like choroditis,subretinal abcess

### B. Dr.S.R.Rathinam

When the clinical picture and the investigation does not correlate with each other. In a patient with multi-focal choroidal lesions and healed hyper pigmented chorio retinal scars, if the blood investigation and systemic imaging does not support the diagnosis, then we can think of molecular diagnosis for confirming the Etiology. The vice versa is also true. Second scenario, a patient who has completed a course of ATT but still has recurrence of uveitis. Real Time PCR can be done to look for activity

### C. Dr.Amod Gupta

All the molecular techniques (RT-PCR, Xpert, LPA, Multiplex PCR, LAMP, to diagnose ocular TB have low sensitivity varying from 20-30%. In house conventional PCRs lack validation. We have used in the past these techniques to characterise clinical presentations of ocular TB but these have at best a very limited role in diagnosis and are no longer practiced as a routine as a negative test does not rule out TB.

### D. Dr.Vishali Gupta

In cases where there is diagnostic dilemma and presentation atypical

### E. Dr.S.Basu

PCR of body fluids, unlike culture/ microscopy does not provide a *definitive* evidence of any EPTB [INDEX-TB guidelines]. False-negative results can occur due to inadequate sampling (esp. with low cellular count, since Mtb is an intracellular organism). Conversely, false-positive PCR is common in TB-endemic countries, due persistence of *Mtb* or its DNA ('bystander DNA') in reticulo-endothelial cells in different tissues. For these reasons, our initial enthusiasm on the role of PCR in diagnosis of ocular TB has now come down

## 9. How do you consider the possibility of atypical mycobacterial infections?

### A. Dr.J Biswas

-I usually don't consider

### B. Dr.S.R.Rathinam

When there is no response to ATT for more than a month, we can consider Atypical mycobacterium.

### C. Dr.Amod Gupta

Under exceptional circumstances, yes but majority of these are diagnosed by molecular techniques.PGI Chandigarh has reported some such odd cases.

### D. Dr.Vishali Gupta

This is mostly diagnosed when we do PPV for atypical situations and PCR comes positive for atypical mycobacteria. My experience of treating them with long term clarithromycin and ethambutol has been frustrating though

### E. Dr.S.Basu

Our experience with atypical mycobacteria are mainly in scleritis and sclerokeratitis. However, these have also been implicated in uveitis, and they remain a real possibility especially in endemic regions

## 10. When you make the diagnosis of paradoxical reaction due to TB, how do you delineate the differentials?

### A. Dr.J Biswas

-4 weeks after initiating anti TB treatment if there is a recurrence

### B. Dr.S.R.Rathinam

Worsening of clinical picture after starting the patient on Anti Tubercular Therapy. Ex : Development of vascular occlusion in a patient who presented with only choroiditis .

### C. Dr.Amod Gupta

In our experience majority of the paradoxical reactions are seen in patients with TB multifocal serpiginoid choroiditis and are seen within days to few weeks after initiating ATT. Rarely have seen in patients with periphlebitis and choroidal granulomas.

### D. Dr.Vishali Gupta

Typically occurs in 2-3 weeks after initiating ATT and shows enlargement of the lesions with appearance of new lesions in a phenotype that is characteristic for TB. Increasing dose of systemic steroids, intravitreal ozurdex or methotrexate will show a good response

### E. Dr.S.Basu

Paradoxical worsening has mainly been reported in serpiginous-like choroiditis (though also seen in other presentations, Basu et al., 2010 and 2013). These are generally seen between 1-6 weeks after starting ATT, and typically result in enlargement of the pre-existing lesion, though new lesions may also be seen.

The main differential at this stage is a missed/alternative diagnosis, and must be ruled out through ocular and systemic evaluation and tailored investigations

## 11. When do you give anti TB drugs with immunosuppressives?

### A. Dr.J Biswas

-Most of the times

### B. Dr.S.R.Rathinam

When suspicion of TB co-exists with the primary pathology. EX: When it is a proven case of Wegeners and patient needs immuno suppression and there is a co existing pulmonary lesion suggestive of TB

### C. Dr.Amod Gupta

Rarely in less than 5% of cases of serpiginoid choroiditis we had to use IMT when the the lesions were progressive even on high dose of oral corticosteroids and the fovea was threatened.

### D. Dr.Vishali Gupta

In patients who show recurrences while reducing corticosteroids and would require long term immunosuppression

### E. Dr.S.Basu

Our preferred immunosuppressive for TBU is methotrexate. We avoid using it concurrently with ATT, considering their shared hepatotoxicity. However, we have used intravitreal methotrexate (e.g. in steroid responders) during primary disease and oral methotrexate in post-ATT inflammation.

## 12. How do you consider giving anti VEGF s along with anti Tb drugs? How often you repeat them?

### A. Dr.J Biswas

-CNVM in choroditis, some occasion I have given in choroidal tuberculoma

### B. Dr.S.R.Rathinam

Treat the ocular condition and bring down the inflammation , before deciding on anti-VEGF. The subsequent dosing will depend on the recurrence or persistence of the reason for dosing.

### C. Dr.Amod Gupta

We have used rather frequently in recent years after initially reporting in BMJ case reports, a case of successful treatment with intravitreal avastin of recurrent TB granuloma. The vascularisation in these granulomas is driven by VEGF and they respond to a few injections given every 4 weeks. Once the granuloma subsides, you need not keep injecting till it recurs

### D. Dr.Vishali Gupta

Mostly in patients of TB granuloma who show concomitant choroidal neovascularization or patients with Serpiginous like choroiditis who complaint of recent metamorphopsia and show iCNV on OCTA. These patients usually need one-two injections only and we administer them on prn basis.

### E. Dr.S.Basu

Anti-VEGF drugs can serve 2 purposes in TBU. First, they prevent dissemination of *Mtb* from the granuloma as reported in the zebra fish model of TB (Ohlers et al, 2015). Second, they reduce vascularity of the granuloma and help in faster resolution of lesions. The former mechanism is unlikely to be applicable to TBU, as it is supposedly paucibacillary. However, the latter might be useful especially in lesions with increased vascularity. Currently, there are no specific guidelines for injecting/ repeating anti-VEGF agents.

**13. Do you follow the Index-TB guidelines of the utility of IGRA over mantoux test to evaluate for TB in India?**

**A. Dr.J Biswas**

-I don't know any such guidelines

**B. Dr.S.R.Rathinam**

NO ,we prefer to use Mantoux.

**C. Dr.Amod Gupta**

We have typically used Mx test. IGRA has low sensitivity in extra pulmonary TB

**D. Dr.Vishali Gupta**

No

**E. Dr.S.Basu**

Both IGRA and Mantoux do not distinguish between latent and active TB. The specificity advantage of IGRA is minimal in areas with low prevalence of atypical mycobacteria. The influence of BCG vaccination (if received in infancy, as in India) on the Mantoux reaction is not seen beyond 10 years of age (Menzies, 2000). For these reasons, IGRA does not offer any additional advantage over TST in majority of cases.

**14. How do you rule out the differential diagnosis of subretinal abscess from that due to TB?**

**A. Dr.J Biswas**

-I do vitreous biopsy or FNAB

**B. Dr.S.R.Rathinam**

Molecular diagnosis can help in these clinical situations

**C. Dr.Amod Gupta**

You have to have high index of suspicion and consider fungal, Brucella or even bacterial infections depending on the clinical setting of say a patient with indwelling catheters, IV hyperalimentation, UTI, liver transplant, IV dextrose infusions in rural settings for a fungal infection, pneumonias, UTI, SABC, septicaemias etc. for bacterial and cattle handlers for Brucella infections. TB abscess would be seen in patients who are sick with disseminated TB. The labs would include blood, urine or ocular fluid smear and cultures.

**D. Dr.Vishali Gupta**

Presence of Retinal angiomatous proliferans over an abscess would make me suspicious of possible TB etiology. The rest of the diagnosis is based on investigations.

**E. Dr.S.Basu**

I have limited experience with treatment of TB subretinal abscess, but majority of patients would have concurrent pulmonary/ miliary TB, that would lead you to the diagnosis

## 15. When do you consider resistance to anti Tb drugs?

### A. Dr.J Biswas

One month of therapy with anti TB if there is no regression

### B.Dr.S.R.Rathinam

When a proven case of TB , does not respond to the routine course of treatment for more than one month.

### C. Dr.Amod Gupta

We have considered resistant organisms in very few cases who did not respond to the conventional therapy and were subjected to diagnostic PPV with PCRs and gene sequencing .

### D. Dr.Vishali Gupta

Patient who is unresponsive to therapy and progressing despite adequate ATT and steroid/ immunosuppression and re-investigations for other possible causes are all negative.

### E. Dr.S.Basu

In general, the prevalence of MDR in EPTB is less common than PTB. Also, the diagnosis of TBU is rarely based on culture and microscopy. Thus, the diagnosis of MDR ocular TB is challenging in the absence of concurrent pulmonary TB. We must again rule out an alternative diagnosis with appropriate investigations, and paradoxical worsening. History of recent contact with open MDR TB patient is useful. Sequencing of *Mtb* DNA from vitreous for the *rpoB* gene (Rifampicin resistance) has been reported for diagnosis of drug-resistant ocular TB. However, anecdotal evidence suggests that lesions with *rpoB* gene mutations have occasionally resolved without MDR-TB therapy. Thus the diagnosis of MDR ocular TB remains an open question.

## 16. What are the clinical, laboratory parameters that you shall employ to repeat when a patient is on anti TB medications at each visit?

### A. Dr.J Biswas

I do liver function tests to rule out hepatotoxicity.

### B. Dr.S.R.Rathinam

Usually liver function tests are done, before starting the patient on ATT and repeated only when the patient complaints of intolerance or develops signs suggestive of drug toxicity.

Baseline colour vision before starting the patient on ATT.

### C. Dr.Amod Gupta

All patients who are put on ATT should have liver functions done every 2-4 weeks for the first 3-4 months and the interval may be increased later. If the patient is planned to receive ethambutol longer than 2 months, they should have baseline colour vision and repeated at all visits

### D. Dr.Vishali Gupta

Liver function tests.

### E. Dr.S.Basu

Liver function tests are required at baseline and then at 4 and 8 weeks. Routine laboratory monitoring is not necessary. Incidentally, ethambutol toxicity has not been reported in patients with TBU.



# **Kaun Banega Uveapathy!**

## **Quiz-Take five!**

**Author**

**Dr. Parthopratin Dutta Majumder**  
Senior Consultant  
- Sankara Nethralaya, Chennai

## Take Five

### Parthopratin Dutta Majumder

Senior Consultant, Department of Uvea and Intraocular inflammation, Sankara Nethralaya, Chennai

#### Questions:

1. Pharmacist Gavin S. Herbert was a successful owner of a chain of drug stores in Los Angeles. He and his close friend Stanley Bly planned to develop an anti-allergy nasal drop containing the antihistamine neoantergan. They set up a small laboratory on the balcony of Mr. Herbert's drugstore in Los Angeles to make the solution. Responding to the suggestion of an ophthalmologist friend, Mr. Herbert and Mr. Bly later reformulated the product as an eye drop to treat allergic conjunctivitis. This was the beginning story of a pharmaceutical company. Name the pharmaceutical company.
2. If we compare human eye as a photo camera, what would be its resolution?
3. Why the term "Reiter's Syndrome" was abandoned and renamed "reactive arthritis"?
4. In 1853 Henry joined George's Hospital Medical School, London as lecturer. His aim was to write a compact illustrated textbook for students that will be low-cost yet accurate and authoritative. He was amazed by the artistic skills of Carter, who was studying at St. George's for his medical qualifications. The duo went on writing and illustrating. The first edition of the book ran to 750 pages with more than 360 pictures. While preparing the second edition in 1860, Henry died of smallpox at the age of 34. He contracted the disease while treating his nephew, who survived. Carter shifted to Mumbai (then Bombay) in 1858 as he joined the Indian medical service and worked as a Professor in Grant Medical College, Mumbai. However subsequent work on the book was continued by others. The 41<sup>st</sup> edition of the book was published in 2015 - 1,600 pages, with almost 2,500 illustrations—1000 of them new. The book has remained a vital teaching and reference work for generations of medical students, surgeons, and all other health practitioners. Which book I am talking about.
5. The word "abracadabra" was originally used to treat which disease?

## \*Answers on page no. 73



# Delineating the differential! CSCCR versus Serous RD

## Author Credits

**Dr. Anand Rajendran** *FRCS, DNB*

Professor & Head  
Retina-Vitreous Service

Aravind Eye Hospital, Chennai

**Dr. Eliza Anthony** *DNB*

Consultant  
Retina & Uvea Service  
Aravind Eye Hospital, Chennai

# Delineating CSCR from Inflammatory retinal detachments

## The Preamble

If there are a couple of entities that have cross-simulated each other in the vast spectrum of retinal and choroidal pathologies and have been erroneously misidentified for each other, it would be Central Serous Chorioretinopathy (CSCR) and Inflammatory Retinal Detachments. To add to the enigma and misplaced aura of this troublesome twosome, is the fact that the aggravating factor for one is almost always the antidote for the other – namely that ubiquitous drug - steroids. This couple has also perhaps the dubious distinction of being the cause for many an altercation between the Retina and Uveitis Specialists and quite counter-intuitively, also a large part of the rationale for the two branches to realise that a harmonious co-existence is the smarter option.

Distinguishing CSCR from Inflammatory Retinal Detachments may be done by a careful appraisal of the History, Clinical examination and Investigations such as the Optical Coherence Tomogram (OCT), Fundus Fluorescein Angiography (FFA) and Indocyanine Green Angiography (ICG). The common Uveitic entities that form the differential spectrum are Vogt Koyanagi Harada Syndrome (VKH), Posterior Scleritis, Infective Focal Choroiditis, White Dot Syndromes (WDS).

## I. The History

**CSCR** - Attention to the role of complaints, the medical history and presentation is a largely under-rated aspect of this exercise. CSCR is typically a unilateral disease or asymmetrically bilateral in presentation. A painless, gradual onset mild loss of central vision with metamorphopsia are the classic complaints seen mostly in males in their second decade. Association with a stressed life-style, Type A personality and vocations involving intense activity at night time with reduced or irregular sleeping hours are common features.<sup>1,2</sup> Obstructive sleep apnea, Helicobacter pylori infections have been implicated and bear asking for.<sup>1</sup> A history of using steroid based medications or cosmetic applications are to be looked for too.<sup>1,2</sup>

**Uveitic Pathologies** - On the contrary, the uveitic entities more often than not present with pain and redness. VKH, WDS tend to be bilateral, while posterior scleritis is invariably unilateral.<sup>3,4,5</sup> VKH is classically associated with systemic signs like vitiligo, poliosis and auditory and neurological signs like deafness, headache, tinnitus.<sup>3</sup> Infective posterior choroiditis can occur in a host of pathologies which may have their corresponding signature systemic manifestations. Posterior scleritis is typically painful.<sup>4</sup> The WDS', especially APMPPE, usually present with asymmetrically bilateral central or paracentral scotomas and blurred vision that may closely simulate a CSCR.<sup>5</sup> Sympathetic Ophthalmia (SO) would have the history of penetrating injury to the contralateral eye.

## II. The Clinical Exam – Tell tale Signs

**CSCR** - Acute CSCRs present as serous detachments in the posterior pole with or without pigment epithelial detachments (PEDs). **(Figure 1)** Serous PEDs, confirmed on OCT, serve as a marker for CSCR and are a very simple sign of distinguishing a CSCR from inflammatory entities. Chronic CSCRs may have a tear-drop tract, with or without serous RD, and is a give-away feature.<sup>1,2</sup> **(Figure 2,3)** Subretinal fibrin may resemble exudates of choroiditis closely and are, therefore, not always a reliable sign. **(Figure 4)** RPE tears, may occasionally, be seen with CSCRs.<sup>6</sup> Rarely, CSCR can rarely present as bullous serous retinal detachments seen gravitating inferiorly.<sup>6</sup> **(Figure 5)** This bullous variant of CSCRs may also be associated with RPE tears, subretinal fibrin and retinal folds.<sup>6</sup>

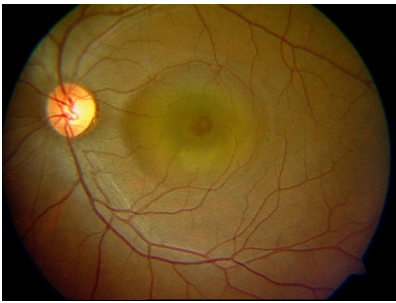


Figure - 1

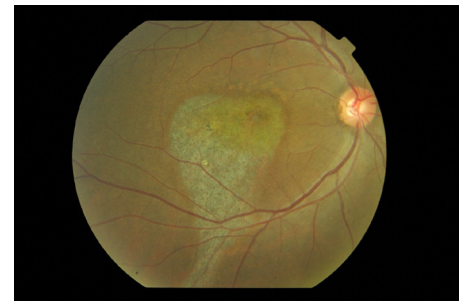

Figure - 2

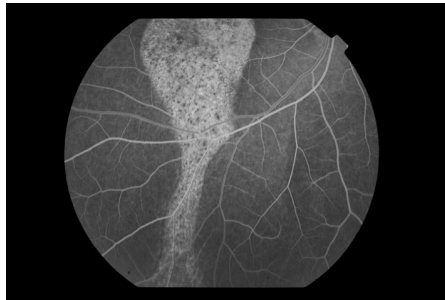


Figure - 3

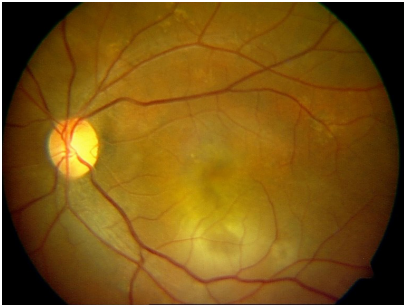


Figure - 4

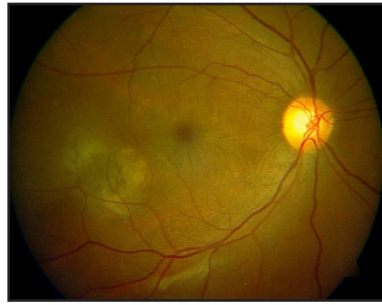


Figure - 5a

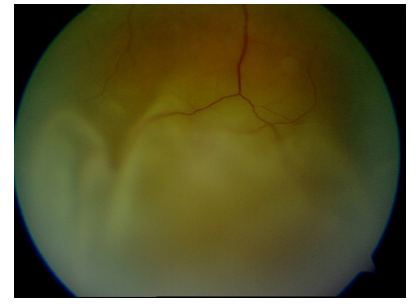


Figure - 5b

**Uveitic pathologies** – The presence of inflammatory cells – vitritis, iritis, as well as other signs of inflammations, such as keratic precipitates, pigments, posterior synechiae, peripheral choroiditis and exudative RDs are obvious, exclusive features of uveitis ruling out CSCR. Cystoid Macular edema (CME) at the apex of a fresh serous RD is a sign of an inflammatory pathology. However, a word of caution – Chronic CSCR's may also have cystoid macular degeneration. Uveitic entities more often present as multiple serous RDs in the posterior pole as commonly seen with VKH and WDS. **(Figure 6)** Disc edema is another feature, which when present, is a hallmark of uveitis.

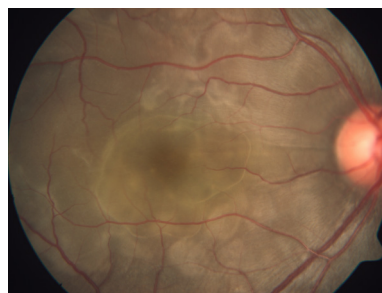


Figure - 6

White dot syndromes consists of group of disorders which present with multiple yellowish white lesions at the level of outer retina and RPE. These include punctate inner choroiditis (PIC), multiple evanescent white dot syndrome (MEWDS) and acute posterior multifocal placoid pigment epitheliopathy (APMPPE).

PIC occurs in mostly in myopic females and presents with discrete yellowish white lesion at posterior pole and mid periphery, at the level of outer retina and RPE with overlying serous RD. Choroidal neovascularisation is common in PIC which is seen clinically, as well confirmed on angiography.<sup>5</sup> APMPE presents as placoid greyish white lesions at the posterior pole with overlying serous RDs. It is bilaterally assymmetric and vitreous might shows few cells.<sup>5</sup> It is has been associated with tuberculosis, sarcoidosis, granulomatosis polyangitis , inflammatory bowel disease, post streptococcal type A infection , post Hepatitis B vaccination and mumps.<sup>5</sup> MEWDS is usually self limiting and has a good visual prognosis. It presents with subtle white deep lesions at posterior pole which might, sometimes, have a wreath like pattern.<sup>5</sup>

### III. Investigations

#### a. OCT

**CSCR** - A very critical differentiating feature on OCT imaging is that in CSCRs, the RPE-Choroid is invariably a straight line image on the scan, while in several choroiditic pathologies, the OCT contour of the choroid is a lumpy, undulating one. **(Figure 7, 8)** Serous PEDs, as mentioned above, when present, almost always rule out uveitic pathologies.<sup>6</sup> Serous RDs presenting alone can be obfuscated with WDS especially APMPE and early presentations of VKH and even posterior scleritis, rarely. This is more the case when the CSCR uncharacteristically presents as multiple serous RDs or is multiloculated wherein the aforementioned differentials bear a closer semblance.<sup>6</sup>

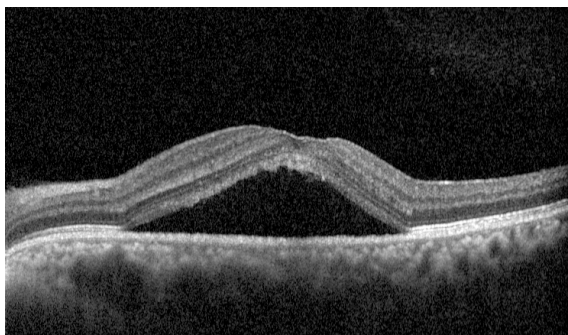


Figure - 7

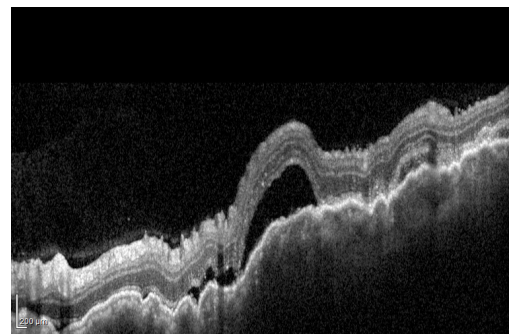


Figure - 8

The presence of subretinal fibrin, more a feature of recurrent or chronic CSCRs, is probably the single feature that seeds the most doubt. Usually pouring through at the site of RPE leak, it is most commonly mistaken for focal choroiditis, especially when it is the dominant feature over serous fluid.<sup>6</sup> Enhanced Depth Imaging (EDI), a mode used to study the choroid and deeper structures in better detail, often shows the CSCR case to have a thickened choroid or Pachychoroid.<sup>7,8,9</sup> **(Figure 9)**

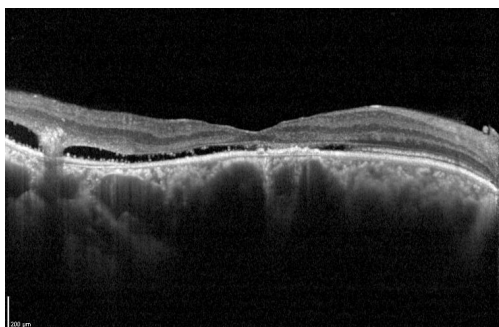


Figure - 9

**Uveitic Pathologies** - Additionally, in uveitic pathology like VKH, the retina is commonly seen as multiple, arching serous RDs on the cross-sectional OCT scan, which is christened as the "Aqueeduct Sign". (**Figure 10**). Often, the outer retina is selectively edematous in cases of posterior scleritis and occasionally other posterior uveitides too, a feature that would truly distinguish it from CSCR. (**Figure 11**) Inflammatory uveitic entities also have the OCT showing up the posterior vitreous to have a cellular reaction.<sup>10</sup> (**Figures 12, 13**) Cellular infiltrates and Hyper-reflective dots have been detected on EDI-OCT.<sup>10</sup>

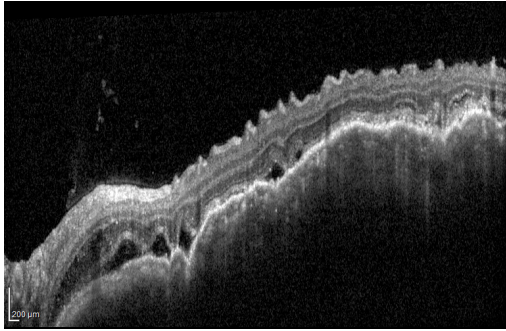


Figure - 10

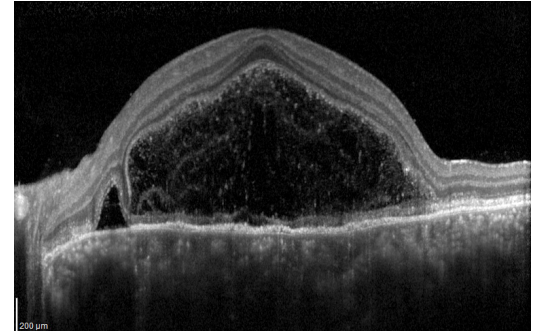


Figure - 11

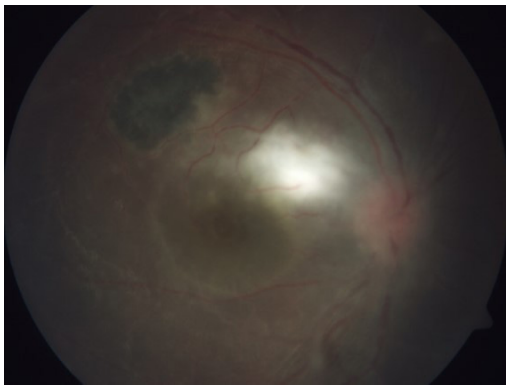


Figure - 12

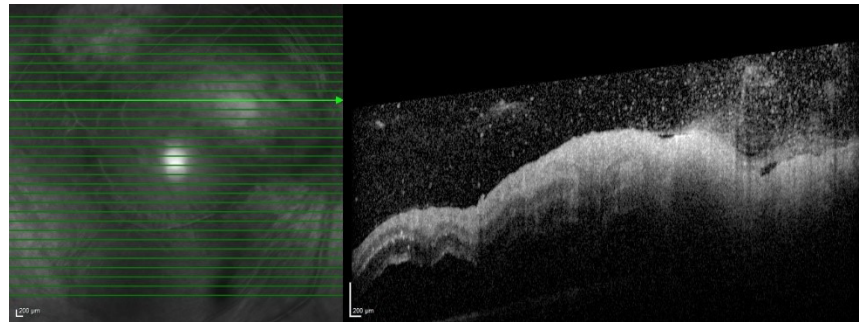


Figure - 13

## B. Angiography

**CSCR** – Fundus Fluorescein Angiography (FFA) is the gold standard in confirming a diagnosis of CSCR with the signature RPE leaks – the commoner "ink-blot" and rarer "smoke-stack" leaks with late phase pooling of dye in SRD and RPE transmission defects.<sup>2,6</sup> (**Figures 14,15**) Descending tear-drop tracks can be appreciated in FFA as mottled hyperfluorescent tracks. CSCR does not have disc leakage or staining unlike inflammatory conditions. Peripheral non perfusion has been noted in 38% cases of bullous CSCR.<sup>7</sup>

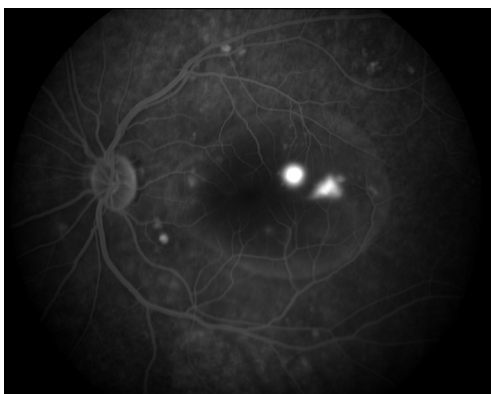


Figure - 14

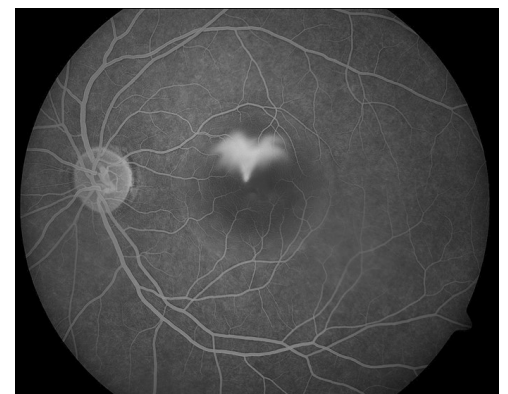

Figure - 15

Indocyanine green angiography (ICG) may show characteristically patchy choroidal hyperfluorescence.<sup>8</sup> Pachyveasels, choroidal hypocyancence owing to pooling of overlying SRF may be seen too.<sup>9</sup> (Figure 16)

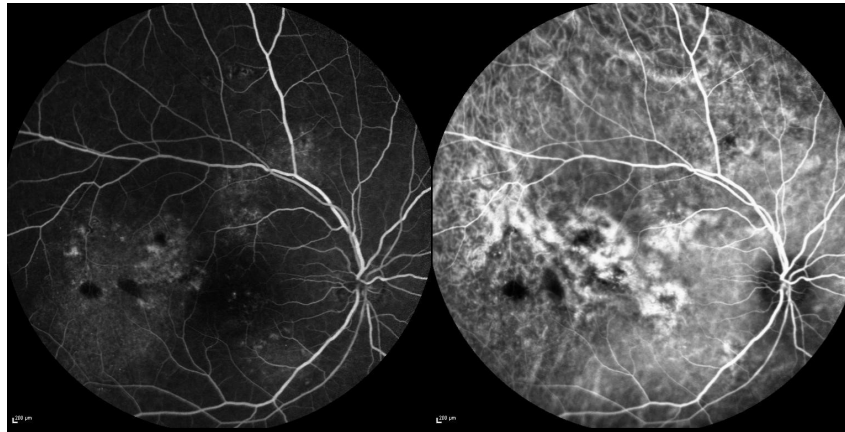


Figure - 16

**Uveitic pathologies** – While the typical angiographic features of CSCR, as discussed above, are quite unique, and helps differentiate it from a host of uveitic entities, the latter have distinct features of their own. VKH shows delayed choroidal filling, multiple pinpoint RPE leaks in arteriovenous phase and late prominent pooling of dye in SRDs and a hot disc.<sup>3</sup> (Figure 17) The “starry sky” pattern is a classic angiographic description of VKH. Indocyanine angiography (ICG) shows early patchy hypofluorescence due to choroidal vasculopathy with hyperfluorescent stromal vessels due to vasculitic choroidal large vessels, mid phase hypofluorescent spots corresponding to areas of choroidal inflammation and granulomas and late phase diffuse choroidal hyperfluorescence.<sup>3</sup> Choroidal folds appears as hyperfluorescent bands on ICG.

In Posterior Scleritis, FFA shows early multiple pin point RPE leaks with pooling of dye in serous RDs and a hot disc, when associated with disc edema. B scan ultrasonography shows diffuse or nodular choroidal thickening with widening of subtenon's space and the classical T-sign.<sup>4</sup> (Figure 18)

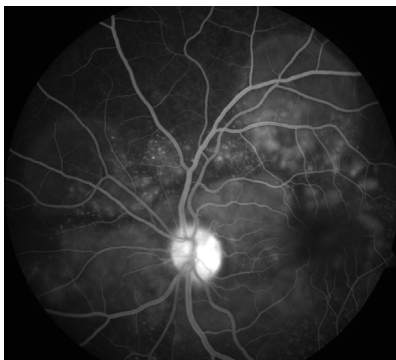


Figure - 17

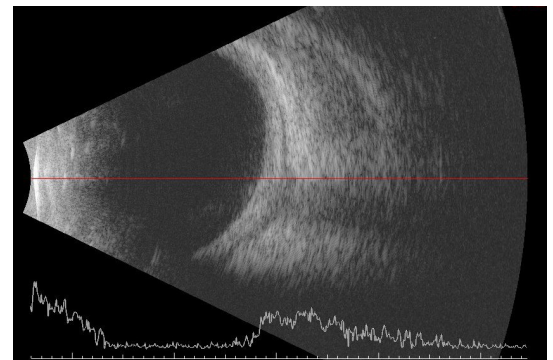


Figure - 18

All WDS shows early hypofluorescence with late hyperfluorescence on FFA except MEWDS which shows early and late hyperfluorescence on FFA.<sup>5</sup> Early hypofluorescence in WDS in FFA is due to choroidal non perfusion or infarction secondary to inflammation. In late stages of PIC and APMPPE, RPE becomes atrophic and shows transmission defects on FFA. ICG shows early and late hypofluorescence in all WDS.<sup>5</sup> In choroiditis, FFA demonstrates early hypofluorescence with late hyperfluorescence and late pooling of dye in the serous RD. ICG in choroiditis lesions show early and late hypofluorescence.

CSCR and Uveitic pathologies, thus present constellations of symptoms, signs and imaging markers that are largely distinct and unique. However, they do occasionally mimic each other and a heightened

awareness of these masquerading as well as distinguishing features will serve us well in diagnosing and managing them with precision.

### References:

1. Liu B, Deng T, Zhang J. Risk factors for central serous chorioretinopathy : A Systematic Review and Meta-Analysis. *Retina* 2016;36(1):9–19.
2. Nicholson B, Noble J, Forooghian F, Meyerle C. Central serous chorioretinopathy: update on pathophysiology and treatment. *Surv Ophthalmol* 2013;58(2):103-26.
3. Baltmr A, Lightman S, Tomkins-Netzer O. Vogt–Koyanagi–Harada syndrome – current perspectives. *Clin Ophthalmol* 2016;10:2345–61.
4. McCluskey PJ, Watson PG, Lightman S, Haybittle J, Restori M, Branley M. Posterior scleritis: Clinical features, systemic associations, and outcome in a large series of patients. *Ophthalmology*. 1999;106(12):2380–6.
5. Quillen DA, Davis JB, Gottlieb JL, Blodi BA, Callanan DG, Chang TS, et al. The white dot syndromes. *Am J Ophthalmol*. 2004;137(3):538–50.
6. Sahoo NK, Singh SR, Rajendran A, Shukla D, Chhablani J. Masqueraders of central serous chorioretinopathy. *Surv Ophthalmol*. 2019;64(1):30–44.
7. Balaratnasingam C, Freund KB, Tan AM, et al. Bullous Variant of Central Serous Chorioretinopathy: Expansion of Phenotypic Features Using Multimethod Imaging. *Ophthalmology*. 2016;123(7):1541–52.
8. Cheung CMG, Lee WK, Koizumi H, Dansingani KK, Lai TYY, Freund KB. *Eye* 2019;33(1):14-33.
9. Gallego-Pinazo R, Dolz-Marco R, Gomez-Ulla F, Mrejen S, Freund KB. Pachychoroid diseases of the macula. *Med Hypothesis Discov Innov Ophthalmol* 2014;3(4):111-5.
10. Lin D, Chen W, Zhang G, Huang H, Zhou Z, Cen L, et al. Comparison of the optical coherence tomographic characters between acute Vogt-Koyanagi-Harada disease and acute central serous chorioretinopathy. *BMC Ophthalmol* 2014;14:87.



## LEGENDS

- Figure 1** - An Acute CSCR with serous retinal detachment
- Figure 2** - Fundus photograph of a chronic CSCR with a tear-drop tract
- Figure 3** - FFA of the chronic CSCR with the hyperfluorescent atrophic tract
- Figure 4** - CSCR with subretinal fibrin
- Figure 5a** - Posterior pole of a chronic CSCR case with inferior exudative RD
- Figure 5b** - Inferior Exudative RD of the patient in 5a
- Figure 6** - A VKH case with multiloculated and multiple serous RDs
- Figure 7** - OCT of a CSCR case with a linear choroidal contour
- Figure 8** - OCT of a VKH case with a lumpy, undulating contour
- Figure 9** - EDI OCT of a Chronic CSCR with thickened choroid – Pachychoroid and large bore Pachyvessels
- Figure 10** - OCT of a VKH case with multiple serous RDs simulating the “Aqueduct Sign”
- Figure 11** - Outer retinal edema seen on the OCT in a case of Posterior Scleritis
- Figure 12** - Fundus picture of a case of toxoplasmic retinitis
- Figure 13** - OCT depicting the intense vitritis emanating from the focal toxoplasmic retinitis in Figure 12
- Figure 14** - FFA showing the “Ink- Blot” leak of CSCR
- Figure 15** - FFA revealing the “Smoke-stack” leak of CSCR
- Figure 16** - FFA showing mottled hyperfluorescence of a chronic CSCR and ICG highlighting the engorged pachyvessels.
- Figure 17** - FFA of a VKH case highlighting the pooling of the dye in serous RDs, multiple pinpoint leaks and the hot disc
- Figure 18** - A B-scan depicting the classic T-sign of posterior scleritis



# Journal Collection

Author

**Dr. S Bala Murugan**

Consultant - Aravind Eye Hospital,  
Pondicherry-605 007

## **Psoriasis-associated progressive necrotizing posterior scleritis: A 6-year follow-up.**

Amer R1, Levinger N1.

### **Abstract**

#### **PURPOSE::**

Posterior scleritis is the least frequent form of scleritis accounting for around 2%-8% of all scleritis cases. We aim to present the 6-year clinical course of a 62-year-old female patient with bilateral progressive necrotizing posterior scleritis who suffered from concurrent active psoriasis and psoriatic arthritis.

#### **METHODS::**

Descriptive case report.

#### **RESULTS::**

A middle-aged female patient was referred to our clinic because of left eye peripheral progressively enlarging white retinochoroidal lesions. Her previous work-up ruled out infectious and malignant etiologies. A second diagnostic vitrectomy was performed because of the slowly progressive and the atypical nature of the sectoral retinochoroidal patches in the retinal periphery. Again malignancy was ruled out. With the onset of cystoid macular edema and diffuse retinal vasculitis, which occurred concurrently with the reactivation of psoriasis and psoriatic arthritis, treatment was initiated with systemic immunosuppressants which initially included oral steroids and methotrexate and at the last follow-up 6 years after the first presentation included also cyclosporin and golimumab. Vision was preserved with quiescent uveitis and posterior scleritis.

#### **CONCLUSION:**

Posterior scleritis is an uncommon condition and it is even rarer in the setting of psoriasis. The necrotizing inflammation observed in the present case and by others revealed sectoral progressive chorioretinitis as a clinical manifestation which may initially raise the suspicion of masquerade malignant and infectious etiologies. Detailed thorough history-taking remains the cornerstone in identifying the possible systemic associations even when occult or subclinical.

## **Clinicopathologic case report: scleral buckle associated nontuberculous mycobacterial scleritis.**

Nielsen JS1, Blatt S, Perlman JI, Gieser RG.

### **Abstract**

Nontuberculous mycobacterial (NTM) infections have become increasingly important in ophthalmology, particularly with keratorefractive surgery. We report a case of scleral buckle associated NTM scleritis occurring in a 69-year-old male after silicone sponge explant removal. Purulent scleral ulceration with nodule formation persisted despite topical antimicrobial therapy, buckle removal, and surgical debridement. Eventually, tissue biopsy revealed noncaseating granulomas with acid-fast bacilli that were identified in culture as *Mycobacterium chelonae*. The infection resolved only after administration of systemic antibiotics. NTM are important pathogens in scleral buckle associated scleritis and should be considered in persistent cases. Surgical therapy remains the cornerstone of therapy, but antimicrobials, particularly newer fourth generation fluoroquinolones, may have an important role in treating scleral buckle associated NTM scleritis.

## **NODULAR POSTERIOR SCLERITIS: Clinico-Sonographic Characteristics and Proposed Diagnostic Criteria.**

Agrawal R1, Lavric A, Restori M, Pavesio C, Sagoo MS.

### **Abstract**

#### **PURPOSE:**

To report the clinical and ultrasound features and outcomes of a series of nodular posterior scleritis.

#### **METHODS:**

Retrospective medical record review of 11 consecutive patients with nodular posterior scleritis. Patient demographics, ocular and systemic findings, ultrasound features, and final anatomical and visual outcomes were recorded.

#### **RESULTS:**

There were 9 females and 2 males (11 eyes) with mean age at presentation of 57 years (range, 30-84 years). Underlying systemic inflammatory disease was present in 73%. Symptoms included pain in 73% and blurred vision in 45%. A solitary amelanotic mass without the presence of lipofuscin was found in all cases. Associated ocular features included retinal pigment epithelial changes (67%), intraocular inflammation (55%), subretinal fluid (50%), macular edema (50%), and choroidal folds (30%). B-mode ultrasound showed a sclerochoroidal mass with high internal reflectivity (100%) of mean elevation of 4.1 mm. There was nodular thickening of the sclera (100%) and fluid in Tenon space or "T" sign (36%). A complete regression of the nodule after the treatment was observed only in 1 patient (11%) and partial regression in 4 patients (44%).

#### **CONCLUSION:**

Nodular posterior scleritis should be considered in the differential diagnosis of a single amelanotic choroidal mass showing high internal reflectivity on ultrasound B-scan. It can produce intraocular inflammation in 50% of the cases and may be painless in 25%. It has a high association with a systemic underlying disease.

# Infectious scleritis: Clinical spectrum and management outcomes in India

Zia Sultan Pradhan, Pushpa Jacob

In this retrospective case series, we studied the predisposing factors, causative organisms, clinical spectrum, and outcomes of 12 cases of

culture-proven infectious scleritis. Nine of 12 patients had a history of preceding trauma (surgical or accidental). Past surgical history included small-incision cataract surgery (4), pterygium surgery (1), and trabeculectomy (1). Six patients had multifocal scleral abscesses due to *Pseudomonas*, *Klebsiella*, or *Nocardia*. Only 2 patients retained useful vision (>6/18). A poor visual acuity at presentation usually resulted in a worse visual outcome ( $P = 0.005$ ). Four eyes developed phthisis. The addition of surgical intervention did not result in a significantly better visual outcome than medical management alone ( $P = 0.209$ ), but resulted in a higher globe preservation rate ( $P = 0.045$ ). Therefore, we concluded that infection must be ruled out in cases of scleritis with preceding history of trauma, and aggressive surgical intervention improves the anatomical outcome but does not change the visual outcome.

**Key words:** Infectious scleritis, microbial scleritis, ocular infection, scleritis

Scleritis is a severe, painful inflammation of the sclera that may involve adjacent structures and can threaten vision.<sup>[1]</sup> Nearly 50% of cases are due to an associated collagen vascular disease, and an infectious etiology is comparatively rare.<sup>[2]</sup> The organism most often responsible is *Pseudomonas aeruginosa*.<sup>[1,3,4]</sup> However, reports from India have stated fungi to be more common in tropical regions.<sup>[2]</sup> We, therefore, analyzed data from our medical records to determine the clinical and microbiological spectrum of infectious scleritis in a tertiary care hospital in India. We also evaluated the visual and anatomical outcome of these cases to determine prognostic factors and effectiveness of management.

Access this article online	
Quick Response Code:	Website: www.ijo.in
	DOI: 10.4103/0301-4738.121085

Department of Ophthalmology, Christian Medical College, Vellore, Tamil Nadu, India

**Correspondence to:** Dr. Zia Sultan Pradhan, Department of Ophthalmology, Christian Medical College, Schell Eye Hospital, Arni Road, Vellore - 632 001, Tamil Nadu, India. E-mail: zedpradhan@gmail.com

**Manuscript received:** 15.05.13; **Revision accepted:** 15.08.13

## The spectrum of postoperative scleral necrosis.

Doshi RR1, Harocopos GJ, Schwab IR, Cunningham ET Jr.

### Abstract

An otherwise healthy 62-year-old woman developed necrotizing scleritis 23 years following pterygium excision with adjunctive beta-radiation. Surgically induced necrotizing scleritis (SINS) was diagnosed, but the scleritis progressed despite anti-inflammatory therapy, and 10 weeks after presentation the patient developed a hypopyon and decreased vision. After cultures revealed no growth at 72 hours, immunosuppressive therapy was escalated, with a subsequent deterioration in the patient's clinical course. *Scedosporium* superinfection was eventually cultured and found on histological examination of the enucleated globe. In reported cases, infectious scleral necrosis occurs most commonly following pterygium (71.4%) and scleral buckling (97.2%) surgery. Hypopyon is uncommon (10.0%) in patients with postoperative scleral necrosis, but when present is a strong predictor of infection (odds ratio, 21.2; 95% confidence interval, 2.9-157.5). Rates of underlying autoimmune disease are generally low (0.0-12.5%) except following cataract and lens procedures, where the occurrence of SINS heralds systemic illness in 42.9% of cases.

# Iontophoretic delivery of dexamethasone phosphate for non-infectious, non-necrotising anterior scleritis, dose-finding clinical trial.

O'Neil EC1, Huang J2, Suhler EB3, Dunn JP Jr4,5, Perez VL6, Gritz DC5, McWilliams K2, Peskin E2, Ying GS2,7, Bunya VY1, Maguire MG2,7, Kempen JH8,9,10,11.

## Abstract

Currently available treatment options for non-infectious scleritis, including non-steroidal anti-inflammatory drugs, systemic corticosteroids and immunosuppressive therapies, have both efficacy and side effect limitations. Iontophoretic delivery of corticosteroids has been demonstrated to be effective for anterior uveitis and represents a potential new approach to scleritis therapy. We hypothesised that iontophoretic delivery would provide effective and precise medication delivery to the sclera, while limiting systemic exposure and side effects. This first-in-human randomised, double-masked, dose-escalating study of iontophoretic administration of dexamethasone phosphate for scleritis suggests the treatment to be well tolerated and safe (within the limitations of the 18 patients sample size). There was a suggestion of efficacy in the lowest (1.2 mA/min at 0.4 mA) dose group (corresponding to the superficial location of scleritis compared with anterior uveitis), with 5/7 eyes meeting the primary efficacy outcome within 28 days. Our results suggest iontophoretic delivery of corticosteroids is a promising potential treatment for scleritis, with favourable safety and preliminary efficacy results in this phase 1 trial.

*TRIAL REGISTRATION NUMBER:*

NCT01059955.

© Article author(s) (or their employer(s) unless otherwise stated in the text of the article) 2018. All rights reserved. No commercial use is permitted unless otherwise expressly granted.

## Antineutrophil cytoplasmic antibody-positive scleritis: Clinical profile of patients from a tuberculosis-endemic region

Parthoprattim Dutta Majumder, Sridharan Sudharshan, Amala Elizabeth George, Sudha K Ganesh, Jyotirmay Biswas  
Departments of Uvea, Sankara Nethralaya, Chennai, Tamil Nadu, India

### Abstract

**Purpose:** To report the clinical profile of a series of antineutrophil cytoplasmic antibody (ANCA)-associated scleritis in Indian population. **Methods:** We conducted a retrospective review of medical records of 33 eyes of 26 consecutive patients with scleritis, who tested positive for either antibody to proteinase 3 [anti-PR3/cytoplasmic antineutrophil cytoplasmic antibody (cANCA)] or myeloperoxidase [anti-MPO/perinuclear anti-neutrophil cytoplasmic antibody (pANCA)] between 2006 and 2015. **Results:** The mean age at presentation was 54.1 (11.1) years and 61.5% of the patients were female. Underlying systemic disorder was found in 46.2% of patients and includes granulomatosis with polyangiitis (30.8%) and tuberculosis (15.4%). Necrotizing scleritis (48.5%) was the most common scleritis observed, followed by diffuse anterior scleritis (42.4%). Positive cANCA was found in 65.4% of patients and 34.6% was found positive for pANCA. Four of the six patients with positive Mantoux test were started on anti-tuberculosis treatment (ATT) by pulmonologist. Cyclophosphamide was the most common immunosuppressive and 11.5% of the patients required combination of two immunosuppressives. Seventeen eyes developed cataract and four eyes required patch graft. Female gender was more frequently associated with pANCA-associated scleritis than cANCA ( $P = 0.037$ ). Incidence of necrotizing scleritis was higher in patients with positive cANCA, but this difference was not statistically significant ( $P = 0.806$ ). cANCA-positive patients had statistically significant higher association with systemic rheumatic diseases ( $P = 0.021$ ). **Conclusion:** Necrotizing scleritis is the most common subtype of scleritis in ANCA-positive individuals and even in the absence of systemic involvement. All patients with ANCA positivity should be thoroughly screened to rule out any evidence of tuberculosis, especially in tuberculosis-endemic region before planning aggressive immunomodulatory therapy.

**Keywords:** Antineutrophil cytoplasmic antibody, granulomatosis polyangiitis, necrotizing scleritis, scleritis, tuberculosis

## Clinical Features of Scleritis Across the Asia-Pacific Region.

Joshua Lane, ORCID Icon, Ethan Nyugen, Julie Morrison, Lyndell Lim, Richard Stawell, Lauren Hodgson, Muhammad Amir Bin Ismail, Ho Su Ling, Stephen Teoh, Rupesh Agrawal, Padmamalini Mahendradas, Parvathi Hari, Poornachandra B. Gowda, Ankush Kawali ORCID Icon & Peter J. McCluskey

### Author information

### Abstract

#### PURPOSE:

To examine the spectrum of scleritis in four tertiary institutions across the Asia-Pacific.

#### METHODS:

Clinical records from 354 patients were reviewed from centers in Australia, Singapore, and India, excluding those with insufficient data (n = 24).

#### RESULTS:

Indian patients presented younger ( $41.5 \pm 13.4$  years) than Australians ( $50.8 \pm 17.5$ ) and Singaporeans ( $48.6 \pm 15.9$ ), with fewer women (49% vs 62%/57%). Diffuse disease was universally most common. Autoimmune and infectious disease proportions were similar in Australia (31%/10.3%) and Singapore (27.5%/8.3%) but reversed in India (8.3%/30%). Necrotizing scleritis was most frequently associated with infection (27.3%). Presumed ocular tuberculosis accounted for 75% of infectious cases in India. Posterior scleritis had the highest complication rate (82.4%) and immunosuppressants used per patient ( $0.98 \pm 0.31$  95% CI).

#### CONCLUSIONS:

Clinical presentations of scleritis vary across the Asia-Pacific, particularly in endemic regions for tuberculosis such as India, where it affects younger men with a predominance of nodular and infectious disease.

## Dengue fever-associated necrotizing scleritis: A case report with long-term follow-up.

Kamoi K, Mochizuki M, Ohno-Matsui K.

### Abstract

#### RATIONALE:

Dengue fever is a notable emerging infectious disease that is now seen worldwide, with an estimated incidence of approximately 390 million cases per year. Although ocular complications are uncommon among dengue fever-infected patients, caution is needed to prevent vision loss. Here we report a potentially serious sight-threatening complication of dengue fever, dengue fever-associated necrotizing scleritis.

#### PATIENT CONCERNS AND DIAGNOSIS:

After being bitten by mosquitoes, a 60-year-old Japanese female exhibited positive serologic tests of immunoglobulin M and G enzyme immunoassays for dengue viral infection along with a decrease of leukocytes and platelets. These findings led to a dengue fever diagnosis. Slit lamp examination of her left eye revealed a conjunctival and scleral injection, elevation of the entire circumference of the sclera, and bulging of the sclera on the nasal upper side with a patch of avascular episcleral tissue. Since additional systemic examinations identified no autoimmune diseases such as rheumatism, we diagnosed the patient as dengue fever-associated scleritis.

#### INTERVENTIONS:

Intensive systemic and topical steroids were administered during the initial acute phase. Over the next 15 months, the amount of steroid was tapered off.

#### OUTCOME:

Initial findings for the scleritis gradually declined in response to steroid treatment. Although there was no recurrence of active scleritis, gradual thinning of the sclera continued to occur during the 18-year follow-up.

#### LESSONS:

To the best of our knowledge, this is the first reported case of dengue fever-associated necrotizing scleritis with long-term follow-up. This case suggests the existence of a long-term immune-mediated mechanism during the development of the dengue fever-associated necrotizing scleritis. Dengue fever virus patients found to have red eyes need to be carefully followed and treated, as these eyes might develop thinning of the sclera that could lead to rupture of the globe, thereby resulting in blindness.

**Keywords:** blindness, dengue fever, necrotizing scleritis, scleritis

# Clinical characteristics and visual outcomes in infectious scleritis: a review.

Ramenaden ER, Raiji VR.

*Department of Ophthalmology, George Washington University, Washington, DC, USA.*

## **Abstract**

Infection is a very important but rare cause of scleritis, occurring in about 5%-10% of all patients presenting with scleral inflammation. However, due to the similarity of its presentation, infectious scleritis is often initially managed as autoimmune, potentially further worsening its outcome. The overall visual outcome in infectious scleritis is generally worse than its autoimmune counterparts, perhaps because of the delay in diagnosis or because of the aggressive nature of associated microbes. Thus, there is a definite need for insight into the diagnostic approach and treatment options for this ocular disease process. Several studies and case reports have been published in recent years that have provided useful information regarding the presenting clinical features and etiologic microbial agents in infectious scleritis. This review summarizes the important findings in the literature that may aid in differentiating infectious scleritis from other etiologies, including predisposing factors, microbe-specific characteristics, diagnostic tools, treatment modalities, and outcomes.

## **KEYWORDS:**

Pseudomonas; abscess; infectious scleritis; necrotizing scleritis

# Scedosporium apiospermum infectious scleritis following posterior subtenon triamcinolone acetonide injection: a case report and literature review

Daisuke Todokoro, corresponding author<sup>1</sup> Junki Hoshino,<sup>1</sup> Ayaka Yo,<sup>2</sup> Koichi Makimura,<sup>2</sup> Junko Hirato,<sup>3</sup> and Hideo Akiyama<sup>1</sup>

## Abstract

### Background

Ubiquitous fungi of the *Scedosporium apiospermum* species complex (SASC) cause various opportunistic infections. Posterior subtenon triamcinolone acetonide (STTA) injection is a standard therapy for intraocular inflammation and macular edema. We report a case of *Scedosporium apiospermum* infectious scleritis after a posterior STTA injection.

### Case presentation

A 75-year-old man received a posterior STTA injection to treat macular edema in his left eye. After 3 months, he complained of ocular pain and hyperemia in his left eye. Examination showed a subtenon abscess in the site corresponding with the STTA injection. After incising the abscess, the smear revealed numerous conidia-like structures. Although we suspected fungal infection and started topical voriconazole (VRCZ) and levofloxacin, the inflammation of the eye worsened. Fungal culture revealed filamentous fungus growth. Subsequently, we added systemic VRCZ and performed surgical debridement of the infected sclera and Tenon's capsule. Pathology of the sclera showed fungal hyphae. The antifungal susceptibility test revealed low minimum inhibitory concentrations for miconazole, VRCZ and miconazole (0.06, 0.25 and 0.5 µg/mL, respectively). After 2 months, the ciliary injection subsided and VRCZ therapy was stopped. However, subtenon abscess recurred 1 month after discontinuation of topical VRCZ. Surgical debridement and topical VRCZ were resumed, with the eye finally improving after 5 months of management. The fungal species was identified as *Scedosporium apiospermum sensu stricto* morphologically and by DNA sequencing.

### Conclusions

This case was successfully treated by topical and systemic VRCZ and repeated surgical debridement. Infectious scleritis caused by SASC rarely develops after posterior STTA. SASC can produce conidia in the enclosed subtenon space. Late-onset infectious scleritis after a posterior STTA injection suggests the presence of a fungal infection, including SASC, thereby requiring extensive and prolonged medical and surgical treatment.

**Keywords:** *Scedosporium apiospermum*, Posterior subtenon triamcinolone acetonide injection, Infectious scleritis, Voriconazole

HOSTED BY



ELSEVIER

Contents lists available at ScienceDirect

Journal of Acute Disease

journal homepage: [www.jadweb.org](http://www.jadweb.org)Case report <http://dx.doi.org/10.1016/j.joad.2016.08.015>**Acute anterior necrotizing scleritis: A case report**Yuen Keat Gan<sup>1,2\*</sup>, Syed Shoeb Ahmad<sup>1</sup>, Sheena Mary Alexander<sup>1</sup>, Amir Samsudin<sup>2</sup><sup>1</sup>Department of Ophthalmology, Queen Elizabeth Hospital, Kota Kinabalu, Malaysia<sup>2</sup>Department of Ophthalmology, Faculty of Medicine, University of Malaya, Kuala Lumpur, Malaysia**ARTICLE INFO***Article history:*

Received 1 Jul 2016

Received in revised form 6 Jul 2016

Accepted 12 Jul 2016

Available online 12 Aug 2016

*Keywords:*

Necrotizing

Scleritis

Herpes zoster

Eye

**ABSTRACT**

Necrotizing scleritis is an uncommon but potential disastrous infection to the eye. It is commonly caused by vaso-occlusive autoimmune diseases such as rheumatoid arthritis or surgically-induced, and rarely due to infections. In this article, we presented a rare case of necrotizing scleritis caused by herpes infection in an immunocompromised patient. A 49 years old, retroviral positive gentleman presented to our clinic with a painful, red right eye associated with watering, photophobia and blurring of vision. His right eye rapidly deteriorated leading to an impending perforation of the sclera despite intensive antimicrobial therapy. The patient was started on acyclovir ointment and subsequently improved remarkably salvaging the eye from the need of an evisceration. Although the visual prognosis was poor, structural integrity of the eye was achieved.

## Original Research

# Necrotizing scleritis and peripheral ulcerative keratitis associated with Wegener's granulomatosis.

*State Key Laboratory of Ophthalmology, Corneal Department, Zhongshan Ophthalmic Center, Sun Yat-sen University, 54 Xianlien Road, Guangzhou, 510060, People's Republic of China.*

## Abstract

### INTRODUCTION:

To evaluate the complications, efficacy of medical and surgical treatment, and outcome in patients with necrotizing scleritis and peripheral ulcerative keratitis associated with Wegener's granulomatosis.

### METHODS:

The authors reviewed a series of seven patients with Wegener's granulomatosis treated in the Corneal Department of Zhongshan Ophthalmic Center and the Department of Ophthalmology of Kashgar First People's Hospital. A detailed chart review was performed to determine demographic characteristics, ocular presentation, biopsy and laboratory testing results, treatment, and final outcome.

### RESULTS:

Wegener's granulomatosis was indicated by ocular and/or systemic findings; biopsy and immunohistochemistry results supported the diagnosis. Patients with necrotizing scleritis and/or peripheral ulcerative keratitis received cytotoxic immunosuppressive therapy; this, in conjunction with surgical treatment, halted the relentlessly progressive inflammation and preserved the integrity of the globe in 78% of eyes. Best-Corrected Visual Acuity remained stable in four of nine eyes, was improved in two of nine eyes, and decreased in three of nine eyes (secondary to cataract and/or stromal scarring). Although one patient died, treatment with corticosteroids and cytotoxic agents dramatically improved outcomes in these patients.

### CONCLUSION:

Necrotizing scleritis and peripheral ulcerative keratitis often have a poor visual outcome, and may herald an underlying systemic vasculitis. Wegener's granulomatosis, with the associated necrotizing scleritis and peripheral ulcerative keratitis, should be managed with aggressive immunosuppression to avoid the associated morbidity and mortality. Thus, the ophthalmologist may play a significant role in its early diagnosis and treatment.

# **Necrotizing nocardial scleritis after combined penetrating keratoplasty and phacoemulsification with intraocular lens implantation: a case report and review of the literature.**

*Ramos-Esteban JCI, Servat JJ, Silva RS, Ambrósio R Jr, Tauber S, Bia F.*

*Department of Ophthalmology and Visual Sciences, Yale University School of Medicine, New Haven Connecticut, USA.*

## **Abstract**

We report the history and clinical presentation of an 88-year-old female with Fuchs dystrophy who developed an acute anterior necrotizing scleritis in her left eye 23 months after an uncomplicated combined penetrating keratoplasty and phacoemulsification with intraocular lens implantation which progressed to scleral perforation with uveal prolapses. The patient underwent a complete systemic work-up for both autoimmune and infectious causes of scleritis. Surgical specimens of the area of scleral perforation were sent for histology and microbiologic studies. Analysis of surgical specimens revealed the presence of culture-proven *Nocardia asteroides* as a causative agent for the patient's scleral perforation. Results of her systemic autoimmune work-up were not conclusive. Successful treatment with tectonic scleral reinforcement with donor corneal tissue and preserved pericardium, oral and topical trimethoprim-sulfamethoxazole and topical amikacin salvaged the globe and increased vision. The patient's final best-corrected visual acuity sixteen months after her last operation remains 20/70. Prompt surgical intervention with submission of appropriate specimens for pathological diagnosis and microbiology, along with consultation with rheumatologic and infectious disease specialists, are mandatory to minimize visual loss in cases of suspected infectious necrotizing scleritis.

# Nocardial scleritis: A case report and a suggested algorithm for disease management based on a literature review

Laura Pires da Cunha,<sup>a</sup> Verena Juncal,<sup>a</sup> Cecília Godoy Carvalhaes,<sup>b</sup> Sylvia Cardoso Leão,<sup>c</sup> Erica Chimara,<sup>d</sup> and Denise Freitas

*Department of Ophthalmology and Visual Sciences, Escola Paulista de Medicina, Universidade Federal de São Paulo, Hospital São Paulo. 821, Botucatu Street, São Paulo, SP, Brazil*

*bDepartment of Microbiology, Immunology and Parasitology, Escola Paulista de Medicina, Universidade Federal de São Paulo. 715, Napoleão de Barros Street, São Paulo, SP, Brazil*

*cDepartment of Microbiology, Immunology and Parasitology, Escola Paulista de Medicina, Universidade Federal de São Paulo. 862, Botucatu Street, São Paulo, SP, Brazil*

## Abstract

### Purpose

To report a case of nocardial scleritis and to propose a logical treatment algorithm based on a literature review.

### Observations

It is important to suspect a nocardial infection when evaluating anterior unilateral scleritis accompanied by multiple purulent or necrotic abscesses, especially in male patients with a history of chronic ocular pain and redness, trauma inflicted by organic materials, or recent ophthalmic surgery. A microbiological investigation is essential. In positive cases, a direct smear reveals weakly acid-fast organisms or Gram-positive, thin, beading and branching filaments. Also, the organism (usually) grows on blood agar and Lowenstein–Jensen plates. An infection can generally be fully resolved by debridement of necrotic areas and application of topical amikacin drops accompanied by systemic sulfamethoxazole–trimethoprim.

### Conclusions and significance

Together with the case report described, we review data on a total of 43 eyes with nocardial scleritis. Our proposed algorithm may afford a useful understanding of this sight-threatening disease, facilitating easier and faster diagnosis and management.

**Keywords:** Nocardia, Microbiology, Infection, Scleral disease, Necrotizing

# Long-term, multicenter evaluation of subconjunctival injection of triamcinolone for non-necrotizing, noninfectious anterior scleritis.

Sohn EH1, Wang R, Read R, Roufas A, Teo L, Moorthy R, Albini T, Vasconcelos-Santos DV, Dustin LD, Zamir E, Chee SP, McCluskey P, Smith R, Rao N.

*Doheny Eye Institute and Department of Ophthalmology, Keck School of Medicine of the University of Southern California, Los Angeles, California, USA.*

## Abstract

### PURPOSE:

We sought to characterize the long-term outcomes and complications of subconjunctival triamcinolone acetonide injection (STI) for non-necrotizing, noninfectious anterior scleritis.

### DESIGN:

Retrospective, interventional, noncomparative, multicenter study.

### PARTICIPANTS:

Sixty-eight eyes of 53 patients from 9 participating hospitals in the United States, Singapore, and Australia. Only eyes with 6 or more months of follow-up were included.

### INTERVENTION:

Subconjunctival injection of 2 to 8 mg of triamcinolone acetonide was administered to eyes with non-necrotizing, noninfectious anterior scleritis.

### MAIN OUTCOME MEASURES:

Resolution of signs and symptoms, time to recurrence of scleritis, and side effect profile.

### RESULTS:

Median follow-up was 2.3 years (range, 6 months to 8.3 years). Sixty-six eyes (97.0%) experienced improvement of signs and symptoms after 1 injection. Twenty-four months after a single injection, 67.6% of eyes remained recurrence-free, whereas at 48 months, 50.2% were recurrence-free. Some 55.0% of patients who had adverse effects from systemic medications were off all systemic medications at last follow-up; 55.0% of patients who were taking systemic medications at the time of first triamcinolone acetonide injection were not taking prednisone and immunosuppressants at this time; 76.2% of patients still requiring systemic agents had associated systemic disease. Fourteen eyes (20.6%) had ocular hypertension not requiring intraocular pressure (IOP)-lowering therapy. Two eyes (2.9%) were treated with topical IOP-lowering agents alone, and 2 eyes required surgical intervention for glaucoma. None developed scleral necrosis or melt.

### CONCLUSIONS:

This retrospective, international study carried out at 9 hospitals suggests that STI can treat non-necrotizing, noninfectious anterior scleritis with side effects limited to elevated IOP in a few patients. Although no cases of scleral melt or necrosis were observed, we cannot definitively conclude that this may not occur after STI. Intraocular pressure should be closely monitored after STI. Subconjunctival triamcinolone acetonide injection may be useful as adjuvant therapy or to decrease systemic medication burden.

# Ocular Autoimmune Systemic Inflammatory Infectious Study (OASIS)- report 4: analysis and outcome of scleritis in an East Asian population.

Bin Ismail MA1, Lim RHF2, Fang HM1, Wong EPY1, Ling HS1, Lim WK1,3, Teoh SC1,3, Agrawal R4.

## Abstract

### BACKGROUND:

The purpose of this study is to evaluate the spectrum of scleritis from database of Ocular Autoimmune Systemic Inflammatory Infectious Study (OASIS) at a tertiary eye referral eye institute in Singapore. Clinical records of 120 patients with scleritis from a database of 2200 patients from Ocular Autoimmune Systemic Inflammatory Infectious Study (OASIS) were reviewed.

### RESULTS:

56.6% were females, with a mean age of  $48.6 \pm 15.9$  years. 75 (62.5%) had diffuse anterior scleritis, 25 (20.8%) had nodular anterior scleritis, 7 (5.8%) had necrotizing anterior scleritis and 13 (10.8%) had posterior scleritis. Ocular complications were observed in 53.3% of patients, including anterior uveitis (42.5%), raised intraocular pressure (12.5%), and corneal involvement (11.7%). Autoimmune causes were associated with 31 (25.8%) of patients, and 10 (8.3%) patients had an associated infective etiology, much higher than Caucasian studies. 53.3% of patients were treated with oral corticosteroids while 26.7% required immunosuppressives.

### CONCLUSIONS:

Infective etiology needs to be considered in patients of scleritis from Asian origin. In our study and in OASIS database, scleritis was associated with systemic autoimmune disease and ocular complications.

### KEYWORDS:

Complications; Epidemiology; Scleritis; Treatment



# **Smart study in short time! Constellation of diagnostic criterias in uveitis**

**Authors**

**Dr. Bharat Gurnani**

**Dr. Annamalai. O**

**Dr. S.Bala Murugan**

**Aravind Eye Hospital, Pondicherry - 605007**

## DIAGNOSTIC CRITERIA

### INTRAOCULAR TUBERCULOSIS

#### I. Clinical Presentations in Intraocular Tuberculosis

1	Anterior uveitis	Granulomatous, Non-granulomatous, iris nodules, ciliary body tuberculoma
2	Intermediate uveitis	Granulomatous, Non-granulomatous with organizing exudates in the pars plana/ peripheral uvea
3	Posterior and panuveitis	Choroidal tubercle Choroidal tuberculoma Subretinal abscess Serpiginous-like choroiditis
4	Retinitis and retinal vasculitis	
5	Neuroretinitis and optic neuropathy	
6	Endophthalmitis and panophthalmitis	

Eales disease is considered by some to reflect tuberculous infection/hypersensitivity.

#### II. Ocular Investigations

- a. Demonstration of AFB by microscope or culture of *M. tuberculosis* from the ocular fluids.
- b. Positive polymerase chain reaction from ocular fluids for IS 6110 or other conserved sequences in *M. tuberculosis* genome.

#### III. Systemic Investigations

- a. Positive Mantoux reaction.
- b. Evidence of healed or active tubercular lesion on radiography of the chest.
- c. Evidence of confirmed active extrapulmonary tuberculosis (either by microscopic examination or by culture of the affected tissue for *M. tuberculosis*).

#### IV. Exclusion of Other Uveitis Entities

In the geographic regions where tuberculosis is low in incidence, other causes of uveitis must be excluded by various laboratory investigations including serology for syphilis, toxoplasmosis and others.

#### V. Therapeutic Test

A positive response to 4-drug ATT (isoniazid, rifampicin, ethambutol, and pyrazinamide) over a period of 4 to 6 weeks. Therapeutic trial with single drug isoniazid should be avoided due to risk of development of resistance. It is important to refer such a patient to a TB expert who can initiate and monitor the treatment. The therapeutic response to ATT in the eye should, however be evaluated by the

ophthalmologist.

Confirmed (Definitive) case of intraocular tuberculosis : Any one or more of the clinical signs listed under section I in combination with any of the positive tests under section II.

Presumed ocular tuberculosis : Any one or more of the clinical signs listed under section I in combination with any of the positive tests under section III or a positive therapeutic trial section V in combination with section IV.

Gupta V, Gupta A, Rao NA. Intraocular tuberculosis-an update. *Surv Ophthalmol.* 2007 Nov-Dec;52(6):561-87.

## **SARCOIDOSIS**

### **Clinical signs suggestive of ocular sarcoidosis**

- (1) mutton-fat keratic precipitates (KPs)/small granulomatous KPs and/or iris nodules (Koeppe/Busacca),
- (2) trabecular meshwork (TM) nodules and/or tent-shaped peripheral anterior synechiae (PAS),
- (3) vitreous opacities displaying snowballs/strings of pearls,
- (4) multiple chorioretinal peripheral lesions (active and/or atrophic),
- (5) nodular and/or segmental peri-phlebitis (+/- candlewax drippings) and/or retinal macroaneurysm in an inflamed eye,
- (6) optic disc nodule(s)/granuloma(s) and/or solitary choroidal nodule, and
- (7) bilaterality.

**Laboratory investigations or investigational procedures** that were judged to provide value in the diagnosis of ocular sarcoidosis

- (1) negative tuberculin skin test in a BCG-vaccinated patient or in a patient having had a positive tuberculin skin test previously,
- (2) elevated serum angiotensin converting enzyme (ACE) levels and/or elevated serum lysozyme\*,
- (3) chest x-ray revealing bilateral hilar lymphadenopathy (BHL),
- (4) abnormal liver enzyme tests (any two of alkaline phosphatase, ASAT, ALAT, LDH or  $\gamma$  -GT), and
- (5) chest CT scan in patients with a negative chest x-ray result.

\* Test required in patients treated with ACE inhibitors.

No	Diagnostic criteria for ocular sarcoidosis	
	All other possible causes of uveitis, in particular tuberculous uveitis, have to be ruled out	
1	Biopsy supported diagnosis with a compatible uveitis	Definite ocular Sarcoidosis <sup>#</sup>
2	Biopsy not done; presence of bilateral hilar lymphadenopathy (BHL) with a compatible uveitis	Presumed ocular Sarcoidosis <sup>#</sup>
3	Biopsy not done and BHL negative; presence of three of the suggestive intraocular signs and two positive investigational tests	Probable ocular Sarcoidosis <sup>#</sup>
4	Biopsy negative, four of the suggestive intraocular signs and two of the investigations are positive	Possible ocular Sarcoidosis <sup>#</sup>

<sup>#</sup> Used in the sense of intraocular inflammatory lesions both in patients with systemic disease and in patients with disease seemingly limited to the eye without any clinically detectable involvement of another organ.

Herbert CP, Rao NA, Mochizuki M; members of Scientific Committee of First International Workshop on Ocular Sarcoidosis. International criteria for the diagnosis of ocular sarcoidosis: results of the first International Workshop On Ocular Sarcoidosis (IWOS). Ocul Immunol Inflamm. 2009 May-Jun;17(3):160-9.

## VOGT-KOYANAGI-HARADA SYNDROME

### DIAGNOSTIC CRITERIA

- I. No history of penetrating ocular trauma or surgery preceding the initial onset of uveitis
- II. No clinical or laboratory evidence suggestive of other ocular disease entities
- III. Bilateral ocular disease (either A or B below must be met depending on the stage of disease when the patient is examined):
  - A. Early manifestations
    1. Diffuse choroiditis (with or without anterior uveitis, vitreous inflammatory reaction, or optic disk hyperemia), as manifested by either:
      - a. Focal areas of subretinal fluid, or
      - b. Bullous serous retinal detachments
    2. With equivocal fundus findings, then both of the following must be present as well:
      - a. Fluorescein angiography showing focal delayed choroidal perfusion, multifocal pinpoint leakage, large placoid areas of hyperfluorescence, pooling of dye within subretinal fluid, and optic nerve staining
      - b. Ultrasonography showing diffuse choroidal thickening without evidence of posterior scleritis
  - B. Late manifestations
    1. History suggestive of prior presence of findings from III A, and either both 2 and 3 below, or multiple signs from 3
    2. Ocular depigmentation
      - a. Sunset glow fundus, or
      - b. Sugiura sign
    3. Other ocular signs

- a. Nummular chorioretinal depigmentation scars, or
- b. RPE clumping and/or migration, or
- c. Recurrent or chronic anterior uveitis

IV. Neurologic/auditory findings (may have resolved by time of examination):

A. Meningismus (malaise, fever, headache, nausea, abdominal pain, stiffness of the neck and back, or a combination of these factors; headache alone is not sufficient to meet definition of meningismus, however) or

B. Tinnitus, or

C. Cerebrospinal fluid pleocytosis

V. Integumentary findings (not preceding onset of central nervous system or ocular disease)

A. Alopecia, or

B. Poliosis, or

C. Vitiligo

Complete Vogt-Koyanagi-Harada syndrome

Criteria I to V must be present

Incomplete Vogt-Koyanagi-Harada syndrome

Criteria I to III and either IV or V from above

Probable Vogt-Koyanagi-Harada syndrome

Criteria I to III from above must be present

Isolated ocular disease

Read RW, Holland GN, Rao NA, et al. Revised diagnostic criteria for Vogt-Koyanagi-Harada disease: report of an international committee on nomenclature. *Am J Ophthalmol.* 2001;131(5):647-652.

## **REACTIVE ARTHRITIS (REITER'S SYNDROME)**

### MAJOR CRITERIA

1. Joints : Polyarthritits
2. Eyes : Conjunctivitis, iridocyclitis
3. Genitourinary : Urethritis
4. Skin : Keratoderma blennorrhagica, balanitis circinata

### MINOR CRITERIA

1. Joints : Plantar Fasciitis, Achilles tendonitis, sacroiliitis, spondylitis, Pain in lower part of back
2. Eyes : Keratitis
3. Genitourinary : Cystitis, prostatitis
4. Skin : Painless oral mucosal lesions, psoriatic eruptions, nail changes
5. Gastrointestinal : Diarrhea associated with other symptoms in the complex
6. Laboratory findings : Leukocytosis, increased serum  $\alpha_1$ ,  $\alpha_2$  or  $\gamma$  globulins, inflammation in the synovial fluid, Positive HLA B-27

Reactive arthritis is:

Definite : if three major criteria or two major and three minor

Probable : if two major and two minor\*

Possible : if two major and one minor\*

\* Manifestations must be found in different categories

Lee DA, Barker SM, Su WPD et al.: The clinical diagnosis of Reiter's syndrome, *Ophthalmology* 1986; 93: 350–6.

## **REACTIVE ARTHRITIS (REITER'S SYNDROME)**

### MAJOR CRITERIA

Polyarthritis

Conjunctivitis, iridocyclitis

Urethritis

Keratoderma blennorrhagica, balanitis circinata

### MINOR CRITERIA

Fasciitis, tendonitis, sacroiliitis, spondylitis

Keratitis

Cystitis, prostatitis

Oral mucosal lesions, psoriasis-like rash, nail changes

Diarrhea, leukocytosis, increased serum globulins, inflammation in the synovial fluid

Definite : if three major criteria or two major and three minor

Probable : if two major and two minor

Whitcup SM. Anterior Uveitis. In: Nussenblatt RB, editor. *Uveitis Fundamentals and clinical practice*. 4<sup>th</sup> ed. China: Mosby Elsevier; 2010. p. 255-6.

Modified from Lee DA, Barker SM, Su WPD et al.: The clinical diagnosis of Reiter's syndrome. *Ophthalmology* 1986;93:350-6.

## **BEHCET DISEASE**

### **DIAGNOSTIC SYSTEM FOR BEHCET DISEASE (JAPAN)**

#### Major Criteria

1. Recurrent oral aphthous ulcers
2. Skin lesions (erythema nodosum, acneiform pustules, folliculitis)
3. Recurrent genital ulcers

4. Ocular inflammatory disease

#### Minor Criteria

1. Arthritis
2. Gastrointestinal ulceration
3. Epididymitis
4. Systemic vasculitis or associated complications
5. Neuropsychiatric symptoms

#### Types of Behcet Disease

Complete (4 major criteria)

Incomplete (3 major criteria or ocular involvement with 1 other major criterion)

Suspect (2 major criteria with no ocular involvement)

Possible (1 major criterion)

Adapted from Foster CS, Vitale AT. Diagnosis and Treatment of Uveitis. Philadelphia, PA: WB Saunders;2002.

### **CRITERIA FOR DIAGNOSIS OF BEHÇET'S DISEASE**

#### MAJOR CRITERIA

1. Recurrent aphthous ulcers of oral mucosa
2. Skin lesions
  - a. Erythema nodosum, acne, cutaneous hypersensitivity thrombophlebitis
3. Genital ulcers
4. Ocular inflammatory disease
  - a. Recurrent anterior and posterior

#### MINOR CRITERIA

1. Arthritis
2. Intestinal ulcers
3. Epididymitis
4. Vascular disease
  - a. Obliteration, occlusion, aneurysm
5. Neuropsychiatric symptoms

Complete type

Four major symptoms simultaneously or at different times

Incomplete type

Three major symptoms simultaneously or at different times

or

Typical recurrent ocular disease with one other major criterion

Suspect type

Two major symptoms, excluding ocular

Possible type

One major symptom

Modified from Behçet's Disease Research Committee: Clinical research section recommendations, Jpn J Ophthalmol 1974; 18: 291–294.

## **DIAGNOSTIC CRITERIA OF INTERNATIONAL STUDY GROUP FOR BEHÇET'S DISEASE**

### **RECURRENT ORAL ULCERATION**

Minor or major aphthous lesions or herpetiform-like lesions need to have been observed by the physician or patient at least three times within a 12-month period.

### **PRESENCE OF TWO OTHER CRITERIA**

Recurrent genital ulceration

Observation by the physician or patient of the aphthous ulceration or scar is required

Eye lesions

The ocular disease can include anterior and/or posterior uveitis, cells in the vitreous, or the presence of a retinal vasculitis.

Skin lesions

These changes, noted by the physician or patient, include erythema nodosum, pseudofolliculitis, and papulopustular lesions. In addition, lesions would include an acneiform nodule in post-adolescent patients not receiving corticosteroid therapy.

Positive pathergy test result

Read by physician at 24–48 hours.

Modified from International Study Group for Behçet's Disease: Criteria for diagnosis of Behçet's disease, Lancet 1990; 335: 1078–1080.

## BIRDSHOT CHORIORETINOPATHY

### BIRDSHOT CHORIORETINOPATHY: DIAGNOSTIC CRITERIA FOR RESEARCH PURPOSES

#### Required characteristics

1. Bilateral disease
2. Presence of at least three peripapillary 'birdshot lesions'\* inferior or nasal to the optic disc in one eye
3. Low-grade anterior segment intraocular inflammation (defined as  $\leq 1$  + cells in the anterior chamber†)
4. Low grade vitreous inflammatory reaction (defined as  $\leq 2$  + vitreous haze‡)

#### Supportive findings

1. HLA-A29 positivity
2. Retinal vasculitis
3. Cystoid macular edema

#### Exclusion criteria

1. Keratic precipitates
2. Posterior synechiae
3. Presence of infectious, neoplastic, or other inflammatory diseases that can cause multifocal choroidal lesions§

\*Cream-colored, irregular or elongated, choroidal lesions with indistinct borders, the long axis of which is radial to the optic disc

†As defined by the Standardization of Uveitis Nomenclature (SUN) Working Group

‡As defined by Nussenblatt and associates

§Patient should be evaluated for the following disorders by appropriate history taking, physical examination, or laboratory tests: sarcoidosis with panuveitis or posterior uveitis; intraocular lymphoma; acute posterior multifocal placoid pigment epitheliopathy (APMPPE); multifocal choroiditis and panuveitis; punctate inner choroidopathy (PIC); multifocal evanescent white dot syndrome (MEWDS); pars planitis syndrome; posterior scleritis; sympathetic ophthalmia; Vogt–Koyanagi–Harada disease (chronic stage); syphilis; tuberculosis

Levinson RD, Brezin A, Rothova A, et al. Research criteria for the diagnosis of birdshot chorioretinopathy: results of an international consensus conference. *Am J Ophthalmol* 2006; 141(1): 185–187.

#### Acute Retinal Necrosis

1. The American Uveitis Society established the following as diagnostic criteria: One or more foci of retinal necrosis with discrete borders, located in the peripheral retina
2. Rapid progression in absence of antiviral therapy
3. Circumferential spread

4. Occlusive vasculopathy, affecting arterioles
5. Prominent vitritis and/or anterior chamber inflammation

Kyrieleis' Arteriolitis may be seen in ARN.

## Reference

Koushik Tripathy, MD (AIIMS), FRCS (Glasgow), Lauren Taney, MD, Murtaza Adam, Vinay A. Shah M.D. and Vinay A. Shah M.D. AAO.Sep 2017

JRA

## International League of Associations for Rheumatology (ILAR) classification of juvenile idiopathic arthritis (JIA)

JIA can be diagnosed if age at onset is under 16 years, disease duration is 6 weeks or greater, and other known conditions are excluded.

- **Systemic-onset JIA:** Systemic arthritis is diagnosed if there is arthritis in 1 or more joints with, or preceded by, fever of at least 2 weeks' duration. Signs or symptoms must have been documented daily for at least 3 days and accompanied by 1 or more of the following: evanescent rash, generalised lymphadenopathy, hepato/splenomegaly, serositis. (Exclusions are A, B, C, and D from the exclusion list below.)
- **Persistent or extended oligoarthritis:** Oligoarthritis is diagnosed if there is arthritis affecting 1 to 4 joints during the first 6 months. Persistent oligoarthritis affects up to 4 joints throughout the course of the disease, and extended oligoarthritis affects more than 4 joints after the first 6 months of disease. (Exclusions are A, B, C, D, and E from the exclusion list below.)
- **RF-negative polyarthritis:** Polyarthritis (RF-negative) is diagnosed if there is rheumatoid factor (RF)-negative arthritis affecting 5 or more joints during the first 6 months of disease. (Exclusions are A, B, C, D, and E from the exclusion list below.)
- **RF-positive polyarthritis:** Polyarthritis (RF-positive) is diagnosed if there is RF-positive arthritis affecting 5 or more joints during the first 6 months of disease. Two or more RF tests (taken at least 3 months apart) are positive during the first 6 months of disease. (Exclusions are A, B, C, and E from the exclusion list below.)
- **Psoriatic JIA:** Psoriatic arthritis is diagnosed if there is arthritis and psoriasis, or arthritis and at least 2 of the following: dactylitis, nail pitting, onycholysis, and/or family history of psoriasis (in a first-degree relative). (Exclusions are B, C, D, and E from the exclusion list below.)
- **Enthesitis-related arthritis:** Enthesitis-related arthritis is diagnosed if there is arthritis and/or enthesitis with at least 2 of the following: presence or history of sacroiliac joint tenderness with or without inflammatory lumbosacral pain; presence of HLA B27 antigen; onset of arthritis in a male over 6 years of age; acute (symptomatic) anterior uveitis; history of ankylosing spondylitis, enthesitis-related arthritis, sacroiliitis with inflammatory bowel disease, Reiter's syndrome, or acute anterior uveitis in a first-degree relative. (Exclusions are A, D, and E from the exclusion list below.)
- **Undifferentiated:** Undifferentiated arthritis is diagnosed if there is arthritis that does not fulfil criteria in any of the above categories or that fulfils criteria for 2 or more of the above categories.

## Exclusions:

A. Psoriasis or history of psoriasis in patients or first-degree relatives. B. Arthritis in HLA B27 positive males beginning after the age of 6 years. C. Ankylosing spondylitis, enthesitis-related arthritis, sacroiliitis with inflammatory bowel disease, Reiter's syndrome, acute anterior uveitis, or history of 1 of these disorders in first-degree relatives. D. Presence of IgM rheumatoid factor on at least 2 occasions at least 3 months apart. E. Presence of systemic JIA in patients.

1. Merino R, de Inocencio J, Garcia-Consuegra J. Evaluation of Revised International League of Associations for Rheumatology Classification Criteria for Juvenile Idiopathic Arthritis in Spanish

Children (Edmonton 2001). J Rheumatol 2005;32:559-61.

2. Petty RE, Southwood TR, Manners P, et al. International League of Associations for Rheumatology. International League of Associations for Rheumatology classification of juvenile idiopathic arthritis: second revision, Edmonton, 2001. J Rheumatol. 2004;31:390-392.
3. Prakken B, Albani S, Martini A. Juvenile idiopathic arthritis. Lancet. 2011;377(9783):2138-2149.

## **SLE**

The SLICC criteria for SLE classification requires: 1) Fulfillment of at least four criteria, with at least one clinical criterion AND one immunologic criterion OR 2) Lupus nephritis as the sole clinical criterion in the presence of ANA or anti-dsDNA antibodies.

### Clinical Criteria:

1. Acute cutaneous lupus
2. Chronic cutaneous lupus
3. Oral ulcers: palate
4. Nonscarring alopecia (diffuse thinning or hair fragility with visible broken hairs)
5. Synovitis involving two or more joints, characterized by swelling or effusion OR tenderness in two or more joints and thirty minutes or more of morning stiffness.
6. Serositis
7. Renal
8. Neurologic
9. Hemolytic anemia
10. Leukopenia (< 4000/mm<sup>3</sup> at least once)
11. Thrombocytopenia (<100,000/mm<sup>3</sup>) at least once

### Immunological Criteria

1. ANA above laboratory reference range
2. Anti-dsDNA above laboratory reference range, except ELISA: twice above laboratory
3. Anti-Sm
4. Antiphospholipid antibody: any of the following
5. Low complement
6. Direct Coombs test in the absence of hemolytic anemia

## **References:**

- 1. Petri M, Orbai A-M, Alarcón GS, Gordon C, Merrill JT, Fortin PR, Bruce IN, Isenberg D, Wallace DJ, Nived O, Sturfelt G, Ramsey-Goldman R, Bae SC, Hanly JG, Sanchez-Guerrero J, Clarke A, Aranow C, Manzi S, Urowitz MB, Gladman DD, Kalunian K, Costner M, Werth V, Zoma A, Bernatsky S, Ruiz-Irastorza G, Khamashta M, Jacobsen S, Buyon JP, Maddison P, Dooley MA, Van Vollenhoven R, Ginzler E, Stoll T, Peschken C, Jorizzo JL, Callen JP, Lim S, Fessler BJ, Inanc M, Kamen DL, Rahman A, Steinsson K, Franks Jr. AG, Sigler L, Hameed S, Fang H, Pham N, Brey R, Weisman MH, McGwin Jr. G, Magder LS. Derivation and validation of Systemic Lupus International Collaborating Clinics (SLICC) classification criteria for systemic lupus erythematosus. Arthritis Rheum 2012; 64:2677-2686.
- 2. Navarra SV, Guzmán RM, Gallacher AE, Hall S, Levy RA, Jimenez RE, Li EK-M, Thomas M, Kim H-Y, León MG, Tanasescu C, Nasonov E, Lan J-L, Pinela L, Zhong ZJ, Freimuth W, Petri MA, for the BLISS-52 Study Group. Efficacy and safety of belimumab in patients with active systemic lupus

erythematosis: a randomised, placebo-controlled, phase 3 trial. *Lancet* 2011; 377:721-731.

## 8.Reactive arthritis

Although there are no definitive criteria to diagnose the existence of reactive arthritis, the American College of Rheumatology has published sensitivity and specificity guidelines.<sup>[16]</sup>

Percent Sensitivity and Specificity of Various Criteria for Typical Reactive Arthritis		
Method of diagnosis	Sensitivity	Specificity
1. Episode of arthritis of more than 1 month with urethritis and/or cervicitis	84.3%	98.2%
2. Episode of arthritis of more than 1 month and either urethritis or cervicitis, or bilateral conjunctivitis	85.5%	96.4%
3. Episode of arthritis, conjunctivitis, and urethritis	50.6%	98.8%
4. Episode of arthritis of more than 1 month, conjunctivitis, and urethritis	48.2%	98.8%

Ref-American College of Rheumatology. "Arthritis and Rheumatism". Retrieved May 16, 2011.

## 9.Spondyloarthropathy

According to the Brazilian Consensus of Spondyloarthropathies,<sup>30</sup> the modified New York criteria and the European Spondyloarthropathy Study Group (ESSG) criteria (Table 1) continue to be widely used. It is worth noting that, similarly to most classifications, such criteria are useful for population studies and to assess individual patients, but the diagnosis of spondyloarthritis should not be ruled out if the criteria are not met.<sup>31</sup>

Table 1 Criteria	
New York criteria (1984)	ESSG criteria (1991)
<ul style="list-style-type: none"> <li>- Low back pain</li> <li>- Limitation of lumbar spine motion in both the sagittal and frontal planes</li> <li>- Limitation of chest expansion</li> <li>- Bilateral grade 2–4 sacroiliitis</li> <li>- Unilateral grade 3–4 sacroiliitis</li> </ul>	<ul style="list-style-type: none"> <li>- Inflammatory spinal pain OR synovitis (asymmetric, lower extremities) AND at least one of the criteria below:               <ul style="list-style-type: none"> <li>- Positive family history (AS, psoriasis, anterior uveitis, inflammatory bowel disease)</li> <li>- Cutaneous psoriasis</li> <li>- Urethritis or acute diarrhea within four weeks before onset of arthritis</li> <li>- Pain alternating between the two buttocks</li> <li>- Enthesopathy (insertion of the Achilles tendon or plantar fascia)</li> <li>- Sacroiliitis (bilateral grade 2–4 or unilateral grade 3–4)</li> </ul> </li> </ul>
<p>ESSG: European Spondyloarthropathy Study Group; AS: ankylosing spondylitis.            New York criteria: AS is defined when the fourth or fifth criterion is present plus some clinical criteria.<sup>30</sup>            ESSG criteria: AS is diagnosed in the presence of at least one major and one minor criterion.<sup>31</sup></p>	

Ref-van der Linden S, Valkenburg HA, Cats A. Evaluation of diagnostic criteria for ankylosing spondylitis. A proposal for modification of the New York criteria. *Arthritis Rheum* 1984;27(4):361-8.

# 10.TINU

Table 2: Diagnostic criteria for tubulointerstitial nephritis and uveitis (TINU) syndrome [19].

I. Definite TINU	II. Probable TINU	III. Possible TINU
(A) Acute interstitial nephritis (AIN): by renal biopsy or if biopsy is not done but clinical course and laboratory examinations including abnormal urinalysis and renal function examinations are all consistent with AIN	(A) AIN: by renal biopsy or laboratory findings and clinical course	(A) AIN: diagnosed by laboratory findings and
(B) Uveitis: typical bilateral anterior uveitis	(B) Uveitis: atypical (not bilateral anterior uveitis) Or (A) AIN: diagnosed by laboratory findings and clinical course but not all laboratory findings or clinical course complete, consistent, or available (B) Uveitis: typical bilateral anterior uveitis	clinical course but not all laboratory findings or clinical course complete, consistent, or available (B) Uveitis: atypical uveitis (not bilateral anterior uveitis)

# 11.FUCHS HETEROCHROMIC CYCLITIS

Table 3. Diagnostic criteria for Fuchs' heterochromic cyclitis.


I. Essential findings <sup>a</sup>	II. Associated findings <sup>b</sup>
<ul style="list-style-type: none"> <li>- Absence of acute symptoms (severe redness, pain and photophobia)</li> <li>- Characteristic keratic precipitates and/or minimal cells and flare in the aqueous (1+ or 2+)</li> <li>- Diffuse iris stromal atrophy</li> <li>- Absence of synechiae</li> </ul>	<ul style="list-style-type: none"> <li>- Unilaterality of the uveitis</li> <li>- Heterochromia</li> <li>- IPE atrophy</li> <li>- Subcapsular cataract</li> <li>- Elevated intraocular pressure</li> <li>- Vitreous opacities</li> <li>- Chorioretinal lesions</li> </ul>

IPE = iris posterior pigment epithelium.

<sup>a</sup> All must be present.

<sup>b</sup> At least two must be present.

Ellen La Hey, Goitze Seerp Baarsma, Aize Kijlstra. Clinical analysis of Fuchs' heterochromic cyclitis. Documenta Ophthalmologica 1991



**CME Endorsed & Supported**

**by**

**Uveitis Society (India)**

# BENGAL UVEITIS SUMMIT 2018

Date: 15/12/2018

Venue: Eastern Command Hospital

The Uveitis Annual Conference had been attended by 87 delegates including the faculties. This being a working day the attendance could have increased had it been on a Sunday. The program started at 9 am. The lectures were well accepted, and the following discussions were all the more thought-provoking. The Panel Discussion conducted by Dr. Parthopratin Dutta Majumder and Dr Dipankar Das raised many unanswered questions which were never asked before. As one of our National Faculty said Bengal Uveitis Summit is now the second largest Uveitis Conference after the National Conference in India. We feel proud to have created a platform to foster and nurture academic discussions and advancements pertaining to Uveitis and its related aspects at the National level.

*Report Submitted by : Dr. Debashish Das*



## **“An evening with Prof. Narsing Rao”**

**Date: 11/01/2019**

**Venue: Sankara Nethralaya, Chennai**

A CME programme on uveitis “An evening with Prof. Narsing Rao” was held on 11th January 2019, 5-8 pm at Sankara Nethralaya, Chennai. Seventy nine delegates from Tamil Nadu and other parts of the country attended the meeting. Prof. Narsing Rao delivered a guest lecture “Approach to diagnosis and management of posterior and panuveitis”. The lecture was for 45 minutes with excellent deliberation of the subject. There was also presentation 5 challenging cases of uveitis and scleritis. Prof. Narsing Rao and Dr. Kalpana Babu, Vice president of USI discussed these cases. The meeting was followed by dinner.

*Report Submitted by : Dr. S Sudharshan*



# COS - Uveitis Basic Course

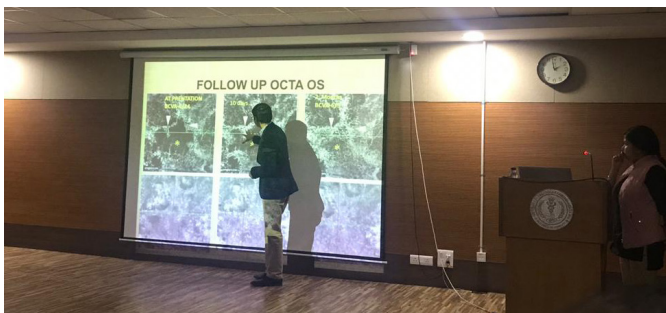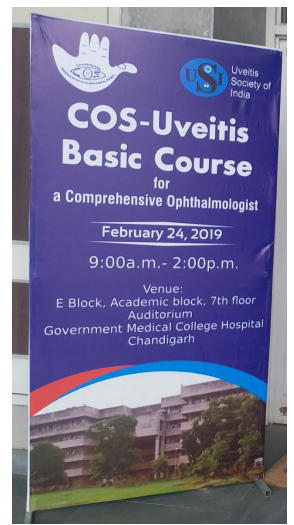
Date : 24/02/2019

Venue: PGI Chandigarh

A half day CME was conducted in the North zone at Chandigarh under the aegis of Chandigarh Ophthalmological Society(COS) in collaboration with USI. This CME focussed on a pertinent topic like 'Basics of uveitis for a comprehensive Ophthalmologist.' It was a well attended CME in which about 75 Ophthalmologists actively participated. It was attended by private practitioners and students from neighbouring medical colleges including Pgimer chandigarh, Command Hospital Chandimandir, GMC Patiala, DMC Ludhiana, CMC Ludhiana, The faculty included eminent speakers like Prof. Amod Gupta, Prof. Vishali Gupta, Dr Subina Narang, Dr Reema Bansal, Dr Ravinder Malhi, Dr Rajeev Gupta, Dr Mohit Dogra and Dr Anirudh.

It was an interactive CME with case based discussions. The second CME of this zone was announced by Dr Ravinder in september 2019 at Ludhiana.

*Report Submitted by : Dr. Subina Narang*



# Common Mistakes in Diagnosis and Management

Date: 24/03/2019

Venue: Aravind Eye Hospital – Coimbatore

Aravind Eye Hospital, Coimbatore and Salem in association with Coimbatore Society of Ophthalmic Surgeons, under the aegis of Uveitis Society (India), conducted a CME program on Uveitis – Common Mistakes in Diagnosis and Management on the 24<sup>th</sup> of March 2019. Dr Manohar Babu, CMO & Chief of Uvea Services, AEH, Salem, welcomed the gathering. The external faculty included eminent national faculty and pioneers in the field of uveitis including Dr Jyothirmay Biswas, Head of Uvea services, Sankara Nethralaya, Chennai, Dr. Parthopratiim Dutta Majumder, Consultant, Uvea services, Sankara Nethralaya, Chennai and Dr Padmamalini Mahendradas, HOD of Uveitis and Ocular Immunology, Narayana Nethralaya, Bangalore. Dr Anuradha V K, Head of Uvea, AEH, Coimbatore proposed the vote of thanks. The scientific committee consisted of Dr. Manohar Babu, Dr. Anuradha, Dr. S. Bala Murugan from Aravind Eye Hospital Pondicherry with the guidance and expert guidance of Dr. S. R. Rathinam, Principal of Aravind Eye Hospital, Madurai.

The conference was met with an overwhelming response and had a total of 191 delegates. The theme of the CME as well as the talks were well appreciated by most of the delegates. The sessions were followed by active participation from the audience and elaborate discussions by the faculty. An interactive quiz program conducted by Dr Parthopratiim Dutta Majumder was really an icing on the cake. The program was accredited with 3 credit points from Tamil Nadu Medical Council and 5 from Dr MGR Medical University.

*Report Submitted by : Dr. Anuradha V K*





# Kaun Banega Uveapathy!

## Quiz-Take five!

### Answers

1. Allergan. The anti-allergy nasal drop which they developed was named ALLERGAN® nasal drops and later ALLERGAN® was marketed as the first antihistamine eye drop in the United States.
2. 576 megapixels.
3. The name "Reiter's syndrome", named after the German physician Hans Conrad Julius Reiter. He reported a German Lieutenant with non-gonococcal urethritis, arthritis and uveitis. However, it was not him, who first describe this syndrome. The triad was reported by Feissinger & Leroy, and Sir Benjamin Collins Brodie separately. Reiter was a member of Nazi party and was convicted of forced human experimentation in the Buchenwald concentration camp. During the Second World War, Hans Reiter designed typhus inoculation experiments that killed more than 250 prisoners at concentration camps in Buchenwald. After the war, he was arrested by the Red Army in Soviet Union-occupied Germany and tried at Nuremberg, where he was found guilty and interned at an American prisoner-of-war camp. In 1977, a group of doctors began a campaign for the term "Reiter's Syndrome" to be abandoned and renamed "reactive arthritis".
4. Gray's Anatomy
5. Yes, the `magic' word abracadabra was first used in the 3rd century BC as a cure for malaria. An amulet with the word abracadabra inscribed all over as a triangle was the prescription for malaria patients. It was believed that the word's power would vanquish malaria.

# ACTIVITY REPORT-2019

## CME on Uveitis conducted by USI-2019

8 CMEs were conducted successfully under the aegis of Uvea Society (India) in various two tier cities to spread awareness of uveitis

### CHENNAI



CONDUCTED BY: DR.JYOTIRMAY BISWAS  
FACULTY: DR. NARSING RAO, KALPANA BABU

### CHANDIGARH



Conducted by: Dr.Subina Narang  
Faculty : Prof Amod Gupta, Vishali Gupta,  
Reema Bansal, Aniruddha Agarwal, Mohit Dogra

# COIMBATORE



Conducted by : Dr.Manohar Babu  
Faculty: Dr.Jyotirmay Biswas, Parthopratin Dutta Majumder

# AHEMEDABAD



Conducted by:Dr.Navneet Mehrotra  
Faculty:Reema Bansal & Alay Banker

# CHITRAKOOT



By Dr. Samendra Kharkhur  
Faculty: Prof. Amod Gupta, Dhananjay Shukla, Manisha Agarwal

# KURNOOL



By Dr. Ankush Kawali  
Faculty: Dr. Padmamalini Mahendras, Parthopritam Majumdar


# RAJKOT



Conducted by :Dr.Navneet Mehrotra  
Faculty : Dr. S. Sudarshan

## 1st Working meeting of Joint Research on Uveitis China Japan Korea India Research Group

Uvea Society (India) has become a part of this group to take forward  
both clinical and basic science research in uveitis



## AWARDS AT INTERNATIONAL FORUMS



Achievement Award to Prof. Amod Gupta at 25th Henan Academy of Ophthalmology's annual meeting & 7th International Uveitis Symposium

### **Uvea Society (India) session- a part of the following conferences**

7th International Uveitis Symposium and 1st Chinese-Japanese-Korean-Indian Uveitis Meeting held on 24-25th Aug 2019, Zhengzhou, China.

International Ocular inflammation society -2019,Taiwan.



## Address for Communication

Uveitis Society (India)

C/O Hallmark Events, Maruthi ' 688

1st floor, 6th main,3rd block, BEL layout

Vidyaranyaपुरa, Bangalore - 560097

 080 - 23646880

 9591732274

 [uveitissociety@gmail.com](mailto:uveitissociety@gmail.com)

To register to USICON 2019 - Bengaluru log on to [www.usicon.org](http://www.usicon.org)

[www.indianuveitis.org](http://www.indianuveitis.org)



# The time tested Anti-viral

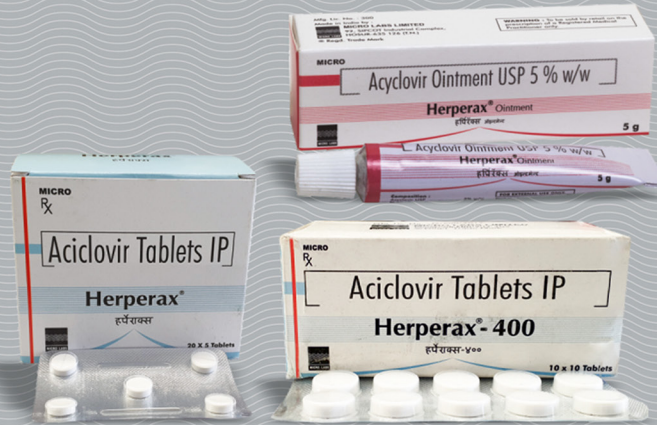

In Viral flare  
Rx The Dependable & Safe Choice

# Herperax®

Aciclovir 200/400/800 mg Tab / 5% Skin Oint

## The Ever Green Antiviral



Leflore S et al, Drug Saf. 2000 Aug;23(2):131-42.



Pregnancy & Lactation are times of high Calcium requirement

# ACUCAL

(Calcium Citrate 950 mg, Magnesium 100 mg, Vitamin D<sub>3</sub> 200 I.U.)

Delivers more calcium to **mother & foetus**

### Calcium Citrate 950 mg

#### Benefits of calcium citrate over calcium carbonate

##### Better Absorption & Bioavailability

- Calcium citrate is **better absorbed** than calcium carbonate<sup>1</sup>
- **2.5 times** more bioavailable than calcium carbonate: Calcium citrate offers **higher transcellular & paracellular absorption** in small intestine thus delivering more calcium to mother & foetus<sup>2,3</sup>

##### Effective at just half the dose as compared to calcium carbonate<sup>4</sup>

- Lesser side effects with Calcium Citrate

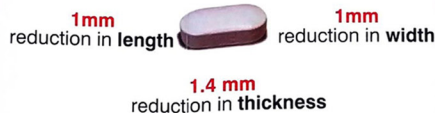##### Better reduction in bone resorption

- Calcium citrate **offers PTH suppression by more than 50%** Vs. calcium carbonate: Ensuring better reduction in bone resorption<sup>2,4</sup>

### Magnesium 100 mg

- Reduces fetal growth retardation<sup>5</sup>
- Reduces risk of pre-eclampsia<sup>5</sup>
- Increases birth weight<sup>5</sup>

#### New Smaller Film Coated Tablet\* Reduction in all 3 dimension of tablet



Easy to swallow  
Maximises patient compliance

### Vitamin D<sub>3</sub> 200 I.U

- Decreases **maternal bone resorption** & leads to enhanced bone mass<sup>6</sup>
- Decreases the risk of recurrent wheeze in early childhood<sup>7</sup>



Once a day



No gastric side effects



Can be taken with or without meals

ACU

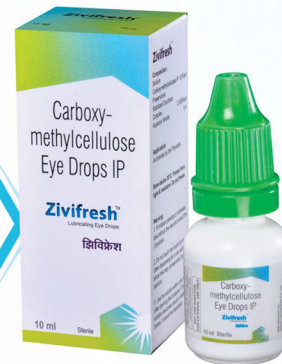1. Sakhae K et al. Am J Ther. 1999 Nov;6(6):312-21  
 2. Heller HJ et al. J Clin Pharmacol. 1999 Nov;39(11):1151-4  
 3. Quesada Gomez JM, et al. Clin Invest. 2011;31(12):285-98  
 4. Thomas SD, et al. Calcif Tissue Int. 2008 Aug;83(2):81-4  
 5. Magnesium Supplementation in pregnancy (review) 2014 The Cochrane Collaboration. Published by John Wiley  
 6. Hallelou B et al. Eur J Obstet Gynecol Reprod Biol. 2011 Sep;158(1):24-7  
 7. Camargo CA Jr et al. Am J Clin Nutr. 2007 Mar;85(3):788-95  
 \* Data on file  
 PTH: Parathyroid hormone

Mild to moderate dry eyes

℞ **Zivifresh**

Sodium Carboxymethyl Cellulose 0.5% w/v

**Relieves Restores Revives**



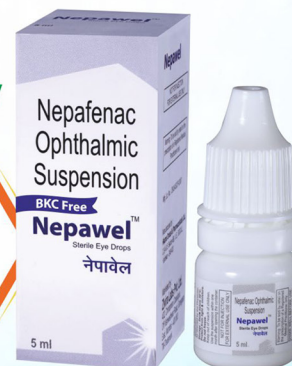In post cataract surgery, CME & DME

℞ **Nepawel**

**BKC Free**

Nepafenac ophthalmic suspension 0.1%w/v

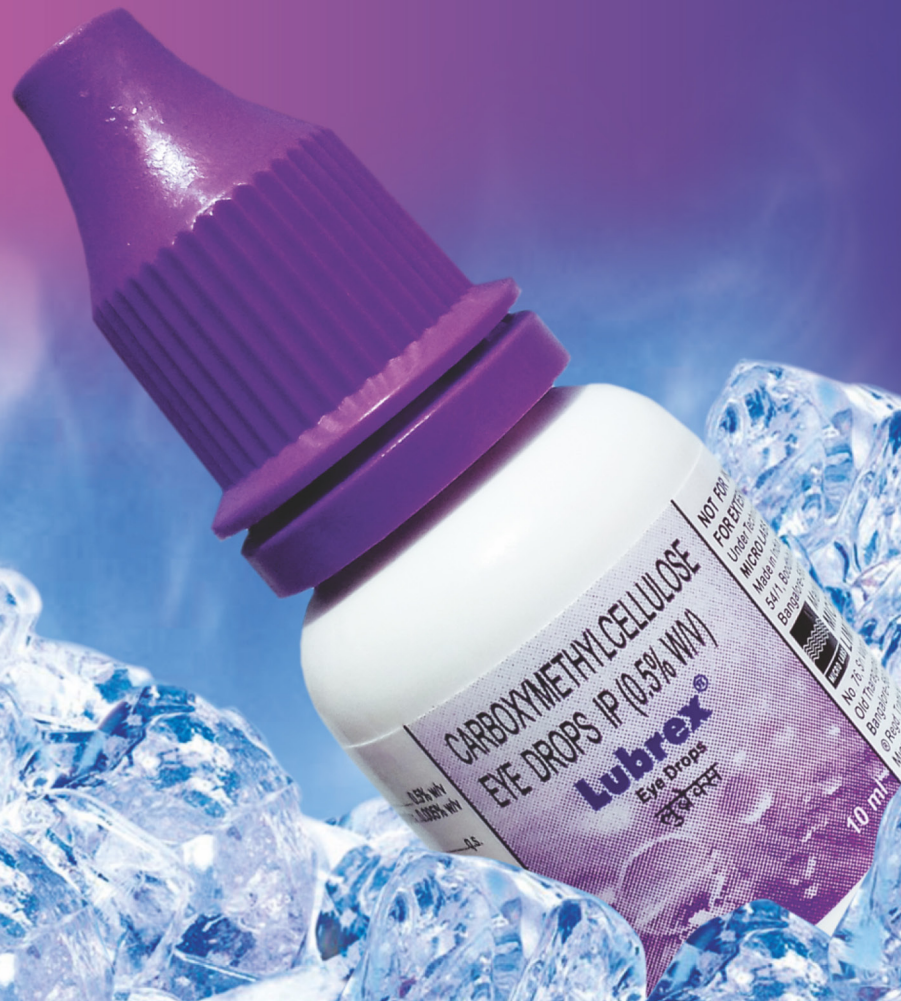Ensured **Wellness**, Ensured **Safety**



# Lubrex

(Sodium Carboxymethylcellulose 0.5%) Eye Drops

Trusted ocular lubricant...  
...for today's over stressed eyes



For the use of Registered Medical Practitioners or a Hospital

