



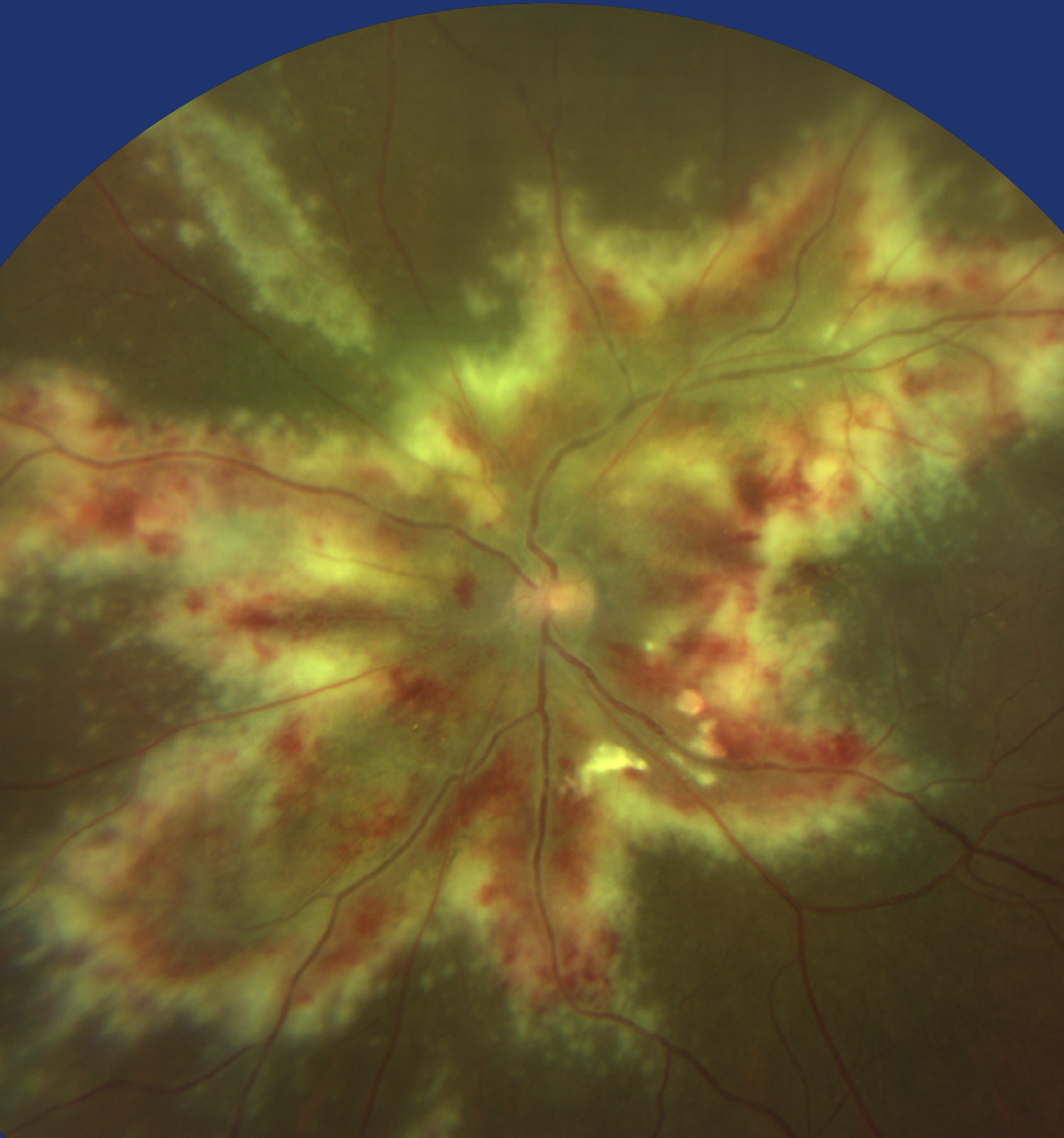
Uveitis Society (India)

EDITION-03

NEWSLETTER

VOLUME - 1 | MARCH 2021

VIRAL UVEITIS





From the Desk of the President



Dear members of US(I),

Once again it is great pleasure for me to be writing this foreword for the upcoming newsletter by our society. The last year has been particularly difficult for all of us. The executive committee of USI with very committed efforts from Dr. Manisha Agarwal, Dr. Kalpana Babu and Dr. S Sudharshan has worked hard to keep our members updated with the latest developments in the field of Uveitis. Dr. Manisha worked extremely hard to organize topic based monthly CMEs in Uveitis and currently uveitis society is co-hosting a complete virtual course on Uveitis that is planned to have 30 monthly webinars by the International Uveitis Study Group that is attended by more than one thousand participants from all over the world.

The Newsletter too is being appreciated by all of you and single person who is leading this difficult project with unmatched hard work and dedication is Dr. S Bala Murugan with his team of experts. It indeed humbles me to write this foreword for the work done by the wonderful team of our young members. For the logistic reasons due to pandemic, we shall have only the soft copy of this newsletter currently. We look forward to your scientific participation for the coming issues of the newsletter and do hope that we are able to see each other this year.

Once again, please take care of yourself and your loved ones and please share your thoughts and suggestions so that we can improve on the newsletter.

Enjoy reading

Dr. Vishali Gupta

MD, Professor Retina

Vitreous and Uvea Advanced Eye Centre

Post Graduate Institute of Medical Education and Research

Chandigarh



From the desk of USI Secretary



Dear All,

Wishing you all a very Happy New Year and hoping that this year brings in a lot of hope, good health and happiness to all of us

Last year was a difficult time for all of us however we all shared our experience and learnt from each other through various virtual meetings and interactions.

We have our third edition of the newsletter dedicated to viral uveitis and hope all of you enjoy and gain knowledge from reading it. I congratulate Dr. Bala, Editor in chief for his selfless effort in putting this together along with his team.

Also I take this opportunity to thank Dr. Vishali Gupta for her constant support and Dr. Jyotirmay Biswas for his all time guidance.

Hoping to meet everyone this year for the annual meeting of our society.

Dr. Manisha Agarwal

Head of Vitreoretina Services

Dr. Shroff's Charity Eye Hospital

New Delhi



Dr. Narsing A Rao
Patron-in-Chief



Dr. Vishali Gupta
President



Dr. Kalpana Babu
Vice President



Dr. Manisha Agarwal
Secretary



Dr. Sudharshan S
Treasurer



Dr. B Manohar Babu
Immediate Past President



Executive Committee Members



Dr. Amala E George



Dr. Shishir Narain



Dr. Padmamalini Mahendradas



Dr. Somasheila Murthy



Advisors



Prof. Carl Herbort



Prof. Amod Gupta



Dr. Jyotirmay Biswas



Dr. S R Rathinam



Dr. Virender S Sangwan



Dr. Sudha K Ganesh



Scientific Committee



Dr. Padmamalini Mahendradas
Scientific Committee
Chairperson



Dr. Reema Bansal
Scientific Committee
Co - Chairperson



Dr. Salil Mehta
Member



Dr. Soumyava Basu
Member



Dr. Parthopratin Dutta Majumder
Member



Dr. S Bala Murugan
Member
Editor-in-Chief



Zonal Representatives



Dr. Subina Narang - North
subina_navya@yahoo.com



Dr. Debashis Das - East
debashisdas@hotmail.com



Dr. Navneet Mehrotra - West
navneetmeh@gmail.com



Dr. Ankush Kawali - South
akawali332@gmail.com



Dr. Samendra Kumar Karkhur - Central
karkhurs@gmail.com



From the Editorial Desk...

Inspiration is a fragrance that transcends limits. We reflexly relish it before we share it to others. It is a great pleasure and privilege to be a part of the newsletter team and bring out the special edition on the felt topic namely “Viral uveitis”. It is a culmination of team work from the stalwarts in the challenging times. It makes me reminisce the reflections of Swami Vivekananda “Whatever good you see is because of my teachers and whatever inadequacies are because of mine alone”, although I am no paragon to him.

Beyond the core subject, it is an eye-opener for me to learn a lot and become better. We shall revigour our aura to make the endeavour of incremental improvement process-driven perpetually with an open-mind. We shall focus our energy on the process and leave the outcome to follow thyselves, yes in cricketing parlance!

We shall reenergize ourselves to do our best in the coming times in our niche areas. This edition is ample proof that when we come together for a common goal and work in synergy, the outcomes are supra additive.

Please feel free to send the bouquets and brickbats to us. We shall thank you with equanimity.

Dr. S Bala Murugan

Consultant

Uveitis services

Aravind Eye Hospital

Puducherry



**Transition in day to day Uveitis practise post COVID-19.
What do the guidelines say ?**

14

Dr. Anjana Somanath, Dr. S Bala Murugan

This article discusses the changes suggested in the treatment protocol of uveitis patients in this covid era. It also quotes various retrospective studies on the risk of acquiring Covid-19 in patients who are immunosuppressed. Various medical societies stand on immunosuppressive medications were analysed.



Delineating Differentials-Post Fever Retinitis

27

Dr. Padmamalini Mahendradas, Dr. Sai Bhakti Mishra

Dr. Ankush Kawali, Dr. Namita Dave, Dr. Sanjay Srinivasan

This paper has tabulated the systemic and ocular symptoms, clinical signs ocular imaging, serological investigations and treatment protocol of various post febrile retinitis Differentials.



Current Concepts in Viral Uveitis: Expert Panel Discussion

39

Dr. Reema Bansal, Dr. Sudharshan S, Dr. Kalpana Babu

This discussion answers various queries that may arise from diagnosis to management of viral uveitis and its complications. The clinical nuances from the experts helps to solve various unanswered queries in the past.



Crossword on Viral Retinitis

50

Dr. Srinivasan Sanjay, Dr. Ankush Kawali, Dr. Padmamalini M

Exercise your vocabulary and knowledge on viral uveitis



Kaun Banega UVEAPATI (Quiz)

55

Dr. Gazal Patnaik, Dr. Amitabh Kumar, Dr. Jyotirmay Biswas

Test your knowledge and judgment on 10 challenging cases.



Study of studies in viral uveitis

61

Dr. Vinaya Kumar Konana, Dr. Kalpana Babu

A study enlisting original and review articles published in the five years on pathophysiology, clinical features, complications, diagnostics and treatment of viral uveitis. It also in short gives as a gist of each article.



Antivirals In Ophthalmology: A Quick Look

94

Dr. Parthoprattim Dutta Majumder

A short but complete list of antiviral medications and their mode of action pharmacokinetics, anti viral profile and its side effects.



Viral AU case report Viral Anterior Uveitis and More!

103

Dr. Sahana Mazumdar

A case report on Hypertensive viral uveitis with difficulties faced in diagnosing the etiology .



What is new in Viral Uveitis?

108

Dr. Sudha K Ganesh, Dr. Sharanya Abraham, Dr. Nivedita Nair

A tabulated compilation of articles on viral uveitis from last 5 years under the headings Clinical diagnosis, Laboratory diagnosis, ocular imaging, management, and Emerging viral uveitis.

**Paracentral Acute Middle Maculopathy Associated with Viral Retinitis and Amaurosis Fugax** **147**

Dr. Eliza Anthony

An article on Paracentral Acute Middle Maculopathy Associated with Viral Retinitis and Amaurosis Fugax.

**Clinical pearls in ARN diagnosis and management** **153**

Dr. Shishir Narain, Dr. Manisha Agarwal

Article on Acute retinal Necrosis Diagnosis and management with case examples.

**Does response to treatment clinch the diagnosis in viral uveitis?** **162**

Dr. Mudit Tyagi, Dr. Hrishikesh Kaza, Dr. Soumyava Basu

This article explains with case reports how response to treatment trial helps in cluing down the diagnosing while in dilemma

**Atypical Viral Uveitis** **171**

Dr. Radhika T, Dr. Rathinam S R

This article covers multiple atypical presentations possible in cases of viral uveitis in detail.

**Photo Competition** **184**

Photogenic presentation of key clinical signs in various viral uveitis in the anterior and posterior segment are impressive.



**Survey from Uveitis Society (India)
What change COVID-19 made in your real-time practice? 191**

A survey and multiple response on clinical practise during covid pandemic



Crossword Answers for USI news letter on Viral retinitis 199

Dr. Srinivasan Sanjay, Dr. Ankush Kawali, Dr. Padmamalini M



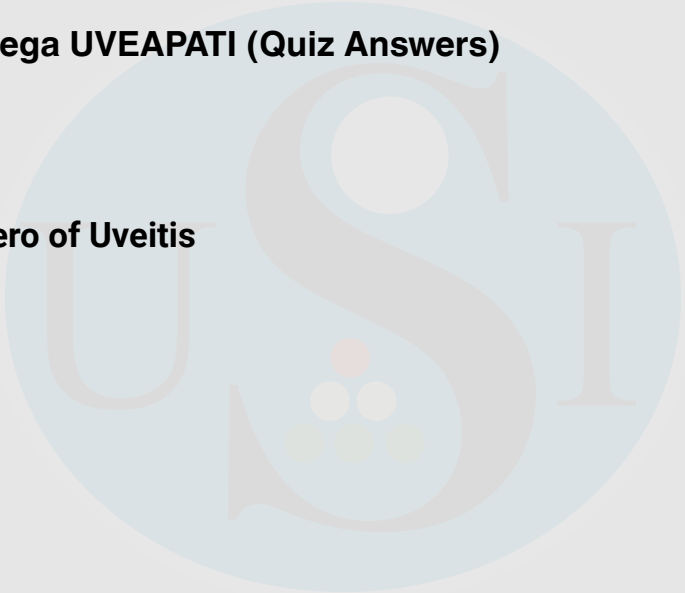
Kaun Banega UVEAPATI (Quiz Answers) 200



Unsung Hero of Uveitis 208



Awards 209





Transition in day to day Uveitis practise post COVID-19. What do the guidelines say ?



Dr. Anjana Somanath

Aravind Eye Care System, Madurai.

Email: anjana471306@gmail.com



Dr. S Bala Murugan

Aravind Eye Care System, Pondicherry

Email: drbalamuruganms@gmail.com

Transition in day to day Uveitis practise post COVID-19.

What do the guidelines say?

The corona virus disease -19(COVID-19) is an ongoing pandemic caused by the severe acute respiratory syndrome corona virus 2 (SARS-COV-2). The disease first emerged in December 2019 in Wuhan which is the capital of Hubei province in central China. The World Health Organisation in March 2020 recognised a surge in the number of cases in various countries. Hence COVID-19 was recognised as a pandemic. As of 6th November 2020, more than 49.1 million cases have been confirmed, with more than 1.23 million deaths attributed to COVID-19^[1].

COVID-19 is a new disease. The clinical course of COVID-19 can be divided into three phases. It includes the viremia phase, the acute phase/pneumonia phase and the severe /recovery phase. In majority of the patients with COVID-19 they have mild symptoms. However in 19 % of the individuals the disease may progress to severe COVID-19 with a high mortality rate.^[2]

Corona virus is an enveloped single stranded RNA virus which can infect many animal species including humans. However prior to the COVID-19 pandemic, Severe Acute Respiratory Syndrome(SARS) and the Middle East Respiratory Syndrome(MERS) outbreak also caused by the corona virus has been identified.^[3] Due to the early identification of the disease, the spread of the disease was contained. Currently limited data is available regarding the outcome of COVID-19.

Risk factors associated with COVID-19

Age more than 50 years Obesity	Diabetes mellitus Coronary heart diseases Respiratory diseases Infections
Pharmacologically immunosuppressed patients HIV patients with CD4 count < 200 cell/mm ³	Health care professionals

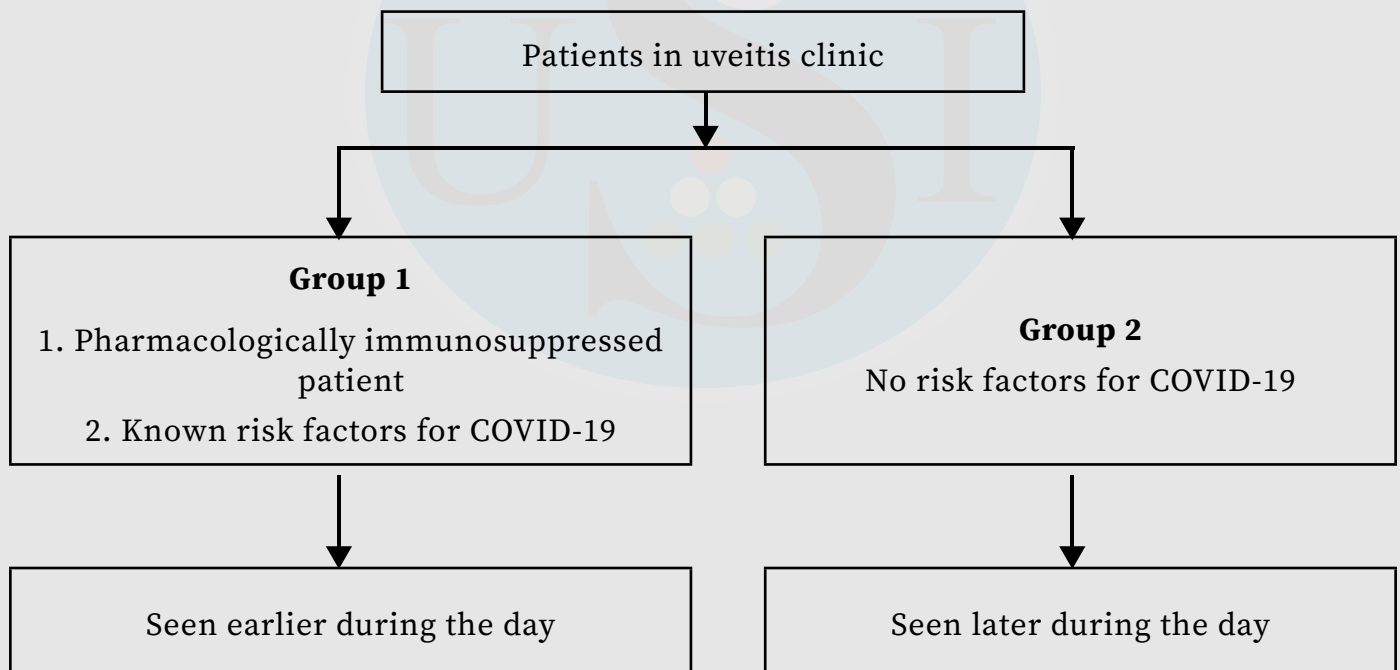
Ophthalmologist, rheumatologist and medical professionals from other disciplines treat patients with immunosuppressive medications^[4,5]. These patients who are pharmacologically immunosuppressed due to ocular inflammation, organ transplantation and autoimmune disease may be vulnerable to COVID-19. Continuing these immunosuppressive drugs during this pandemic may be putting the patient at risk.

Protecting pharmacologically immunosuppressed uveitis patients from coronavirus:

To prevent cross infection during COVID-19 pandemic, recommendations and strategies are advised by the World Health Organisation (WHO) and Centers for Disease Control and Prevention (CDC)^[6,7]. These recommendations and strategies should be followed by all healthcare professionals irrespective of the COVID-19 status of the patient.^[8] The recommendations are as follows:

1. Limiting exposure to patients: Before the patients are to be examined, a history of fever, exposure to COVID-19 infected person, a recent history of travel or a history of attending a social gathering should be noted by a triage personnel. Use of face mask, cough etiquette and use of alcohol-based hand rub should be instructed for all patients. Patients for follow up or for non-emergency procedures should be rescheduled to prevent overcrowding in the clinic area.

In the clinic if mixed category of patients are seen, preferably patients with high risk should be seen earlier in the day. In the waiting area, patients are advised to maintain distance of two meters from each other. Minimum number of patients should be in the waiting room at a given time. Accompanying person are advised to wait outside the examination room and to return after the examination is complete.



2. Adhere to the transmission based precautions: Irrespective of COVID-19 status of patients, standard hand washing precautions should be followed. Use of 60-90 % ethanol based or isopropyl alcohol should be used if soap and water is not available. Else sterile disposable gloves can be used and disposed appropriately. Face masks N95 should be used by all health professional. They should later be disposed as advised by the manufacturer.

3. To take precautions while performing non-invasive and contact procedures:

As COVID-19 spreads through aerosol contact, instruments such as air puff tonometer and ocular response analyser should be avoided. These instruments cause high speed air directed towards the cornea causing microaerosol production. Hence these procedures should be avoided. A slit lamp barrier should be installed and the chin rest paper should be changed after every patient. During contact procedures such as applanation tonometer, pachymeter and B scan, the probe should be disinfected. Other procedures such as conjunctival swab, aqueous and vitreous aspirate should be performed by using all precautions.

1. Hospital environment: To reduce the spread of infection in hospital environment, all contact areas should be regularly disinfected. Alcohol based products such as isopropyl alcohol or ethanol based solutions can effectively disinfect the contact surfaces.

Frequent cleaning of contact surfaces with hospital based solutions such as EPA (Environment Protection Agency) registered hospital based disinfectants for SARS-CoV-2 can be used as per manufactures recommendation to reduce transmission.^[9] High efficiency particulate (HEPA) air filters is another way of replacing air in the hospital environment. Non-emergency surgeries can be postponed or can be performed on an appointment basis.

Preventing cross infection in uveitis patients during COVID-19:

- Use face mask
- Follow standard hand washing procedures
- Use 60-90 % ethanol based hand rub solutions
- Disinfect contact surfaces
- Non emergency procedure to be done on appointment basis
- To follow adequate precautions while performing non-invasive contact procedures
- To use air filters
- Cough etiquette
- Avoid travelling
- Avoid social gathering

Monitoring pharmacological immunosuppressed uveitis patients :

The first line of defence in any immunity is innate immunity. If the patients total count is kept above 4000 cells per cubic mm, the risk of infection is reduced.^[10] Now to handle a situation where the patients are pharmacologically immunosuppressed during this COVID-19 pandemic becomes an important consideration.

The pharmacologically immunosuppressed patients are primed to monitor blood counts regularly to assess the immunity of the individual. However we should reiterate the importance of this again to these patients. The patients are advised to monitor the blood counts close to home to prevent exposure and travel. Even if the patients are well informed

about how to protect themselves from infection, you or your staff need to regularly contact patients on immunosuppressive medications. Patients on immunosuppressive medications need to be reassured about the safety during this COVID-19 pandemic as many patients discontinue the medications without medical advise.

a. Contact with COVID-19 patient or without signs of COVID-19 in an immunosuppressed uveitis patient: Immunosuppressed patient with uveitis, in case of contact with COVID-19 patient, are advised to consult physicians for confirmation of diagnosis. In an uveitis patient without symptoms of COVID-19, they are advised to continue their immunosuppressive medications after confirmation of diagnosis.

b. Immunosuppressed uveitis patients with signs of COVID-19: In a uveitis patient with symptoms of COVID-19, they are advised to discontinue their immunosuppressive or biologic medications. If needed, local treatment options can be considered. They are advised to restart their medications after they have recovered from the illness. Low maintenance doses <10mg/day of prednisolone may not pose significant risk, and should be maintained if necessary for the uveitis. In patients with severe uveitis, where high doses of systemic steroids such as i.v methylprednisolone are required, local therapy or combined with low dose systemic steroids may be considered. ^[11] However, the use of systemic corticosteroids in uveitis patients may need a slow reduction. This should be discussed with the COVID treatment team.

Guidelines for continuing steroids in COVID-19 patients:

Proinflammatory cytokines play an important role in the pathogenesis of COVID-19. Corticosteroids are known to modulate the inflammatory response. They also appeared to be effective in reducing immunopathological damage. Therefore the Chinese guidelines recommended the use of corticosteroids in the treatment of COVID-19.^[11]

But there are concerns centred around on viral rebound and association with adverse events when patients are treated with corticosteroids.

The World Health Organisation does not recommend the use of corticosteroids in patients with COVID-19 due to prolonged virus shedding. It was found that the viral clearance was delayed in patients receiving high to moderate dose corticosteroids. Low-dose corticosteroids can be used, as there was no influence on viral clearance.^[11]

A randomised controlled trial which measured viral load at regular intervals in non-intubated SARS-CoV-2 cases found higher concentrations of viral RNA in the second and the third week of infection in those treated with corticosteroids compared to placebo ^[12]. Also, a laboratory study which treated porcine respiratory coronavirus infected pigs with dexamethasone suggested that one or two doses of the corticosteroid in the acute phase of infection may effectively alleviate early pro-inflammatory response, but prolonged administration may play a role in enhancing viral replication.^[13]

However, a Chinese study, which divided SARS-CoV-2 patients into four treatment groups, identified early high dose steroids in combination with a quinolone produced the most favourable patient outcomes^[14].

The current literature does not give evidence for or against the use of NSAIDs in the treatment of COVID-19 patients, though there appears to be some evidence that corticosteroids may be beneficial in the treatment of SARS-CoV-2. ^[15,16]

Thus during this unprecedented times, caution should be exercised by the medical community until further evidence specific to the infection strain develops.

What do we know about immunosuppression and COVID-19:

Case reports and observational studies on COVID-19 and immunosuppression are from hotspot centers such as China and Europe. These reports are on immunosuppression in transplant recipients and those on systemic autoimmune disease.

Retrospective studies on immunosuppression and COVID-19		
	Author	Outcome
1.	Li <i>et al.</i>	Reported 2 cases of COVID-19 among 200 heart transplant recipients immunosuppressed with tacrolimus and mycophenolate mofetil. Both these patients had clinical presentation, laboratory findings and CT findings similar to the non-immunosuppressed patients. ^[17]
2.	D' Antiga	Reported three cases of SARS-CoV-2 infection with none progressing to pneumonia among over 300 paediatric patients with liver transplants or autoimmune liver disease. No change in immunosuppression regimen was mandated in this centre. ^[18]
3.	Bhoori <i>et al.</i>	111 long-term adult liver transplant patients on minimal immunosuppression with three COVID-19 fatalities and compared them to three uneventful SARS-CoV-2 infections in 40 recently transplanted and fully immunosuppressed patients at his centre. ^[19] The deaths recorded appeared to be related more to the known risk factors of severe COVID-19 disease (age, presence of several concomitant comorbidities) rather than the degree of immunosuppression and that immunotherapy might have been protective against severe disease.

4.	Norsa <i>et al.</i>	522 patients with inflammatory bowel disease (IBD) with 22% on oral immunosuppression such as corticosteroids and antimetabolites and 16% on biologics. ^[20] During the study duration, a separate 479 non-IBD patients were admitted to his hospital for severe COVID-19 pneumonia. There were no reports of SARS-CoV-2 infection in the patients with IBD.
5.	Mao <i>et al.</i>	Reported no cases of SARS-CoV-2 infection in over 20,000 patients with IBD from the seven largest IBD centres in China. ^[21]
6.	Jose.L <i>et al.</i>	Reported that severe COVID-19 occurred in 31.6% of the rheumatic and 28.1% of non-rheumatic cohorts. Having a connective tissue disease but not its therapy was significantly associated with severe COVID-19. ^[22]

Looking at the various retrospective studies on patients with COVID-19, there is little evidence that immunosuppression is a significant risk factor for COVID-19. There are similarities between the risk factors of the current pandemic with that of severe acute respiratory syndrome (SARS) and middle east respiratory syndrome (MERS). During the SARS and MERS outbreak, the mortality and morbidity in immunosuppressed patients did not differ from the general population. Also, there was no report of higher incidence of SARS and MERS in immunosuppressed patients.^[23]

Early data is available which suggests the role of high dose oral steroids and immunosuppressants in COVID-19 patients. Hence large scale prospective epidemiological studies are required to determine the exact cause of risk in severe COVID-19 disease in immunosuppressed patients.

Hydroxychloroquine in uveitis patients and health care professionals during COVID-19 pandemic :

Patients in the uvea clinic with uveitis due to autoimmune diseases such as rheumatoid arthritis and systemic lupus erythematosus are treated with chloroquine or hydroxychloroquine under rheumatologist care. It has been hypothesised that chloroquine interferes with Angiotensin Converting Enzyme (ACE)-2 receptor glycosylation thus preventing SARS-CoV-2 binding to target cells. Thus chloroquine has been shown to be capable of inhibiting the in vitro replication of several coronaviruses. Recent publications support the hypothesis that chloroquine can improve the clinical outcome of patients infected by severe acute respiratory syndrome coronavirus-2 (SARS-CoV-2) ^[24].

Though the existing evidence is thin, whether chloroquine will be beneficial in patients who are on these medications for autoimmune disease is not known. The Lupus foundation of America has requested hydroxychloroquine manufactures to increase their supply, so that systemis lupus erythematosus (SLE) patient on hydroxychloroquine will continue to have access it. [25]

In India, there has been steadfast in its recommendation of the prophylactic use of hydroxychloroquine since March. On 22 May, the advice was extended to all frontline workers and not just health workers. Hydroxychloroquine (HCQ) use was mandated for all asymptomatic frontline workers, such as surveillance workers deployed in containment zones and paramilitary/police personnel involved in Covid-19 related activities. Three studies were taken into account by the Indian Council of Medical Research's (ICMR) Covid-19 task force to make these recommendations. In a retrospective study, ICMR found a significant dose-response relationship between the number of prophylactic doses taken and frequency of occurrence of SARS-CoV-2 infection in symptomatic healthcare workers who were tested for SARS-CoV-2 infection. Another investigation from three central government hospitals in New Delhi found that healthcare workers on HCQ prophylaxis were less likely to develop SARS-CoV-2 infection. The third was an observational prospective study of 334 healthcare workers at AIIMS out of which 248 took HCQ prophylaxis (median 6 weeks of follow up) in New Delhi. That also showed that those taking HCQ prophylaxis had lower incidence of SARS-CoV-2 infection. [26]

Guidelines from various societies regarding immunosuppressive drugs in the COVID-19 pandemic: As mentioned earlier immunosuppressive have a role in modulating the host inflammatory response seen in severe COVID-19 infection. But ceasing immunosuppressive medications can cause the underlying condition to flare up. Thus various medical societies in Europe and in United States of America have decided to continue the patients on their existing immunosuppressive medications.

a. The British Society of Rheumatology: The British Society of Rheumatology (BSR) has developed a risk guide and scoring grid to address the management of immunosuppression during this pandemic. [27] This recommendation is for all patients who are healthy and on immunosuppressive medication. They advised to continue appropriate social distancing and from infection prevention strategies. Those who are on ≥ 20 mg/day of oral prednisone or its equivalent, alkylating agents or two or more drugs (one of which is a corticosteroid) fall into the highest risk category and are recommended to be shielded. Patients on ≥ 5 mg/day but < 20 mg/day of oral prednisone or its equivalent, two or more non-corticosteroid drugs fall into the moderate risk category and recommended to atleast practice social distancing. Lastly, patients on single non-corticosteroid drugs are of the lowest risk similar to patients with comorbidities like diabetes.

b. The National Health System: Special emphasis has been placed on corticosteroids by the National Health System of England (NHS) as well because of the disappointing experience with corticosteroids in the treatment of SARS and MERS.^[28] The NHS guidelines have recommended physicians to exercise caution in starting patients with corticosteroids during the pandemic. They suggest to prescribe the lowest possible dose and taper corticosteroid therapy as fast as possible.

c. The British Gastroenterological Association: The recent reports and opinion by the British Gastroenterological Association, have also reported no evidence of increased risk of infection and severity of COVID-19 disease in patients with inflammatory bowel disease.^[29]

d. American Academy of Dermatology: The American Academy of Dermatology have opined on continuing the use of biological agents during this pandemic.^[30] With no data on the specific risk of COVID-19 infection with biological therapy, their priority is to keep patients out of emergency units so as not to tax the healthcare system unnecessarily. They propose all asymptomatic patients to continue biologics. They recommend in deferring initiation of biological therapy in those with known COVID-19 risk factors and to discontinue biologic therapy in patients who are infected.

e. International Uveitis Study Group: The International Uveitis Study Group jointly with the International Ocular Inflammation Society and the Foster Ocular Inflammation Society has similarly indicated the need to continue immunosuppression in patients without clinical signs of COVID-19 or confirmation of disease.^[31] Social distancing should be practiced as much as possible. Stable patients can be followed up follow-up through telemedicine. Patients with active uveitis should be seen in the clinic for appropriate adjustment in therapy. Tapering corticosteroids as quickly as possible should be attempted in all cases. In symptomatic patients, a confirmation of the diagnosis should be requested as the patient is considered in the high risk group. Corticosteroids dose should be tapered to under 20 mg/day of oral prednisone or equivalent. If corticosteroids are required to treat uveitis or a flare-up, local intraocular therapy (if required, bilateral) should be considered as it should provides adequate treatment. For patients on biologic agents, the medication should be discontinued until there are clear signs of recovery. For other systemic immunosuppression, the dosage should remain intact, but monitored in case of progression to a higher level of COVID-19 severity.

The study on the impact of COVID-19 pandemic on uveitis patients receiving immunomodulatory and biological therapies(COPE) have concluded that during this on going pandemic uvieitis specialist tend to to reduce the ongoing immunosuppressive medications or prefer to opt for a less aggressive treatment.They should be aware that such alteration in medications may cause an aggrevation in uveitis.^[32]

New recommendations are likely to evolve as more information will be available for the relationship between induced immunosuppression and COVID-19 disease.

Laboratory markers for COVID-19 :

Biomarkers are needed to identify patients who will progress to severe COVID-19. Current clinical practice suggests determining Interleukin-6, D-dimer, lactate dehydrogenase (LDH), and transaminases in addition to routine laboratory tests, in order to identify patients at risk of fatal complications.^[33] However some biochemical markers such as the lymphocyte counts, erythrocyte sedimentation rate and the C-reactive protein are affected by the immunosuppressive medication. Hence they are not reliable when the patient is on the immunosuppressive drug.

The outbreak of COVID-19 has become a major health concern internationally. This new disease has major impact on the management of patients not only on immunosuppressive medications but also those who need to be started on immunosuppressive medications to control their disease activity. Infact significant research work is required to clarify the impact of steroids, immunosuppressive medications on COVID-19. Till date logical thinking has guided us in treating patients with known diseases. At the moment specific screening of tuberculosis and hepatitis is done before starting the patient on immunosuppressive or biologic. So in future should we screen patients for COVID-19 or biologic remains unanswered. More evidence should be gathered and laboratory investigations should be identified to identify the patients at risk of developing COVID-19.

References:

1. Ensheng Dong, Hongru Du, Lauren Gardner. An interactive web-based dashboard to track COVID-19 in real time. *The Lancet infectious diseases*. February 19, 2020. doi: [https://doi.org/10.1016/S1473-3099\(20\)30120-1](https://doi.org/10.1016/S1473-3099(20)30120-1).
2. Wu Z, McGoogan JM. Characteristics of and Important Lessons From the Coronavirus Disease 2019 (COVID-19) Outbreak in China: Summary of a Report of 72,314 Cases From the Chinese Center for Disease Control and Prevention. *JAMA*. 2020 Apr 7;323(13):1239-1242.
3. Hu T, Liu Y, Zhao M, Zhuang Q, Xu L, He Q. A comparison of COVID-19, SARS and MERS. *PeerJ*:8e9725. 2020. doi: <https://doi.org/10.7717/peerj.9725>. <https://peerj.com/articles/9725>.
4. Yang J, Zheng Y, Gou X, Pu K, Chen Z, Guo Q, *et al*. Prevalence of comorbidities in the novel Wuhan coronavirus (COVID-19) infection: a systematic review and meta-analysis. *Int J Infect Dis*. 2020
5. Dandachi D, Geiger G, Montgomery MW, Karmen Tuohy S, Golzy M, Antar AAR *et al*. HIV COVID-19 consortium. Characteristics, Comorbidities, and Outcomes in a Multicenter Registry of Patients with HIV and Coronavirus Disease-19. *Clin Infect Dis*. 2020 Sep 9. doi: 10.1093/cid/ciaa1339. <https://pubmed.ncbi.nlm.nih.gov/32905581>

6. World Health Organization. Novel Coronavirus (2019-nCoV). Available from : https://www.who.int/docs/default-source/coronaviruse/situation-reports/20200126-sitrep-6-2019--ncov.pdf?sfvrsn=beae0c_4
7. Centers for Disease Control and Prevention. Interim Infection Prevention and Control Recommendations for Healthcare Personnel During the Coronavirus Disease 2019 (COVID-19) Pandemic. Available from : <https://www.cdc.gov/coronavirus/2019-nCoV/hcp/infection-control>.
8. Ferguson NM, Laydon D, Nedjati Gilani G, Imperial College COVID-19 Response Team. Impact of non-pharmaceutical interventions (NPIs) to reduce COVID-19 mortality and healthcare demand. Imperial College; 2020. Available from: <https://www.imperial.ac.uk/media/imperial-college/medicine/sph/ide/gida-fellowships/Imperial-College-COVID19-NPI-modelling-16-03-2020.pdf>.
9. Kampf G, Todt D, Pfaender S, Steinmann E. Persistence of coronaviruses on inanimate surfaces and their inactivation with biocidal agents. *J Hosp Infect.* 2020;104(3):246-51.
10. Chen, Yanfei, and Lanjuan Li. *Clinical infectious diseases : an official publication of the Infectious Diseases Society of America*, c1aa832. 26 Jun. 2020. doi: <https://doi.org/10.1093/cid/c1aa832>.
11. Russell B, Moss C, George G, Santaolalla A, Cope A, Papa S, Van Hemelrijck M. Associations between immune-suppressive and stimulating drugs and novel COVID-19-a systematic review of current evidence. *Ecancermedalscience.* 2020 ;14:1022.
12. Lee N, Allen Chan KC, Hui DS, Enders K O Ng, Alan Wu *et al.* Effects of early corticosteroid treatment on plasma SARS-associated Coronavirus RNA concentrations in adult patients. *J Clin Virol.* 2004;31(4):304-309.
13. Zhang X, Alekseev K, Jung K, Vlasova A, Hadya N, Saif LJ. Cytokine responses in porcine respiratory coronavirus-infected pigs treated with corticosteroids as a model for severe acute respiratory syndrome. *J Virol.* 2008;82(9):4420-8.
14. Zhao Z, Zhang F, Xu M, Zhong, W Cai, W Yin *et al.* Description and clinical treatment of an early outbreak of severe acute respiratory syndrome (SARS) in Guangzhou, PR China. *J Med Microbiol.* 2003;52(Pt 8):715-720.
15. Thng ZX, De Smet MD, Lee CS, Vishali Gupta, Justine R Smith, Peter J McCluskey *et al.* COVID-19 and immunosuppression: a review of current clinical experiences and implications for ophthalmology patients taking immunosuppressive drugs. *Br J Ophthalmol.* 2021;105:306-310.
16. Russell B, Moss C, Rigg A, Van Hemelrijck M. COVID-19 and treatment with NSAIDs and corticosteroids: should we be limiting their use in the clinical setting? *Ecancermedalscience.* 2020;14:1023.
17. Li F, Cai J, Dong N. First cases of COVID-19 in heart transplantation from China. *J Heart Lung Transplant.* 2020;39(5).

18. D'Antiga L. Coronaviruses and Immunosuppressed Patients: The Facts During the Third Epidemic. *Liver Transpl.* 2020;26(6):832-834.
19. Bhoori S, Rossi RE, Citterio D, Mazzaferro V. COVID-19 in long-term liver transplant patients: preliminary experience from an Italian transplant centre in Lombardy. *Lancet Gastroenterol Hepatol.* 2020;5(6):532-533.
20. Norsa L, Indriolo A, Sansotta N, Cosimo P, Greco S, D'Antiga L. Uneventful Course in Patients With Inflammatory Bowel Disease During the Severe Acute Respiratory Syndrome Coronavirus 2 Outbreak in Northern Italy. *Gastroenterology.* 2020 ;159(1):371-372.
21. Mao R, Liang J, Shen J, Ghosh S, Zhu LR, Yang H, Wu KC, Chen MH; Chinese Society of IBD, Chinese Elite IBD Union; Chinese IBD Quality Care Evaluation Center Committee. Implications of COVID-19 for patients with pre-existing digestive diseases. *Lancet Gastroenterol Hepatol.* 2020 May;5(5):425-427.
22. Pablos JL, Galindo M, Carmona L, Ana Lledó, Miriam Retuerto, Ricardo Blanco *et al.* Clinical outcomes of hospitalised patients with COVID-19 and chronic inflammatory and autoimmune rheumatic diseases: a multicentric matched cohort study. *Annals of the Rheumatic Diseases* 2020;79:1544-1549.
23. Thng ZX, De Smet MD, Lee CS, Gupta V, Smith JR, McCluskey PJ *et al.* COVID-19 and immunosuppression: A review of current clinical experiences and implications for ophthalmology patients taking immunosuppressive drugs. *Br J Ophthalmol.* 2020. [bjophthalmol-2020-316586](https://doi.org/10.1136/bjophthalmol-2020-316586).
24. Gao J, Tian Z, Yang X. Breakthrough: Chloroquine phosphate has shown apparent efficacy in treatment of COVID-19 associated pneumonia in clinical studies. *Biosci Trends.* 2020;14(1):72-73.
25. Lupus Foundation of America. Coronavirus(COVID-19) and lupus. Available from :<https://www.lupus.org/resources/coronavirus-and-lupus>.
26. Revised advisory on the use of Hydroxychloroquine(HCQ) as prophylaxis for COVID-19 infection. Available from :https://www.icmr.gov.in/pdf/covid/techdoc/V5_Revised_advisory_on_the_use_of_HCQ_SARS_CoV2_infection.pdf.
27. British Society for Rheumatology. COVID-19: guidance for rheumatologists. Available from : <https://www.rheumatology.org.uk/practice-quality/covid-19-guidance>.
28. National Health System England. Clinical guide for the management of patients with musculoskeletal and rheumatic conditions on corticosteroids during the coronavirus pandemic, 2020. Available from : <https://www.csp.org.uk/documents/nhs-england-clinical-guide-management-patients-musculoskeletal-rheumatic-conditions>.
29. Kennedy NA, Jones G, Lamb CA, *et al.* British Society of Gastroenterology guidance for management of inflammatory bowel disease during the COVID-19 pandemic. *oGut* 2020;69:984-990.

30. American Academy of Dermatology. Guidance on the use of biologic agents during COVID-19 outbreak. Available from <https://www.aad.org/member/practice/coronavirus/clinical-guidance/biologics>.
31. Manfred Zierhut, Marc D. De Smet, Vishali Gupta, Carlos Pavesio, Quan Dong Nguyen, Soon-Phaik Chee *et al.* Evolving Consensus Experience of the IUSG-IOIS-FOIS with Uveitis in the Time of COVID-19 Infection. *Ocular Immunology and Inflammation*. 2020; 28:5, 709-713.
32. Agarwal AK, Sudharshan S, Mahendradas P, Babu K, Shenoy P, Dogra M *et al.* Impact of COVID-19 pandemic on uveitis patients receiving immunomodulatory and biological therapies (COPE STUDY). *Br J Ophthalmol*. 2020 Oct 3:bjophthalmol-2020-317417.
33. Velavan TP, Meyer CG. Mild versus severe COVID-19: Laboratory markers. *Int J Infect Dis*. 2020 June;95:304-307.





Post Fever Retinitis - Differentials

Dr. Padmamalini Mahendradas



Dr. Sai Bhakti Mishra



Dr. Ankush Kawali



Dr. Namita Dave



Dr. Sanjay Srinivasan



Authors:

Department of Uveitis and Ocular Immunology, Narayana Nethralaya, Bangalore

Corresponding Author:

Dr. Padmamalini Mahendradas

Email: m.padmamalini@gmail.com

Head, Department of Uveitis and

Ocular Immunology

Narayana Nethralaya, Bangalore.



Post Fever Retinitis - Differentials

Post-fever retinitis (PFR) is a uveoretinal sequelae which could be infectious or para-infectious in nature caused by bacterial or viral agents and is seen mainly in tropical countries. Systemic symptoms commonly associated during the febrile stage include joint pain, and skin rash. Diagnosing the etiological agent when a patient presents with PFR is difficult based on only clinical evaluation and ocular imaging. Laboratory investigations including blood counts, serological investigations and molecular diagnostic tests along with the knowledge of concurrent epidemics in the community can help to identify the causative organism.

List of abbreviations:

- BRVO branch retinal vein occlusion
- FFA fundus fluorescein angiography
- OCT optical coherence tomography
- SRF subretinal fluid
- ELISA enzyme linked immunosorbent assay
- NSAID nonsteroidal anti-inflammatory drugs
- PPV pars plana vitrectomy
- VH vitreous haemorrhage
- ICGA indocyanine green angiography
- OCTA optical coherence tomography angiography
- RPE retinal pigment epithelium
- ONL outer nuclear layer
- OPL outer plexiform layer
- AMN acute macular neuroretinopathy
- PAMM paracentral acute middle maculopathy
- PCR polymerase chain reaction
- FAF fundus autofluorescence
- VEGF vascular endothelial growth factor
- CNVM choroidal neovascular membrane
- DCP deep capillary plexus
- SCP superficial capillary plexus
- SARS-CoV-2 severe acute respiratory syndrome 2
- COVID-19 coronavirus disease of 2019

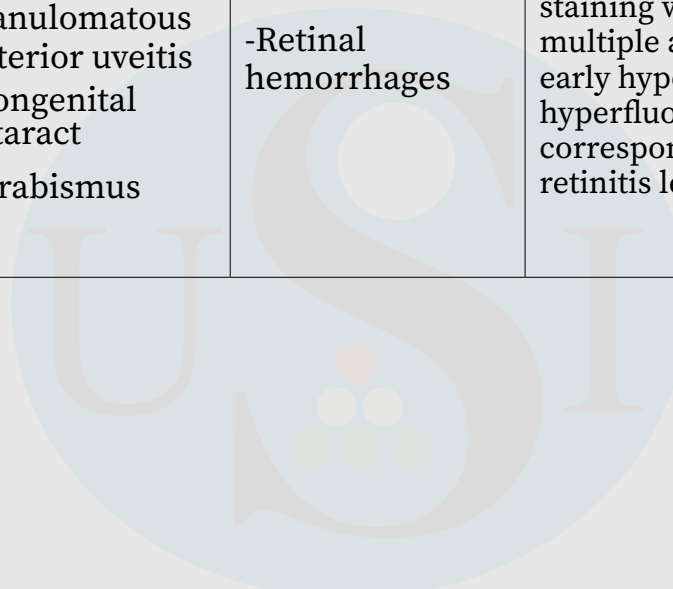
Systemic disease	Systemic history and symptoms	Ocular symptoms	External and anterior involvement	Fundus features	Ocular imaging	Laboratory diagnosis	Treatment
Rickettsial disease	<ul style="list-style-type: none"> -Fever -Myalgia -Headache -Maculo-papular rash -Tachypoea -History of forest visit or exposure to animals 	<ul style="list-style-type: none"> -Decreased vision following febrile illness -Floaters 	<ul style="list-style-type: none"> -Circumcorneal congestion -Subconjunctival hemorrhage 	<ul style="list-style-type: none"> -Vitritis upto grade 2 -Focal or multifocal retinitis at posterior pole, along the arcade vessels or around the disc, and occasionally in mid-periphery -Inflammatory BRVO -Papilledema 	<ul style="list-style-type: none"> -FFA – leakage from vessels, early hypofluorescent lesions with late hyperfluorescence corresponding to retinitis lesion -OCT – Hyperreflective lesion involving primarily the inner layers of the retina, may be associated with cystoid macular edema 	<ul style="list-style-type: none"> -Leucocytosis -Thrombocytopenia -Serology – Weil Felix test* (most common), ELISA immunofluorescent assay (gold standard), latex agglutination test, indirect hemagglutination test 	<ul style="list-style-type: none"> -Oral Doxycycline 100mg twice a day for 2-3 weeks -Oral corticosteroids in case of optic neuritis or clinically evident retinal vasculitis -Ciprofloxacin and Azithromycin are alternative antibiotics
Typhoid	<ul style="list-style-type: none"> -Fever -Myalgia -Immunocompetent status 	<ul style="list-style-type: none"> -Decreased vision following febrile illness -Floater -Diplopia -Drooping of eyelid 	<ul style="list-style-type: none"> (Acute stage) -Catarrhal conjunctivitis -Ulcerative keratitis -Keratomalacia -Iridocyclitis -Loss of accommodation -Abducens palsy -Ptosis 	<ul style="list-style-type: none"> (Acute stage) -Vitritis -Choroiditis -Optic neuritis (Post-fever stage) -Focal or multifocal retinitis -Stellate maculopathy -Inflammatory vascular occlusion -Large neurosensory detachment -Endophthalmitis 	<ul style="list-style-type: none"> -FFA – early hypofluorescent lesions with late hyperfluorescence and staining and leakage from inflamed retinal vessels -OCT - Hyperreflectivity of inner retinal layers with after shadowing 	<ul style="list-style-type: none"> -Blood culture and isolation of S typhi -Serology – Widal test, serum IgG and salivary IgA antibodies are more sensitive 	<ul style="list-style-type: none"> -Topical NSAIDs -Corticosteroids (topical, subtenons, oral or intravenous) in combination with Ciprofloxacin -Pars plana vitrectomy (PPV) with intravitreal and systemic antibiotics incase of endophthalmitis

Systemic disease	Systemic history and symptoms	Ocular symptoms	External and anterior involvement	Fundus features	Ocular imaging	Laboratory diagnosis	Treatment
Dengue	<ul style="list-style-type: none"> -Mosquito bite (Aedes aegypti, Aedes albopictus) -Flulike illness -Rash -Abdominal discomfort -Musculoskeletal pain -Glandular enlargement 	<ul style="list-style-type: none"> -Reduced vision within a month of febrile episode -Retroorbital pain -Floaters 	<ul style="list-style-type: none"> -May be normal 	<ul style="list-style-type: none"> -Foveolitis -Retinitis -Retinal vascular occlusion -Vitreous hemorrhage (VH) -Macular edema -Disc edema -Acute macular neuroretinopathy (AMN) -Residual nummular retinochoroiditis scars 	<ul style="list-style-type: none"> -FFA – vascular occlusion, hyperfluorescence from arteriolar or venular leakage and RPE hyperfluorescence -ICGA- middle to late phase hypercyanescent spots in areas of subclinical involvement -OCT – neurosensory detachment, RPE thickening at fovea (foveolitis) and RPE atrophy, hyperreflectivity of outer nuclear layer (ONL) and outer plexiform layer (OPL) followed by ONL disruption and thinning in AMN -OCTA – flow deficit in the deep capillary plexus with or without flow voids in the superficial capillary plexus 	<ul style="list-style-type: none"> -Thrombocytopenia -Serology- NS 1 antigen assay, Dengue IgM, IgG antibody testing, RT-PCR for DENV serotypes 1,2,3 and 4 RNA 	<ul style="list-style-type: none"> -Spontaneous recovery may be seen -Corticosteroids depending on degree of involvement -PPV for VH -Prevention of mosquito bite is mainstay control

Systemic disease	Systemic history and symptoms	Ocular symptoms	External and anterior involvement	Fundus features	Ocular imaging	Laboratory diagnosis	Treatment
Chikungunya	<ul style="list-style-type: none"> -Mosquito bite (Aedes aegypti) -Sudden onset fever with chills -Lower backache -Myalgia -Neurological complications 	<ul style="list-style-type: none"> -Blurring of vision -Colour vision defect -Central or centrocecal scotoma or peripheral field defect 	-May be normal	<ul style="list-style-type: none"> -Retinitis usually with minimal vitritis -Retinal vasculitis with retinal hemorrhages -Choroiditis -Optic neuritis 	<ul style="list-style-type: none"> -FFA- early hypofluorescence with late hyperfluorescence along the border of retinitis, disc leakage and vascular leakage with or without capillary nonperfusion areas -OCT – hyporeflectivity in areas of neurosensory detachment and hyperreflectivity of inner retina with after shadowing in areas of retinitis -OCTA – flow void areas in the superficial and deep capillary plexus 	<ul style="list-style-type: none"> -PCR and serological tests – IgM and IgG antibodies 	<ul style="list-style-type: none"> -May be self-limiting -Topical and systemic corticosteroids basis location and degree of involvement -Prevention of mosquito bite is mainstay control

Systemic disease	Systemic history and symptoms	Ocular symptoms	External and anterior involvement	Fundus features	Ocular imaging	Laboratory diagnosis	Treatment
West Nile virus	<ul style="list-style-type: none"> -Mostly asymptomatic -Selflimiting febrile illness -Severe neurologic disease may be seen with advanced age and diabetics 	<ul style="list-style-type: none"> -Decreased vision days to weeks after febrile illness -Floaters 	<ul style="list-style-type: none"> -Anterior uveitis in the absence of chorioretinitis 	<ul style="list-style-type: none"> -Typically bilateral involvement -Multifocal chorioretinitis in scattered or linear pattern, oriented radially in nasal and peripheral fundus and may be curvilinear in the temporal and posterior fundus corresponding to the course of nerve fibre layer -Wedge shaped zones of atrophy with RPE mottling -Occlusive vasculitis -Optic neuritis and papilledema 	<ul style="list-style-type: none"> -FFA – early hypofluorescence with late hyperfluorescence corresponding to clinical chorioretinitis lesions -ICGA – well delineated hypofluorescent choroidal spots more than those appreciated of FFA. -OCT- focal elevation of the choroids with hyperreflectivity of retinal layers through the lesions 	<ul style="list-style-type: none"> -PCR and serological tests – IgM and IgG antibodies 	<ul style="list-style-type: none"> -No proven treatment -Topical steroids for anterior uveitis -Peripheral retinal photocoagulation for neovascularization following occlusive retinal vasculitis -PPV for VH and antiVEGF for CNVM and macular edema

Systemic disease	Systemic history and symptoms	Ocular symptoms	External and anterior involvement	Fundus features	Ocular imaging	Laboratory diagnosis	Treatment
Zika virus	<ul style="list-style-type: none"> -Fever -Skin rash with itching 	<ul style="list-style-type: none"> -Red eye -Decreased vision 	<ul style="list-style-type: none"> -Conjunctival hyperemia -Non-purulent conjunctivitis -Non-granulomatous anterior uveitis -Congenital cataract -Strabismus 	<ul style="list-style-type: none"> -Retinitis -RPE mottling -Retinal hemorrhages 	<ul style="list-style-type: none"> -FAF – multiple hyper autofluorescent lesions -FFA – early disc staining with multiple areas of early hypo and late hyperfluorescence corresponding to retinitis lesions 	<ul style="list-style-type: none"> -PCR in acute phase – 1 week from blood and 2 weeks from urine samples -Serology – unreliable due to cross reaction with other flaviruses 	<ul style="list-style-type: none"> -No specific treatment -Topical steroids for anterior uveitis -Surgery for congenital cataract and strabismus



Systemic disease	Systemic history and symptoms	Ocular symptoms	External and anterior involvement	Fundus features	Ocular imaging	Laboratory diagnosis	Treatment
SARS-CoV-2 virus	<ul style="list-style-type: none"> -Fever -Cough -Asthenia -Anosmia -Thoracic pain -Myalgia -Exposure to COVID-19 positive patient 	<ul style="list-style-type: none"> -Redness of one or both eyes -Acute diminution of vision Dyschromatopsia -Negative scotomas 	<ul style="list-style-type: none"> -Conjunctivitis -Anterior uveitis 	<ul style="list-style-type: none"> -Multifocal retinitis -Retinal hemorrhages -White centered hemorrhages (Roth spots) -Cotton wool spots -Retinal vascular occlusions -Optic neuritis 	<ul style="list-style-type: none"> -FFA – early hypo to late hyperfluorescence at site of retinitis lesions -OCT – pinpoint hyperreflective dots in vitreous cavity, outer retinal and/or inner retina hyperreflectivity in areas of retinitis and cotton wool lesions, AMN and PAMM lesions on macular OCT -OCTA – reduced flow signals in DCP and SCP while no flow voids noted in choriocapillaries layer 	<ul style="list-style-type: none"> -Lymphopenia -Thrombocytosis -Raised CRP -Hyperferritinemia -Increased serum aspartate transferase -Serology – COVID IgM and IgG antibodies, RT PCR for antigen 	<ul style="list-style-type: none"> -No specific treatment -May show spontaneous resolution -Short course of oral steroids and anticoagulants in cases of vascular occlusion

*Weil Felix Test Interpretation

OX19 positive - Epidemic/Endemic Typhus

OXK positive - Scrub/Trench Typhus

OX19 and OX2 positive - Rocky Mountain spotted fever

OX19, OX2 and OXK negative - Rickettsial pox

References:

1. Mahendradas P, Kawali A, Luthra S, Srinivasan S, Curi AL, Maheswari S, Ksiao I, Khairallah M. Post-fever retinitis - Newer concepts. *Indian J Ophthalmol*. 2020 Sep;68(9):1775-1786.
2. Mahendradas P, Sridharan A, Kawali A, Srinivasan S, Venkatesh R. Role of Ocular Imaging in Diagnosis and Determining Response to Therapeutic Interventions in Posterior and Panuveitis, *Asia-Pacific Journal of Ophthalmology*: January-February 2021 - Volume 10 - Issue 1 - p 74-86.
3. Nagaki Y, Hayasaka S, Kadoi C, Matsumoto M, Sakagami T. Branch retinal vein occlusion in the right eye and retinal hemorrhage in the left in a patient with classical Tsutsugamushi disease. *Jpn J Ophthalmol* 2001;45:108-10.
4. Khairallah M, Ladjimi A, Chakroun M, Messaoud R, Yahia SB, Zaouali S, et al. Posterior segment manifestations of rickettsia conorii infection. *Ophthalmology* 2004;111:529-34.
5. Kawali A, Mahendradas P, Srinivasan P, Yadav NK, Avadhani K, Gupta K, et al. Rickettsial retinitis an Indian perspective. *J Ophthalmic Inflamm Infect* 2015;5:37.
6. Balasundaram MB, Manjunath M, Baliga G, Kapadi F. Ocular manifestations of Rickettsia conorii in South India. *Indian J Ophthalmol* 2018;66:1840 4
7. Kahloun R, Jelliti B, Ksiao I, et al. Swept-source optical coherence tomography angiography in rickettsial retinitis. *Retin Cases Brief Rep*. 2019;13:348-351.
8. Mahajan SK, Kashyap R, Kanga A, Sharma V, Prasher BS, Pal LS. Relevance of Weil Felix test in diagnosis of scrub typhus in India. *J. Assoc. Physicians India* 2006;54:619 21.
9. Kawali A, Srinivasan S, Mohan A, Bavaharan B, Mahendradas P, Shetty B. Epidemic retinitis with macular edema -Treatment outcome with and without steroids. *Ocul Immunol Inflamm* 2020;21:1 5.
10. Biggs HM, Behravesh CB, Bradley KK, Dahlgren FS, Drexler NA, Dumler JS, et al. Diagnosis and management of Tickborne Rickettsial diseases: Rocky mountain spotted fever and other spotted fever group Rickettsioses, Ehrlichioses, and Anaplasmosis United States. *MMWR Recomm Rep* 2016;65:1 44.
11. de Schweintz GE. Chapter I. In *The ocular complications of typhoid fever*, de Schweintz GE (eds.) BiblioBazaar. 2015. p. 2-5.
12. Agarwal M, Malathi J, Biswas J. Frosted branch angiitis in a patient with typhoid fever. *Ocul Immunol Inflamm* 2018;26:776 8.
13. Relhan N, Pathengay A, Albin T, Priya K, Jalali S, Harry W Flynn Jr. A case of vasculitis, retinitis and macular neurosensory detachment presenting post typhoid fever. *J Ophthalmic Inflamm Infect* 2014;4:23.

14. Redhuan NEM, Chin KL, AdnanAS, IsmailA, Balaram P, Phua KK. Salivary Anti 50kDa antibodies as a useful biomarker for diagnosis of typhoid fever. *J Clin Diagn Res* 2017;11;6:DC10 3.
15. Mathur JS, Nema HV, Char JN, Mehra KS. Post typhoid retinal detachment. *Indian J Ophthalmol* 1970;18:135 7.
16. Acharya P, Ramamurthy LB, Venugopal KC, Manipur SR. Evaluation of posterior segment manifestations following typhoid fever a clinical study. *Indian J Clin Exp Ophthalmol* 2018;4:421 425.
17. World Health Organization. Dengue and dengue haemorrhagic fever—Fact sheet. 2009. Available from: <http://www.who.int/csr/disease/dengue/en>. [Last accessed on 2011 May 19].
18. Yip VC, Sanjay S, Koh YT. Ophthalmic complications of dengue fever: A systematic review. *OphthalmolTher* 2012;1:2.
19. Lim WK, Mathur R, KohA, Yeoh R, Chee SP. Ocular manifestations of dengue fever. *Ophthalmology* 2004;111:2057 64.
20. Bacsal KE, Chee S, Cheng C, Flores JVP. Dengue associated maculopathy. *Arch Ophthalmol* 2007;125:501-10.
21. Teoh SC, Chee CK, Laude A, Goh KY, Barkham T. Optical coherence tomography patterns as predictors of visual outcome in dengue related maculopathy. *Retina* 2010;30:390 8.
22. Su DH, Bacsal K, Chee SP, Flores JV, Lim WK, Cheng BC, et al.; Dengue Maculopathy Study Group. Prevalence of dengue maculopathy in patients hospitalized for dengue fever. *Ophthalmology* 2007;114:1743 7.
23. Loh BK, Bacsal K, Chee SP, Cheng BC, Wong D. Foveolitis associated with dengue fever: A case series. *Ophthalmologica* 2008;222:317-20.
24. Li M, Zhang X, Ji Y, Ye B, Wen F. Acute macular neuroretinopathy in dengue fever: Short term prospectively followed up case series. *JAMA Ophthalmol* 2015;133:1329-33.
25. MouryaDT, MishraAC. Chikungunya fever. *Lancet* 2006;368:186-7
26. Schuffenecker I, Itean I, Michault A, Murri S, Frangeul L, VaneyMC, et al. Genome microevolution of chikungunya viruses causing the Indian Ocean outbreak. *PLoS Med* 2006;3:e263.
27. Mahendradas P, Avadhani K, Shetty R. Chikungunya and the eye: A review. *J Ophthalmic Inflamm Infect* 2013;3:35. doi: 10.1186/1869 5760 3 35.
28. Lalitha P, Rathinam S, Banushree K, Maheshkumar S, Vijayakumar R, Sathe P. Ocular involvement associated with an epidemic outbreak of Chikungunya virus infection. *Am J Ophthalmol* 2008;144:552-6.

29. Mahesh G, Giridhar A, Shedbele A, Kumar R, Saikumar SJ. A case of bilateral presumed chikungunya neuroretinitis. *Indian J Ophthalmol* 2009;57:148-150
30. Mittal A, Mittal S, Bharati MJ, Ramakrishnan R, Saravanan S, Sathe PS. Optic neuritis associated with Chikungunya virus infection in South India. *Arch Ophthalmol* 2007;125:1381-6.
31. Salceanu SO, Raman V. Recurrent Chikungunya retinitis. *BMJ Case Rep* 2018: bcr2017222864. doi: 10.1136/bcr.2017.222864.
32. Agarwal A, Choudhary T, Gupta V. Optical coherence tomography angiography features of bilateral retinopathy associated with Chikungunya fever. *Indian J Ophthalmol* 2018;66:142-5.
33. Khairallah M, Ben Yahia S, Ladjimi A, Zeghidi H, Ben Romdhane F, Besbes L, et al. Chorioretinal involvement in patients with West Nile virus infection. *Ophthalmology* 2004;111:2065-70.
34. Garg S, Jampol LM. Systemic and intraocular manifestations of West Nile virus infection. *Surv Ophthalmol* 2005;50:3-13.
35. Chan CK, Limstrom SA, Tarasewicz DG, Lin SG. Ocular features of West Nile virus infection in North America: A study of 14 eyes. *Ophthalmology* 2006;113:1539-46.
36. Khairallah M, Ben Yahia S, Attia S, Zaouali S, Ladjimi A, Messaoud R. Linear pattern of West Nile virus associated chorioretinitis is related to retinal nerve fibres organization. *Eye (Lond)* 2007;21:952-5.
37. Khairallah M, Chee SP, Rathinam SR, Attia S, Nadella V. Novel infectious agents causing uveitis. *Int Ophthalmol* 2010;30:465-83.
38. Khairallah M, Ben Yahia S, Attia S, Zaouali S, Jelliti B, Jenzri S, et al. Indocyanine green angiographic features in multifocal chorioretinitis associated with West Nile virus infection. *Retina* 2006;26:358-9.
39. Campos GS, Bandeira AC, Sardi SI. Zika virus outbreak, Bahia, Brazil. *Emerg Infect Dis* 2015;21:1885-6.
40. Singh MS, Marquezan MC, Omiadze R, Reddy AK, Belfort R Jr, May WN. Inner retinal vasculopathy in Zika virus disease. *Am J Ophthalmol Case Rep* 2018;10:6-7.
41. Manangeeswaran M, Kielczewski JL, Sen HN, Xu BC, Ireland DDC, McWilliams IL, et al. ZIKA virus infection causes persistent chorioretinal lesions. *Emerg Microbes Infect* 2018;7:96.
42. Jimenez P, Kestelman E, Kestelman B, Vizzoni AG, Cerbino Neto J, Curi ALL. Multifocal choroiditis secondary to acute Zika virus infection. *Ocul Immunol Inflamm* 2019;30:1-4.

43. Huang C, Wang Y, Li X, Ren L, Zhao J, Hu Y, Zhang L, Fan G, Xu J, Gu X, Cheng Z, Yu T, Xia J, Wei Y, Wu W, Xie X, Yin W, Li H, Liu M, Xiao Y, Gao H, Guo L, Xie J, Wang G, Jiang R, Gao Z, Jin Q, Wang J, Cao B. Clinical features of patients infected with 2019 novel coronavirus in Wuhan, China. *Lancet*. 2020 Feb 15;395(10223):497-506.
44. Gascon P, Briantais A, Bertrand E, Ramtohl P, Comet A, Beylerian M, Sauvan L, Swiader L, Durand JM, Denis D. Covid-19-Associated Retinopathy: A Case Report. *Ocul Immunol Inflamm*. 2020 Nov 16;28(8):1293-1297.
45. Madan S, Beri S. Conjunctivitis in Novel Coronavirus Disease (COVID-19). *Indian J Occup Environ Med*. 2020 May-Aug;24(2):129-130.
46. Sheth JU, Narayanan R, Goyal J, Goyal V. Retinal vein occlusion in COVID-19: A novel entity. *Indian J Ophthalmol*. 2020 Oct;68(10):2291-2293.
47. Invernizzi A, Pellegrini M, Messenio D, Cereda M, Olivieri P, Brambilla AM, Staurenghi G. Impending Central Retinal Vein Occlusion in a Patient with Coronavirus Disease 2019 (COVID-19). *Ocul Immunol Inflamm*. 2020 Nov 16;28(8):1290-1292.
48. Ortiz-Seller A, Martínez Costa L, Hernández-Pons A, Valls Pascual E, Solves Alemany A, Albert-Fort M. Ophthalmic and Neuro-ophthalmic Manifestations of Coronavirus Disease 2019 (COVID-19). *Ocul Immunol Inflamm*. 2020 Nov 16;28(8):1285-1289.
49. Montesel A, Bucolo C, Mouvet V, Moret E, Eandi CM. Case Report: Central Retinal Artery Occlusion in a COVID-19 Patient. *Front Pharmacol*. 2020 Dec 23;11:588384.
50. Zago Filho LA, Lima LH, Melo GB, Zett C, Farah ME. Vitritis and Outer Retinal Abnormalities in a Patient with COVID-19. *Ocul Immunol Inflamm*. 2020 Nov 16;28(8):1298-1300.





Current Concepts in Viral Uveitis: Expert Panel Discussion



Dr. Reema Bansal
PGI, Chandigarh



Dr. Sudharshan S
Sankara Nethralaya, Chennai



Dr. Kalpana Babu
Narayana Nethralaya, Chennai

Current Concepts in Viral Uveitis: Expert Panel Discussion

Viral uveitis represents one of the most challenging diagnostic and therapeutic infectious uveitic entity because of its protean clinical manifestations. This condition can affect the anterior as well as posterior segment, and often cause rapidly progressive sight-threatening disease that requires emergent therapy. While there have been numerous advances in the laboratory techniques of detection and diagnosis, and management of this condition, several controversies and unanswered questions remain. There are various ongoing challenges in terms of appropriate use of advanced diagnostic techniques such as polymerase chain reaction, use of oral/topical antiviral agents, and duration of therapy, among others. There is also limited understanding of the role of retinal imaging and its correlation with pathophysiology of the retina and choroid.

We asked several pioneering uveitis experts for their insight into the current management guidelines of viral uveitis. Here they share their experiences with clinical and research aspects in this condition, discuss current limitations in our understanding, and their expert approach in managing such cases in their clinics.

Questions:

1. If you have a patient who visits with the first episode of acute anterior uveitis, what are the key clinical findings that make you suspect viral etiology?

» Dr. Reema Bansal

Iris atrophy, high IOP, pigmented KPs

» Dr. Sudharshan S

Segmental iris atrophy, scattered – KPs (including Pigmented), high IOP, unilateral

» Dr. Kalpana Babu

I would suspect viral etiology in a case of unilateral anterior uveitis with increased intraocular pressure, iris atrophic changes, pigmented keratic precipitates with or without corneal involvement

2. Do you routinely perform polymerase chain reaction (PCR) for detection of viral genome in viral anterior uveitis? If so, which kind of PCR do you prefer?

» Dr. Reema Bansal

Often, yes. Multiplex PCR

» Dr. Sudharshan S

Of late, yes – almost routinely in all suspected cases – nested or Real time PCR based on patient affordability and index of suspicion

» Dr. Kalpana Babu

A diagnosis of viral anterior uveitis is usually made clinically and PCR is used for confirmation of the type of virus to decide the treatment.

I initially use a multiplex PCR to test for different viruses and if positive do a real time PCR (more so in CMV positive cases) which will be useful for monitoring of treatment.

3. What is your approach if the viral PCR is negative and there is high suspicion of viral disease?

» Dr. Reema Bansal

Treat as Viral uveitis

» Dr. Sudharshan S

Treat with antivirals – based on strong clinical suspicion

» Dr. Kalpana Babu

It is known that PCR can be negative in cases of viral uveitis (especially CMV, rubella and some cases of HSV). We do not do a Goldman Whitman coefficient routinely in India. We also know that the chances of PCR being positive in viral uveitis is higher when associated with high IOP spikes and presence of pigmented keratic precipitates. So, If there is a high suspicion based on the characteristic clinical findings, I will still treat the uveitis as viral uveitis and will not hesitate to repeat the AC tap during periods of high IOP spike and appearance of pigmented keratic precipitates.

4. Do you perform serology for immunoglobulins in your patients routinely?

» Dr. Reema Bansal

Sometimes

» Dr. Sudharshan S

No never

» Dr. Kalpana Babu

No

5. What is your experience with sensitivity and specificity of viral PCR tests?

» Dr. Reema Bansal

Though no official publication or data, about 90% sensitivity.

» Dr. Sudharshan S

Guess a bit lesser – probably about 70 % (not based on any studies though)

» Dr. Kalpana Babu

In our series sensitivity of PCR for VZV is close to 90%, 60-70% with HSV and CMV and very poor for rubella

6. What is your preferred local, oral and topical therapy for viral anterior uveitis, along with its duration?

» Dr. Reema Bansal

- Acyclovir 800 mg tds or valacyclovir 1 gm tds (depending upon affordability) for oral (with tapering after 1 month, to be continued and tapered over total 3-6 months)
- Acyclovir ointment 5 times/day
- Betamethasone-Neomycin eyedrops + Cycloplegics

» Dr. Sudharshan S

Topical – Prednisolone eye drops in tapering dose for about 4-6 weeks and then followed by topical NSAIDs for 3 months. AGMs and Cycloplegics – Homatropine
Oral – Tab Valcivir 1 G TDS 3 – 6 months

» Dr. Kalpana Babu

It varies with the aetiology of the virus detected.

For HSV and VZV: It will be oral acyclovir or valacyclovir for a minimum of at least 3 months. If there are recurrences even after 3 months therapy, will treat them with maintenance dose of any of the above drugs for at least a year or more until no recurrences.

For CMV: It is usually topical ganciclovir gel (0.15%) till there is no active inflammation. Refractory high IOP, chronic disease, presence of endothelitis and presence of immune deficiency are definite indications for me to start the patient on oral valganciclovir.

In all these cases, I also start topical steroids under topical antiviral cover to bring down the inflammation. I would tend to avoid prostaglandin analogues in cases of viral uveitis.

Kindly also refer to our review article: Babu K, Konana VK, Ganesh SK, Patnaik G, Chan NS, Chee SP, et al. Viral anterior uveitis. Indian J Ophthalmol 2020;68:1764-73.

7. What is the frequency of recurrence you encounter in your clinical practice with viral anterior uveitis?

» Dr. Reema Bansal

Sometimes, but not very common

» Dr. Sudharshan S

30-40% - chronic and recurrent
After about a year – about 10 %

» Dr. Kalpana Babu

It depends on the aetiology, host immune response and the interval between onset of uveitis and initiation of treatment.

8. How you manage recurrent viral anterior uveitis in a patient who has defaulted treatment?

» Dr. Reema Bansal

Start treatment as before

» Dr. Sudharshan S

Restart treatment as before if active and continue for atleast 6 months to a year

» Dr. Kalpana Babu

Good counselling and restarting treatment.

9. Do you give prophylactic oral antiviral therapy in case the patients require cataract or glaucoma surgery?

» Dr. Reema Bansal

Choice of cataract or glaucoma surgeon, but oral steroids definitely.

» Dr. Sudharshan S

Definitely systemic Antiviral cover for cataract or glaucoma surgery with or without systemic steroids

» Dr. Kalpana Babu

I am guided by the frequency of recurrences of viral uveitis prior to cataract surgery. In cases of patients with multiple recurrences, I give antiviral prophylaxis. Kindly refer to our review article for particulars regarding dosages.

10. What are the key differences in the management of subjects with herpes simplex, varicella zoster, and cytomegalovirus anterior uveitis that you practice?

» Dr. Reema Bansal

CMV anterior uveitis is extremely rare in our practice.

» Dr. Sudharshan S

CMV AU – can be bilateral and is relatively uncommon in comparison to the other two. If unilateral and clinically unable to differentiate, we diagnose CMV AU – based on PCR results. We use topical Ganciclovir along with systemic anti CMV therapy while in HSV or VZV AU – we don't use topical acyclovir if no corneal involvement

» Dr. Kalpana Babu

Please refer to the answer in question 6

11. In subjects with acute retinal necrosis, what is your immediate line of management, with respect to diagnostics and therapeutics?

» Dr. Reema Bansal

IV Acyclovir 750 mg 8 hrly for 14 days (induction phase), followed by oral acyclovir 800 mg/ 5 times/day (maintenance phase). Oral steroids to be started a day after IV acyclovir.

» Dr. Sudharshan S

AC tap – PCR for viruses

Check for immunocompetent/immunocompromised state, Renal function tests, systemic evaluation

If HSV or VZV – IV Acyclovir 500 mg 8th hourly for 2-3 weeks followed by Oral Valcivir 1 G TDS for 6 weeks to 3 months.

Oral Prednisolone at 1 mg/kg body weight after 2 days of IV acyclovir

Intravitreal Ganciclovir 2000 IU – 1-2 doses weekly – based on the clinical condition

To followup for complications /sequelae

If CMV – then IV Ganciclovir followed by Oral valganciclovir

» Dr. Kalpana Babu

Wrt diagnostics: complete blood counts, blood urea, serum creatinine, ELISA for HIV, blood sugars and aqueous tap for PCR to determine the virus aetiology (HSV or VZV)

Wrt therapeutics: The standard of care is either inpatient hospitalization and induction with intravenous (IV) acyclovir 10 mg/kg every 8 hours or 1500 mg/m² per day for 7 to 10 days, followed by maintenance with oral acyclovir 800mg 5 times daily for an additional 6 weeks. The other option is oral valacyclovir 1-2 gm every 3 hours with a slow tapering over 6 weeks.

Initial intravenous antiviral or oral antiviral is effective in the treatment of ARN in term of time taken for regression of retinitis and involvement of the fellow eye.

Prednisone 0.5-1.0 mg/kg/day orally for up to 6 to 8 weeks should be started 24-48 hours after the start of antiviral therapy or once regression of necrosis is demonstrated on followup clinical examinations to reduce the severity of vitreous inflammation. Oral steroids should also be considered particularly when the optic nerve is involved.

12. Which retinal imaging do you perform in subjects with acute retinal necrosis?

» Dr. Reema Bansal

Color fundus photography

» Dr. Sudharshan S

Currently, Optos & Autofluorescence

» Dr. Kalpana Babu

Acute retinal necrosis is a clinical diagnosis. Fundus photography can be used to monitor the progression or resolution of the lesions.

13. Do you perform anterior chamber paracentesis or vitreous tap in order to diagnose viral necrotizing retinitis?

» Dr. Reema Bansal

Usually NOT

» Dr. Sudharshan S

Yes, we routinely do AC tap – in all patients with suspected viral retinitis irrespective of clinical presentation

» Dr. Kalpana Babu

Most of the time the diagnosis of viral necrotizing retinitis is made clinically as they have characteristic clinical patterns. PCR is useful in atypical or non responding cases

14. How often do you perform diagnostic pars plana vitrectomy in establishing a diagnosis of viral necrotizing retinitis? What are your indications for the same?

» Dr. Reema Bansal

Usually NOT. PPV done only if atypical presentation, or poor response to treatment, or associated RD

» Dr. Sudharshan S

Same here

» Dr. Kalpana Babu

Very rare

15. What are the systemic investigations you perform in a case with viral necrotizing retinitis?

» Dr. Reema Bansal

RFT before starting antiviral Rx, HIV

» Dr. Sudharshan S

Same here

» Dr. Kalpana Babu

Please refer to answer for question 11

16. With the current body of literature, do you prefer intravenous or oral antiviral therapies in viral necrotizing retinitis? What is your rationale behind the same?

» Dr. Reema Bansal

I prefer intravenous for induction phase, and oral for maintenance phase therapy. Response is very good with this in my experience.

» Dr. Sudharshan S

Intravenous followed by Oral. To ensure near complete bioavailability of the drug and treatment compliance. Monitoring an inpatient on IV therapy is practical and very important to assess treatment response and pick up complications early.

Intravenous therapy duration is based on clinical response, practical/logistic considerations such as patient compliance, affordability etc – after 2-3 weeks, oral antivirals are started.

» Dr. Kalpana Babu

Systemic therapy is required to prevent involvement of the other eye or prevent other organ involvement especially CNS. With the current evidence, adequate oral antiviral therapy is as good as intravenous therapy

17. What is your regimen of oral corticosteroids in viral retinitis?
Or do you prefer to avoid them?

» Dr. Reema Bansal

Oral steroids Prednisolone 1 mg/kg/day to be started a day after IV acyclovir, tapered and stopped depending upon clinical response. Stopped once all lesions heal.

» Dr. Sudharshan S

Oral Prednisolone @ 1 mg/kg body weight – 1-2 days after initiating systemic antivirals. “Cautious use in immunocompromised, but we use in all immunocompetent patients. This is continued for a period of 6-8 weeks as the case maybe – always under cover of antivirals. Systemic Antivirals are continued after cessation of systemic steroids too

» Dr. Kalpana Babu

Prednisone 0.5-1.0 mg/kg/day orally for up to 6 to 8 weeks should be started 24-48 hours after the start of antiviral therapy or once regression of necrosis is demonstrated on followup clinical examinations to reduce the severe vitreous inflammation. Oral steroids should also be considered particularly when the optic nerve is involved.

18. Do you administer intravitreal antiviral agents in viral necrotizing retinitis if so, what is your treatment protocol?

» Dr. Reema Bansal

Usually NOT

» Dr. Sudharshan S

I routine administer intravitreal antivirals (usually ganciclovir) weekly – in the first 1-2 weeks. Never as monotherapy – always along with systemic antivirals and oral steroids

» Dr. Kalpana Babu

Yes, I use intravitreal ganciclovir along with systemic antivirals. I also use local antivirals (ganciclovir) in those cases with contraindications for systemic antivirals (poor renal function). I give intravitreal injections of ganciclovir (2000 µg in 0.05ml) initially twice a week and then depending on the resolution of the retinitis.

19. What is your opinion on prophylactic laser photocoagulation in acute retinal necrosis?

» Dr. Reema Bansal

I don't do it

» Dr. Sudharshan S

We don't do it – now a days routinely – unless suspected areas of thinning or breaks are noted

» Dr. Kalpana Babu

Controversial

20. What is your surgical approach in viral retinitis-related retinal detachment?

» Dr. Reema Bansal

PPV + endolaser + silicon oil tamponade + 240 band encirclage

» Dr. Sudharshan S

Prefer – 5000 SiO. Surgical procedure – modifications based on the clinical condition

» Dr. Kalpana Babu

I am not a vitreoretinal surgeon and hence I do not have the technical expertise to answer this question. However we do see aggressive postoperative inflammation including fibrinous reaction. Also despite retinal reattachment, visual gain may be limited by optic atrophy and development of epiretinal membrane.

21. When do you suspect Epstein Barr Virus retinitis in your patients?

» Dr. Reema Bansal

Usually NOT

» Dr. Sudharshan S

Same with me

» Dr. Kalpana Babu

I do not have any experience in EB virus related retinitis.

22. What is your diagnostic and management algorithm for fever-related viral retinopathies, specifically dengue and Chikungunya?

» Dr. Reema Bansal

Oral steroids

» Dr. Sudharshan S

*Systemic supportive evidence including past history
Suspicious Clinical features of fever associated retinitis
Ruling out other causes
Doxy and Steroids*

» Dr. Kalpana Babu

They usually resolve with time (on an average 2-4 months depending on the extent of involvement) irrespective of whatever you do and generally have a good prognosis unless they are associated with vascular occlusions. Vision recovery takes over 3-4 months irrespective of usage of steroids (local or systemic)

23. Do you encounter West Nile Virus infections in your practice? If so, how do you diagnose them?

» Dr. Reema Bansal

No

» Dr. Sudharshan S

No

» Dr. Kalpana Babu

I have not encountered so far in my practice.

24. Do you routinely test subjects with Fuchs' uveitis syndrome for rubella infection?

» Dr. Reema Bansal

No

» Dr. Sudharshan S

No

» Dr. Kalpana Babu

No

25. When do you suspect atypical viral uveitis? How do you perform serological diagnosis in such cases?

» Dr. Reema Bansal

When the clinical picture does not corroborate with viral uveitis (and other infectious causes of uveitis are ruled out), but the viral PCR or serology (IgM, IgG for VZV, HSV) is positive.

» Dr. Sudharshan S


I dont understand the question. If it means – viral retinitis ? or panuveitis ?

Rely on IO specimen evaluation – usually AC tap for PCR. Sero titres – only as corroborative evidence – we do not treat relying solely on it

» Dr. Kalpana Babu

Atypical viral uveitis may be suspected if the clinical pattern does not follow a specific pattern and also in children and in patients with immune deficiency. I do not perform serological tests as most adults are already exposed to multiple viruses. Also there is cross reactivity.





Crossword on Viral Retinitis

Dr. Srinivasan Sanjay



Dr. Ankush Kawali




Dr. Padmamalini Mahendradas



Department of Uvea and Ocular Immunology Narayana Nethralaya, Bengaluru

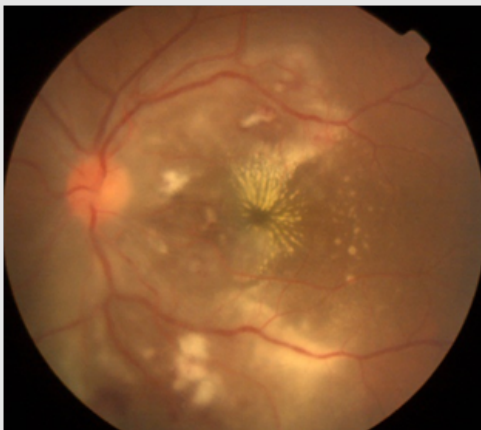Crossword on Viral Retinitis



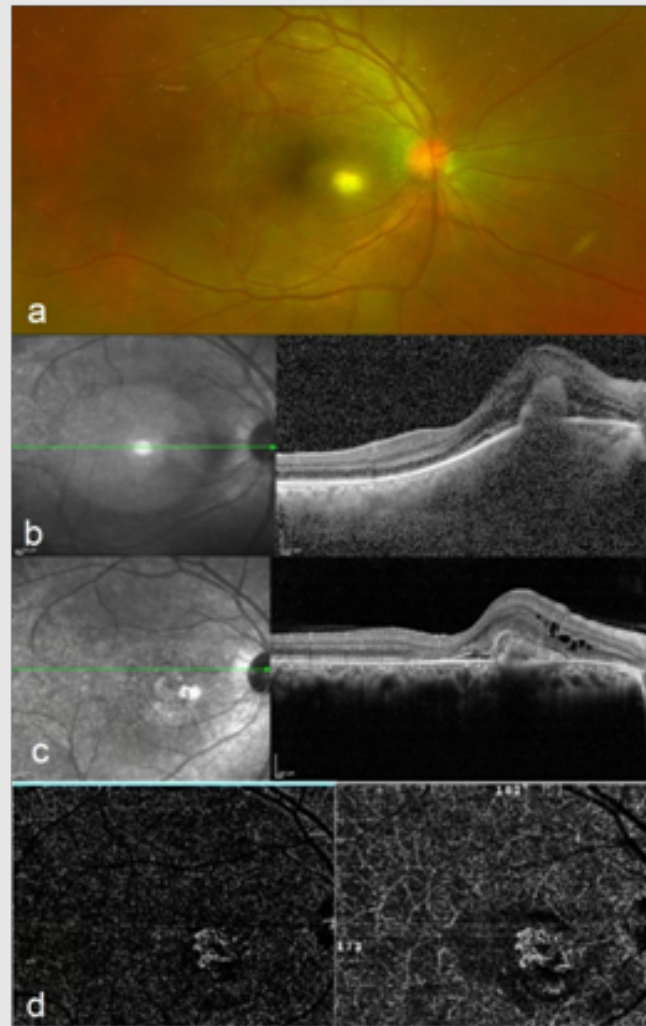
Horizontal

1. This virus was first isolated in 1937 and is an enveloped single-stranded RNA flavivirus. The virus is widely distributed in Africa, Europe, Australia, and Asia. It is a zoonotic disease most often transmitted to human by an infected *Culex* mosquito vector with wild birds serving as its reservoir.

7. A 32 year old nonhypertensive, nondiabetic Indian female presented with a recent history of fever. Left eye colour fundus showing macular star with haemorrhages and multifocal retinitis. Most often it is self-limiting and has various names.



10. A multimodal imaging of the right eye illustrating a rare complication of fungal chorio-retinitis



11. A 20 year old man presents with complaints of blurring of vision in his right eye and has crusting skin rash on his right forehead. Which blood test is most important in this patient?

12. A vaso-occlusive necrotising retinitis originally described in 1971 in the Japanese literature and in 1977 in the English literature. There is no gender predilection, And when caused by non-viral agents, clinicians face diagnostic challenge.

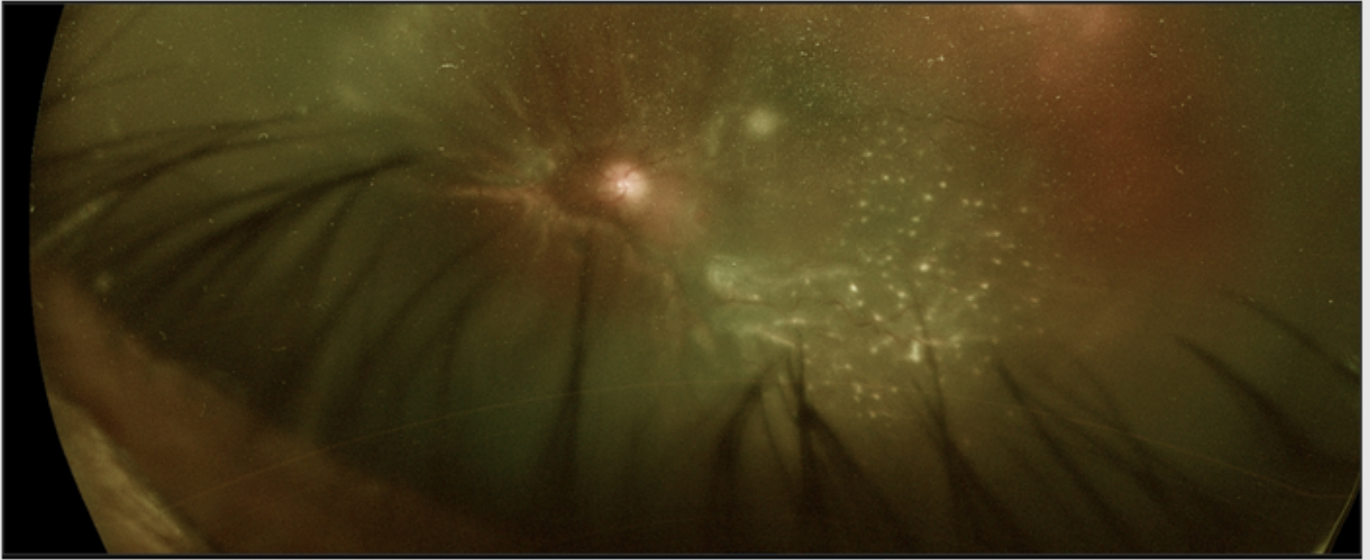
13. This condition occurs in immuno-compromised patients, Inflammation is typically mild and bilateral. Can present with multifocal, deep retinal opacities, Most common cause is varicella zoster virus, the abbreviation often in a literary context can be obscene.

14. Immunocompetent patients who develop neuropsychiatric symptoms associated with ocular symptoms and signs like optic neuritis and haemorrhagic necrotising retinitis. It is imperative to consider this virus as a probable cause and its antibody titres are raised in serum and cerebrospinal fluid.

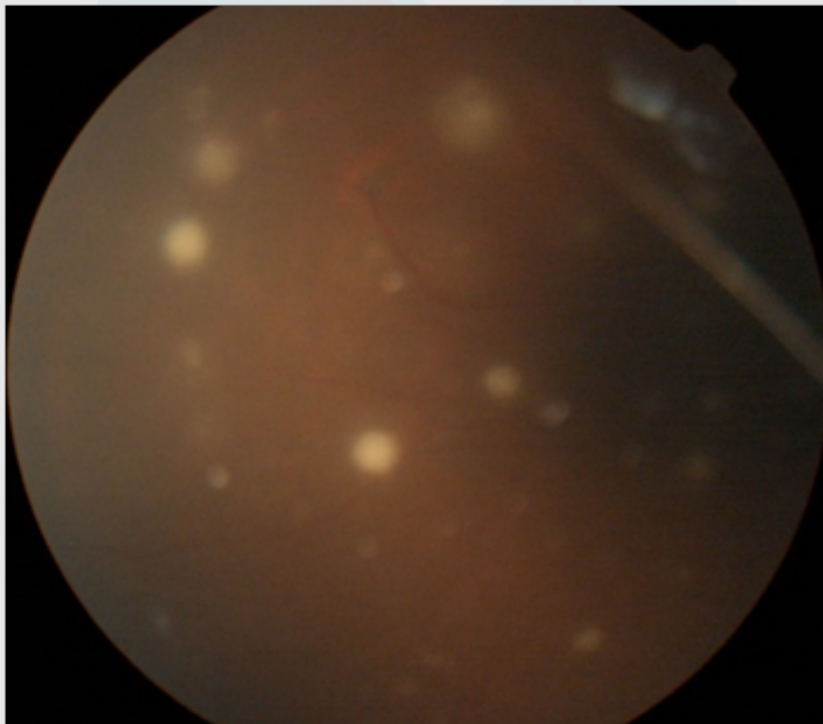
15. This virus causes this pattern of retinopathy of the substances which are commonly used in cuisines all over the world,

Vertical

2. A 66-year-old healthy Indian male developed macular hole with retinal detachment of 1 ½ months duration with outer retinal yellowish spots over detached retina. These yellow lesions are: non-infectious precipitate or viral infiltrates?



3. A non-viral multifocal retinitis, name the disease.

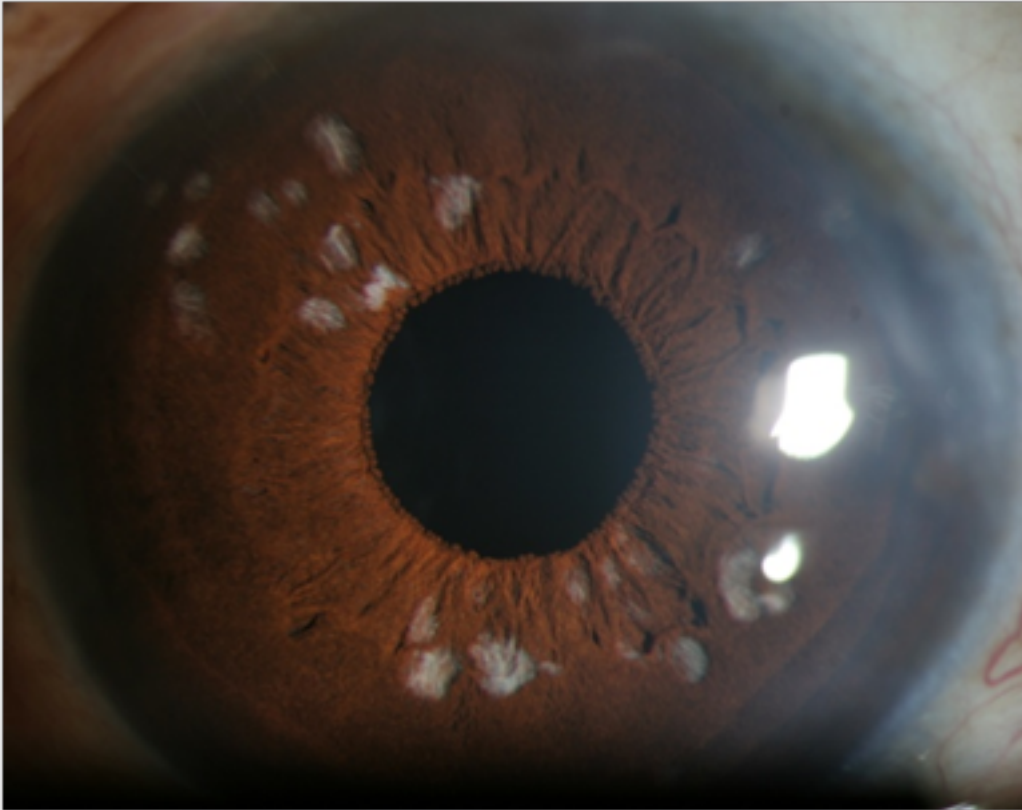


4. Congenital and acquired infections are reported in this viral infection. These include focal macular pigment mottling, chorioretinal atrophy with a predilection for the macular area, congenital glaucoma and optical nerve hypoplasia, and optic disc abnormalities.

5. This medication was originally developed against Ebola virus now being tried on COVID-19 patients.

6. A 74-year-old Indian male, with old punctate bilateral scars on face and the iris with these lesions. What is the condition known as?

8. What could be the systemic disease patient suffered from?



9. This virus was first isolated from the blood of a febrile patient in Tanzania- Mozambique border in 1952-3. It is endemic in parts of west, central and southern Africa and few areas of Asia. The name is derived from the language spoken in the same area as the first official outbreak. The origin of the word can be traced to the root verb which means 'to dry up or become contorted'. Literally, the word translates to 'that which bends up'.





Dr. Gazal Patnaik

Uvea and Medical Retina Fellow
Sankara Nethralaya, Chennai

Email: gazalpatnaik5@gmail.com



Dr. Amitabh Kumar

Department of Uvea, Aditya Birla
Sankara Nethralaya, Kolkata

Email: drakumar_kc@rediffmail.com



Dr. Jyotirmay Biswas

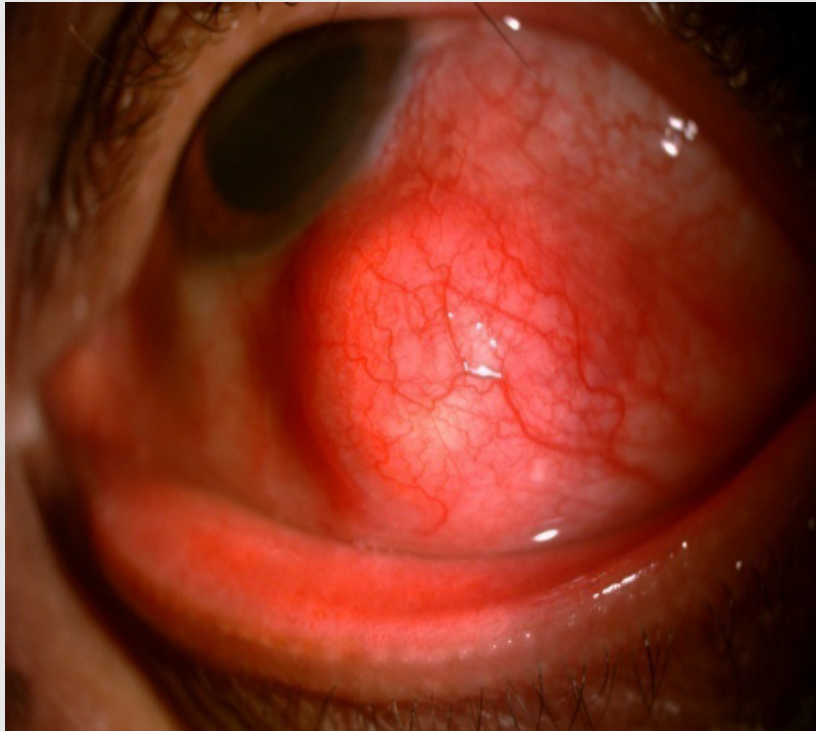Director of Uveitis and Ocular Pathology
Sankara Nethralaya, Chennai

Email: dr.drjb_uveitis@yahoo.co.in

Case 1

Question

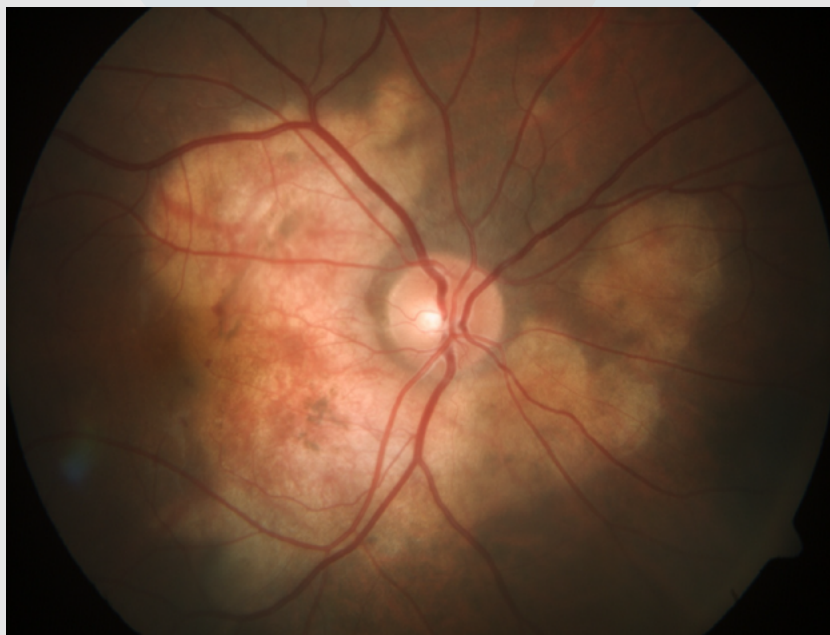A 47-year-old immunocompetent male presented with a painful nodular swelling in the left eye since 2 months.



Case 2

Question

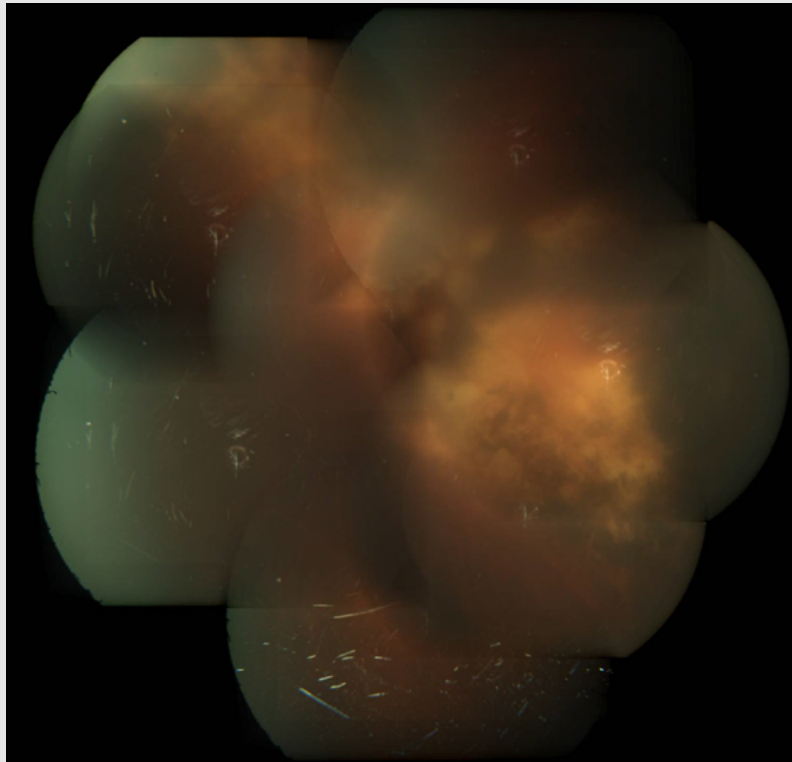
A 30-year-old male presented with a complaint of metamorphopsia in both the eyes since 10 days. Similar fundus picture in both the eyes, as shown in the figure.



Case 3

Question

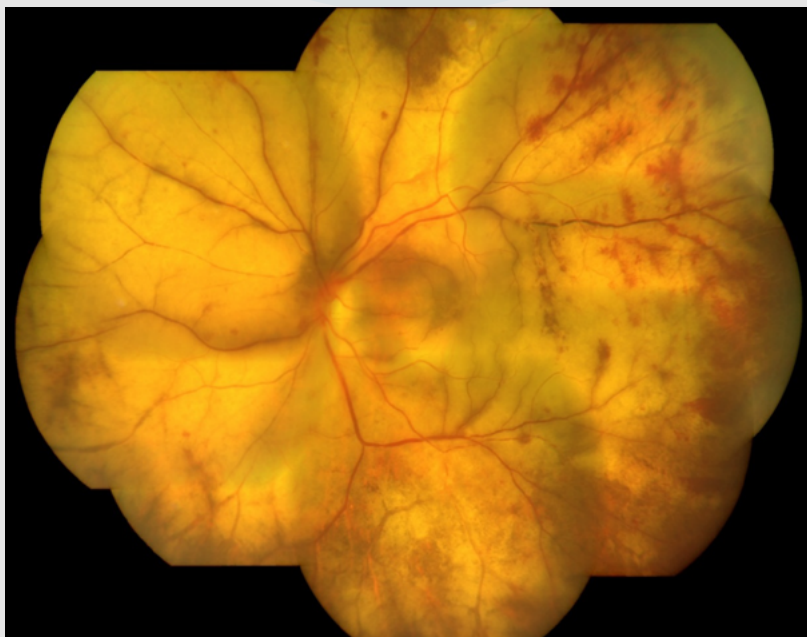A 42-year-old immunocompetent diabetic male, presented with sudden diminution of vision in the left eye since 1 week. Ocular examination revealed a patch of focal retinochoroiditis in the retina, seen through a dense vitreous haze.



Case 4

Question

A 40-year-old immunosuppressed sexually active male presented with sudden, sudden diminution of vision in both the eyes. Fundus findings are as shown in the figure.

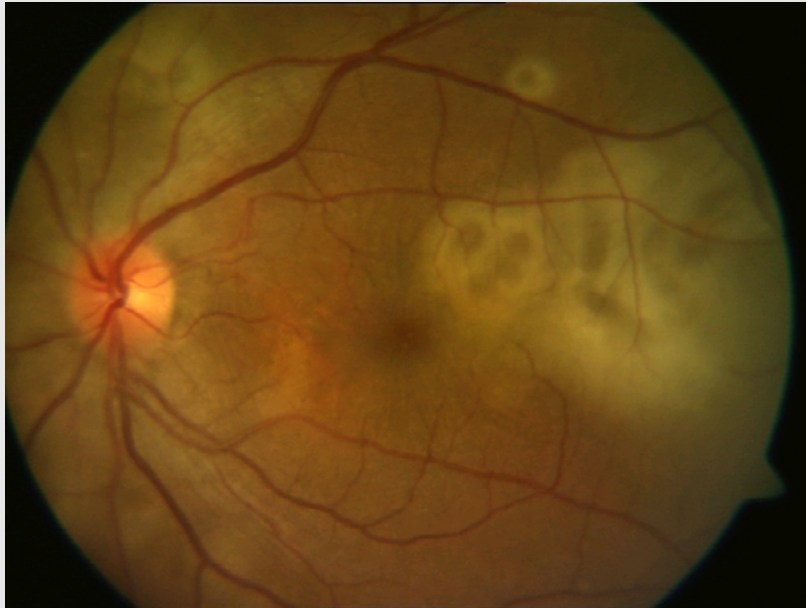

Case 5

Question

42 year old male noticed sudden blurring of vision with metamorphopsia. There was no history of pain and redness.

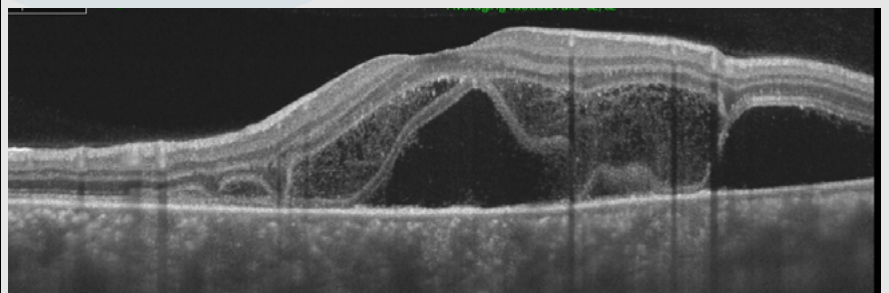
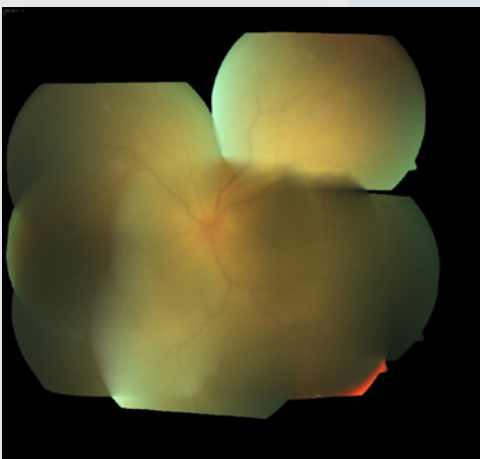
He was diagnosed as multifocal choroiditis



Case 6

Question

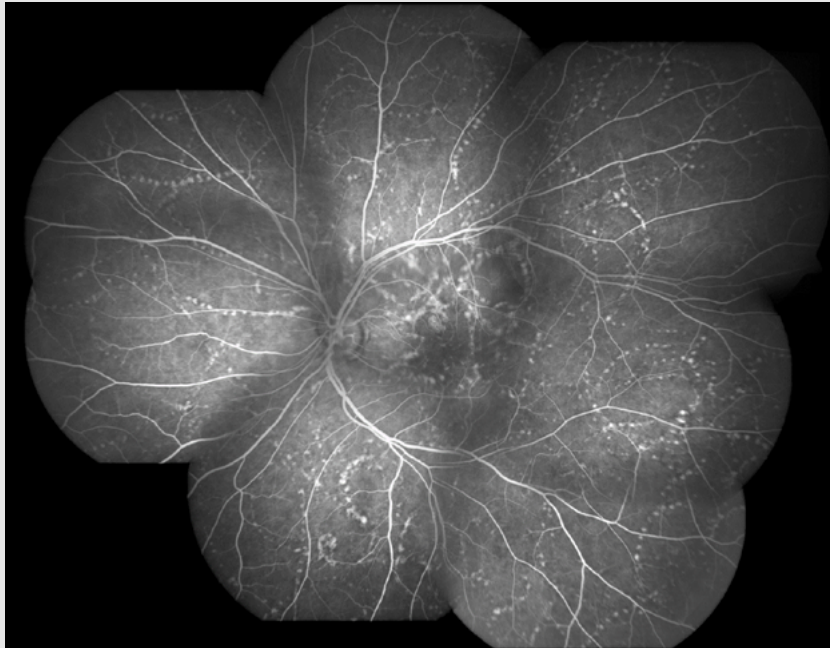30 year old female had sudden blurring of vision in both eyes. Fundus showed serous retinal detachment both eyes. Fundus picture and swept source OCT is shown of one eye



Case 7

Question

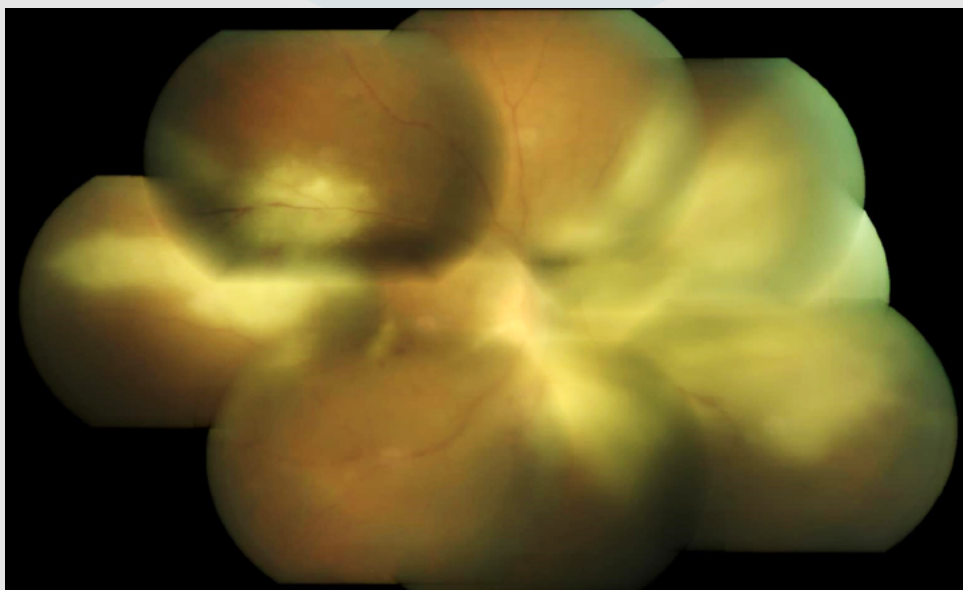
24 year old man was having sudden dimness of vision in the left eye. Systemic evaluation was negative for TB and collagen vascular disorders. FFA of the eye is shown



Case 8

Question

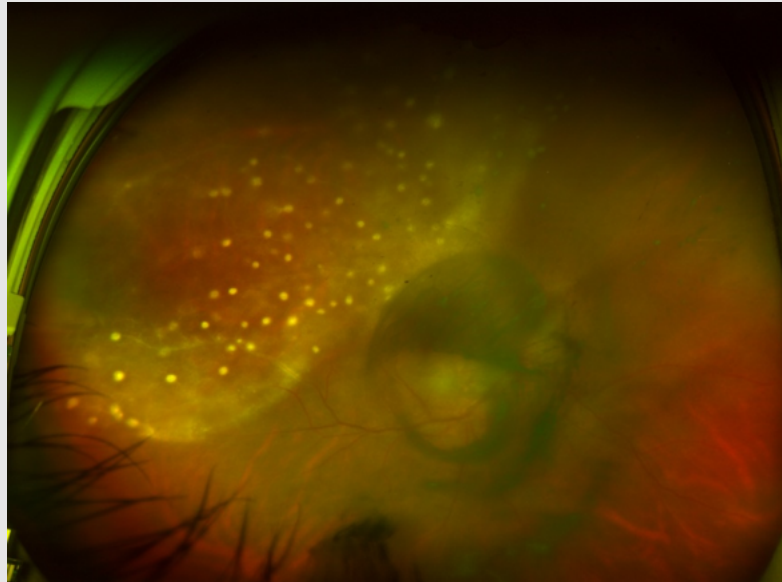
A 57-year-old female presented with complaints of sudden painless gradual diminution of vision in the right eye since 2 weeks not responding to systemic antivirals. Fundus findings are as shown. Her MRI brain showed cortical atrophic changes only. There was no evidence of any other opportunistic infection anywhere else in the body.



Case 9

Question

A 43-year-old male presented with pain, redness, and blurring of vision in both eyes since 1 month. He was treated as bilateral acute retinal necrosis (BARN), by a local ophthalmologist, with intravenous and intravitreal antivirals along with corticosteroids. Fundus examination revealed dense vitritis with hyperemic disc and punctate yellowish superficial retinal precipitates in both eyes.

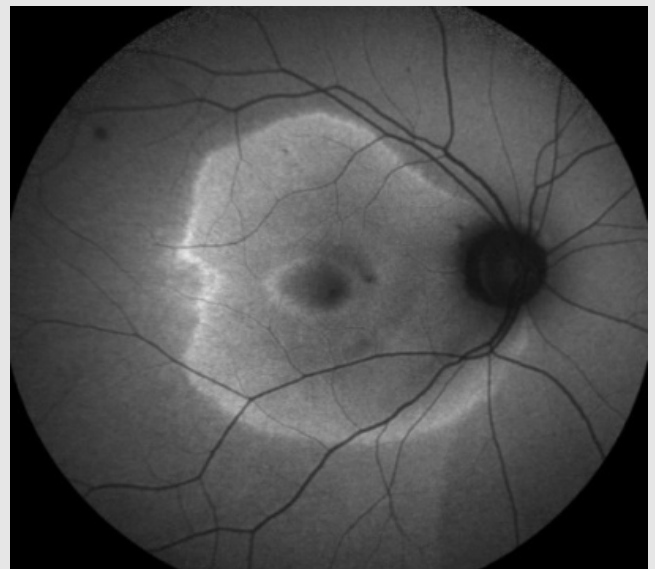
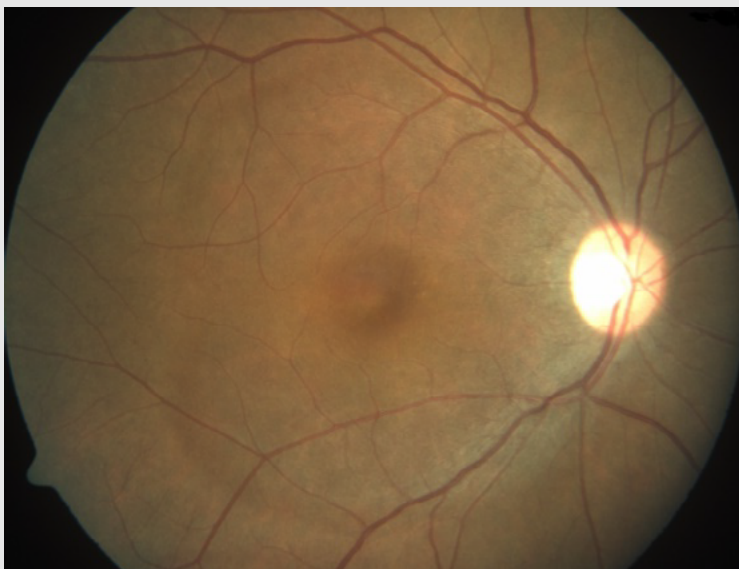

Case 10

Question

A 44-year-old female presented with central vision loss and photopsia in both eyes since 2 months.

The best corrected visual acuity (BCVA) in her right eye was 6/36, N24 and in the left eye was 6/6, N6. Anterior segment findings were within normal limits. Fundus examination demonstrated an annular ring of altered reflex at the posterior pole in both eye





Study of Studies in Viral Uveitis

A 5-year summary of the published literature
(original manuscripts and few important review articles)



Dr. Vinaya Kumar Konana
Email: dr.vini69@gmail.com



Dr. Kalpana Babu
Email: kalpanababumurthy@gmail.com

Department of Uveitis and Ocular inflammation, Vittala International
Institute of Ophthalmology and Prabha Eye Clinic and Research
Centre, Bangalore, Karnataka, India

Study of Studies in Viral Uveitis

Viral anterior uveitis

Pathophysiology

Authors and article citation: Liu Y, Li F, Du L, Pang T, Ma X, Cao Q, Shi L, Li N, Kijlstra A, Yang P. Association of TLR2 Gene Polymorphisms with Presumed Viral-Induced Anterior Uveitis in male Han Chinese. *Exp Eye Res.* 2019 Oct;187:107777.

Year: 2019

Title: Association of TLR2 Gene Polymorphisms with Presumed Viral-Induced T Anterior Uveitis in male Han Chinese

Summary: In conclusion, our results show that the G allele of TLR2/rs7656411 is associated with Presumed Viral-Induced T Anterior Uveitis in Han Chinese, whereby the risk seems to be restricted to men



Authors and article citation: Pohlmann D, Schlickeiser S, Metzner S, Lenglinger M, Winterhalter S, Pleyer U. Different composition of intraocular immune mediators in Posner-Schlossman-Syndrome and Fuchs' Uveitis. *PLoS One.* 2018 Jun 26;13(6):e0199301.

Year: 2018

Title: Different composition of intraocular immune mediators in Posner-Schlossman-Syndrome and Fuchs' Uveitis

Summary: There are remarkable similarities between clinical presentation and cytokine profiles in PSS and FU. Still there are also some significant differences. Both PSS and FU were characterized by TH1 cells mediated immune response, but there seems to be a stronger cytokine response in PSS. Moreover, increased concentrations of IL-1RA, IL-8, IL-10, and IP-10 indicate a more active inflammation in PSS (with CMV as an activator). In contrast, FU presents as a chronic persistent inflammation (with RV as a bystander). Additionally, acetazolamide appears to have an influence on immune mediators in aqueous humor. Further investigations are needed to confirm these new findings.



Authors and article citation: De Groot-Mijnes JDF, Chan ASY, Chee SP, Verjans GMGM. Immunopathology of Virus-Induced Anterior Uveitis. *Ocul Immunol Inflamm.* 2018;26(3):338-346.

Year: 2018

Title: Immunopathology of Virus-Induced Anterior Uveitis

Summary: HSV/VZV and CMV AU are characterized by acute lytic infections, rubella virus-related AU is slowly progressing and does not seem to cause immediate virus-related tissue damage. From an immunological perspective, ocular infection with the aforementioned viruses results in the influx of T and B cells rather than neutrophils, and a proinflammatory immune mediator profile, though the anti-inflammatory cytokine IL-10 is also expressed, possibly to counteract the inflammation.



Authors and article citation: Choi JA, Ju HH, Kim JE, Kim SK, Jee D, Lee J, Park CK, Paik SY. Transcriptional changes after herpes simplex virus type 1 infection in human trabecular meshwork cells. *PLoS One.* 2019 May 28;14(5):e0217567.

Year: 2019

Title: Transcriptional changes after herpes simplex virus type 1 infection in human trabecular meshwork cells

Summary: In human TM cells, HSV-1 induced transcriptional suppression of many components related to fibrosis and enhanced expression of both PDGF-BB and MCP-1. Our study may provide a novel mechanism for the pathogenesis of HSV-1 infection in TM cells.



Diagnostics

Authors and article citation: De Simone L, Belloni L, Aldigeri R, Zerbini A, Mastrofilippo V, Sangiovanni A, Parmeggiani M, Fontana L, Cimino L. Aqueous tap and rapid diagnosis of cytomegalovirus anterior uveitis: the Reggio Emilia experience. *Graefes Arch Clin Exp Ophthalmol.* 2019 Jan;257(1):181-186.

Year: 2018

Title: Aqueous tap and rapid diagnosis of cytomegalovirus anterior uveitis: the Reggio Emilia experience

Summary: To improve the diagnostic accuracy of CMV anterior uveitis, PCR and antibody index are both useful and complimentary. Antibody index was the most sensitive diagnostic tool. One single aqueous tap is sufficient to achieve 100% sensitivity in CMV diagnosis. Early diagnosis is necessary to prevent the development of glaucoma.



Authors and article citation: Relvas LJM, Antoun J, de Groot-Mijnes JDF *et al.* Diagnosis of Cytomegalovirus Anterior Uveitis in Two European Referral Centers. *Ocul Immunol Inflamm.* 2018;26(1):116-121.

Year:2018

Title: Diagnosis of Cytomegalovirus Anterior Uveitis in Two European Referral Centers

Summary: Combining PCR and GWC were very helpful to confirm the clinical diagnosis of CMV AU. In case of very high clinical suspicion and negative results, repeated tap seems to be recommended.



Authors and article citation: Neumann R, Barequet D, Rosenblatt A, *et al.* Herpetic Anterior Uveitis - Analysis of Presumed and PCR Proven Cases. *Ocul Immunol Inflamm.* 2019;27(2):211-218.

Year: 2018

Title: Herpetic Anterior Uveitis – Analysis of Presumed and PCR Proven Cases

Summary: Different HAU-causing Herpesviridae produce common clinical findings; therefore, PCR should be used more often to confirm specific diagnosis. Iris atrophy was associated with more severe disease.

Authors and article citation: Martín Ramírez A, Cardeñoso Domingo L, González Guijarro JJ. PCR Multiplex for CMV Detection in Patients with Anterior Uveitis. Ocul Immunol Inflamm. 2019;27(2):197-202.

Year: 2018

Title: PCR Multiplex for CMV Detection in Patients with Anterior Uveitis

Summary: More than a half of PSS cases and more than a third of hyper-tensive AU are related to CMV infection. These cases should be highly considered because they can be easily and quickly diagnosed by PCR of aqueous samples and allow change the treatment in almost 50% of the patients



Authors and article citation: Qian Z, Fan H, Tao Y, Li W, Gu W.

Herpetic Anterior Uveitis in a Chinese Referral Center: Clinical Manifestations and Laboratory Test Results. Ocul Immunol Inflamm. 2020 Jul 3;28(5):758-763.

Year: 2019

Title: Herpetic Anterior Uveitis in a Chinese Referral Center: Clinical Manifestations and Laboratory Test Results

Summary: Compared with HSV-AU, the intraocular inflammation was more severe in VZV-AU. The intraocular fluid analysis showed higher viral load and IL-8 level in VZV-AU.



Clinical features

Authors and article citation: Gonzales JA, Hinterwirth A, Shantha J, Wang K, Zhong L, Cummings SL, Qian Y, Wilson MR, Acharya NR, Doan T. Association of Ocular Inflammation and Rubella Virus Persistence. JAMA Ophthalmol. 2019 Apr 1;137(4):435-438.

Year: 2018

Title : Association of Ocular Inflammation and Rubella Virus Persistence

Summary: Persistent rubella virus infection is associated with recurrent or chronic anterior or anterior-intermediate uveitis as well as corneal endothelial cell damage. Ophthalmologists should consider rubella virus infection as a potential cause of hypertensive anterior and intermediate uveitis



Authors and article citation: de-la-Torre A, Valdes-Camacho J, Foster CS. Bilateral Herpes Simplex Uveitis: Review of the Literature and Own Reports. Ocul Immunol Inflamm. 2017 Aug;25(4):497-502.

Year: 2016

Title: Bilateral Herpes Simplex Uveitis: Review of the Literature and Own Reports

Summary: Although uncommon, bilateral herpetic uveitis should always be considered in the differential diagnoses, when patients present with hypertensive uveitis in both eyes.



Authors and article citation: Khieu C, Kongyai N, Pathanapitoon K, Van Der Eijk AA, Rothova A. Causes of Hypertensive Anterior Uveitis in Thailand. Ocul Immunol Inflamm. 2020 May 18;28(4):559-565.

Year: 2019

Title: Causes of Hypertensive Anterior Uveitis in Thailand

Summary: PCR evidence of infection with herpes group viruses was found in one-third of patients with hypertensive anterior uveitis; CMV being the most common pathogen. The PCR-positive group generally responded well to a combination of antiviral and anti-glaucoma treatment.



Authors and article citation: Groen-Hakan F, Babu K, Tugal-Tutkun I, Pathanapithoon K, de Boer JH, Smith JR, de Groot-Mijnes JDF, Rothova A. Challenges of Diagnosing Viral Anterior Uveitis. *Ocul Immunol Inflamm.* 2017 Oct;25(5):710-720.

Year: 2017

Title: Challenges of Diagnosing Viral Anterior Uveitis

Summary: It is not clear which clinical presentations should raise a suspicion of viral etiology. There is an overlap in the clinical manifestations of AU caused by viruses and other non-viral forms of AU. A viral cause of AU should be suspected in patients with unilateral AU, exhibiting small or medium sized KPs, some form of iris atrophy, high IOP and early development of a cataract and the definitive diagnosis can be proven by aqueous humor analysis



Authors and article citation: Keorochana N, Treesit I, Funarunart P. Characteristics and Clinical Outcomes of Hypertensive Anterior Uveitis. *Ocul Immunol Inflamm.* 2020 May 18;28(4):538-548.

Year: 2019

Title: Characteristics and Clinical Outcomes of Hypertensive Anterior Uveitis

Summary: Viral infection was found in one half of hypertensive anterior uveitis. The complications of PCR- proven infectious case were more severe than PCR-negative case.



Authors and article citation: Wensing B, Mochizuki M, De Boer JH. Clinical Characteristics of Herpes Simplex Virus Associated Anterior Uveitis. *Ocul Immunol Inflamm.* 2018;26(3):333-337.

Year: 2018

Title: Clinical Characteristics of Herpes Simplex Virus Associated Anterior Uveitis

Summary: The clinical characteristics of HSV anterior uveitis can mimic other viral and non-infectious anterior uveitis entities especially at onset. Aqueous humor analysis for PCR and Goldmann–Witmer coefficient can be useful in case of suspected viral uveitis



Authors and article citation: Leleu I, Jhanji V, Touhami S, Westcott M, Angi M, Titah C, Rousseau A, Hamard P, Brasnu E, Manicom T, Blumen-Ohana E, Rozenberg F, Vauloup-Fellous C, Deback C, Labetoulle M, Sahel JA, Bodaghi B, Merabet L, Kobal A, Brignole-Baudouin F, Errera MH. Clinical Features and Diagnosis of Anterior Segment Inflammation Related to Cytomegalovirus in Immunocompetent African, Asian, and Caucasian Patients. *Ocul Immunol Inflamm.* 2019 Oct 23:1-9.

Year: 2019

Title: Clinical Features and Diagnosis of Anterior Segment Inflammation Related to Cytomegalovirus in Immunocompetent African, Asian, and Caucasian Patients

Summary: Features of Posner-Schlossman syndrome were observed in 50% of the eyes, Fuchs heterochromic iridocyclitis in 13% of the eyes, chronic nonspecific anterior uveitis in 21% of the eyes, and corneal endotheliitis in 18% of the eyes. No obvious association of specific clinical features with individual ethnicity could be identified. We found a high rate of glaucoma in all ethnic groups. There was a delay in diagnosis and specific treatment of HCMV in most patients.



Authors and article citation: Sakai JI, Usui Y, Suzuki J, Kezuka T, Goto H. Clinical features of anterior uveitis caused by three different herpes viruses. *Int Ophthalmol.* 2019 Dec;39(12):2785-2795.

Year: 2019

Title: Clinical features of anterior uveitis caused by three different herpes viruses

Summary: Clinical findings of HSV anterior uveitis and VZV anterior uveitis were similar; however, more inflammatory findings were observed in VZV anterior uveitis. Iris atrophy morphologically differed in HSV anterior uveitis and VZV anterior uveitis. Inflammatory findings in CMV anterior uveitis were mild, and clinical features of iritis differed from those of the two former groups. A difference in the etiology between CMV anterior uveitis and Posner Schlossman syndrome was observed.



Authors and article citation: Chan NS, Chee SP, Caspers L, Bodaghi B. Clinical Features of CMV-Associated Anterior Uveitis. *Ocul Immunol Inflamm.* 2018;26(1):107-115.

Year: 2017

Title: Clinical Features of CMV-Associated Anterior Uveitis

Summary: CMV anterior uveitis predominantly affects immuno-competent individuals, with a male to female ratio of slightly more than one in PSS and predominantly more males in chronic CMV anterior uveitis. It can present similarly to PSS as a recurrent acute hypertensive anterior uveitis, a chronic hypertensive anterior uveitis in Western patients or as FUS in Asian patients. Unlike HSV or VZV anterior uveitis, CMV anterior uveitis causes low grade anterior segment inflammation and mild ocular symptoms. It causes stromal iris atrophy but synechiae is absent. With recurrent or chronic disease, these eyes may develop severe glaucomatous optic neuropathy or cataract.



Authors and article citation: Sabhapandit S, Murthy SI, Balne PK, Sangwan VS, Sumanth V, Reddy AK. Clinical spectrum, diagnostic criteria, and polymerase chain reaction of aqueous humor in viral and toxoplasma detection in Fuchs' uveitis syndrome. *Indian J Ophthalmol.* 2016 Aug;64(8):555-8.

Year: 2016

Title: Clinical spectrum, diagnostic criteria, and polymerase chain reaction of aqueous humor in viral and toxoplasma detection in Fuchs' uveitis syndrome

Summary: This study shows that diagnosis of FU is mainly clinical. There appears to be no role of aqueous humor testing for viruses by PCR to aid in etiological diagnosis.



Authors and article citation: Touhami S, Qu L, Angi M, Bojanova M, Touitou V, Lehoang P, Rozenberg F, Bodaghi B. Cytomegalovirus Anterior Uveitis: Clinical Characteristics and Long-term Outcomes in a French Series. *Am J Ophthalmol.* 2018 Oct;194:134-142.

Year: 2018

Title: Cytomegalovirus Anterior Uveitis: Clinical Characteristics and Long-term Outcomes in a French Series.

Summary: Posner Schlossmann and chronic nonspecific AU were observed in 69.4% and 30.6% of cases respectively. They did not observe any case of Fuchs uveitis or endotheliitis. 94.2% of patients responded to the first line of therapy. Recurrence was reported in 73.5% of cases. Early initiation of antiviral therapy seems to reduce the severity of glaucoma.

Authors and article citation: Choi JA, Kim KS, Jung Y, Park HY, Park CK. Cytomegalovirus as a cause of hypertensive anterior uveitis in immunocompetent patients. *J Ophthalmic Inflamm Infect.* 2016 Dec;6(1):32.

Year: 2016

Title: Cytomegalovirus as a cause of hypertensive anterior uveitis in immunocompetent patients

Summary: CMV was found to be an etiological factor in patients with hypertensive anterior uveitis in Korea. Special caution is needed for patients with CMV-induced hypertensive anterior uveitis, considering its adverse effect on the corneal endothelium.



Authors and article citation: Chan NS, Chee SP. Demystifying viral anterior uveitis: A review. *Clin Exp Ophthalmol.* 2019 Apr;47(3):320-333.

Year: 2019

Title: Demystifying viral anterior uveitis: A review

Summary: There should be a high index of suspicion for a viral aetiology in any case of hypertensive AU or iris atrophy. Viral phenotypes include AU with granulomatous KPs with or without corneal scars; PSS-like uveitis and FUS-like uveitis. However, as each virus has variable clinical presentations and different viruses may also have overlapping manifestations, the preferred methods of confirming the aetiology are quantitative PCR or GWC assay of aqueous humour samples.



Authors and article citation: Relvas LJ, Caspers L, Chee SP, Zierhut M, Willermann F. Differential Diagnosis of Viral-Induced Anterior Uveitis. *Ocul Immunol Inflamm.* 2018;26(5):726-731.

Year: 2018

Title: Differential Diagnosis of Viral-Induced Anterior Uveitis

Summary: Pathogens, including viruses can use the eye as a reservoir and VIAU is probably the clinical consequence of this phenomenon. It is fascinating to observe that infection with different virus types, even from different families, leads to a common clinical expression such as central or paracentral KPs, corneal lesions, elevated IOP, and iris lesions. However, in this review, we have seen that despite Viral-Induced Anterior Uveitis having common clinical characteristics, a careful examination can give clues to differentiate between these viruses. Nonetheless, molecular biology and immunological techniques can help to establish a definitive diagnosis that may have important treatment consequences

Authors and article citation: Khairallah M, Mahendradas P, Curi A, Khochtali S, Cunningham ET Jr. Emerging Viral Infections Causing Anterior Uveitis. *Ocul Immunol Inflamm.* 2019;27(2):219-228.

Year: 2018

Title: Emerging Viral Infections Causing Anterior Uveitis

Summary: Proper clinical diagnosis of any emerging infectious disease is based on epidemiological data, history, systemic symptoms and signs, and the pattern of ocular involvement. The diagnosis is usually confirmed by detection of virus-specific DNA or antiviral antibodies in serum.



Authors and article citation: Hsiao YT, Kuo MT, Chiang WY, Chao TL, Kuo HK. Epidemiology and clinical features of viral anterior uveitis in southern Taiwan—diagnosis with polymerase chain reaction. *BMC Ophthalmol.* 2019 Apr 3;19(1):87.

Year: 2019

Title: Epidemiology and clinical features of viral anterior uveitis in southern Taiwan—diagnosis with polymerase chain reaction

Summary: PCR analysis of the anterior chamber fluid is important for the confirmation of the diagnosis of viral anterior uveitis. Cytomegalovirus anterior uveitis is not uncommon in patients in southern Taiwan, and it may follow an uneventful cataract extraction in immunocompetent patients.



Authors and article citation: Kreps EO, Derveaux T, De Keyser F, Kestelyn P. Fuchs' Uveitis Syndrome: No Longer a Syndrome? *Ocul Immunol Inflamm.* 2016 Jun;24(3):348-57.

Year: 2015

Title: Fuchs' Uveitis Syndrome: No Longer a Syndrome?

Summary: RV is the leading cause of FUS. Cytokine-based findings mirror a viral etiology and chronic low- grade inflammation. RV-associated FUS represents a common pathway of intraocular RV inoculation after congenital or acquired infection. Other causes, including HSV and CMV, may lead to FUS.

Authors and article citation: Tugal-Tutkun I, Cimino L, Akova YA. Review for Disease of the Year: Varicella Zoster Virus-Induced Anterior Uveitis. *Ocul Immunol Inflamm.* 2018;26(2):171-177.

Year: 2017

Title: Review for Disease of the Year: Varicella Zoster Virus-Induced Anterior Uveitis

Summary: Unilateral anterior uveitis associated with a typical skin eruption of HZO or a history of HZO does not present a diagnostic challenge. In the absence of such an association, VZV AU should be considered especially in older individuals who present with characteristic features of unilateral viral AU, such as granulomatous keratic precipitates, focal iris atrophy, and ocular hypertension. A definitive diagnosis of VZV AU can only be made by aqueous humor analysis. The disease course may be uniphasic or chronic relapsing. Patients have a favorable visual prognosis following treatment with systemic antiviral agents and topical corticosteroids



Authors and article citation: Accorinti M, Petitti L, Gaeta A, Giannini D, De Geronimo D. Viral Acute Anterior Uveitis: Clinical Signs Useful for Differential Diagnosis. *Ocul Immunol Inflamm.* 2020 May 14:1-8.

Year: 2020

Title: Viral Acute Anterior Uveitis: Clinical Signs Useful for Differential Diagnosis

Summary: Unilaterality, IOP \geq 24 mmHg and iris atrophy are significant predictors of possible viral etiology in AAU.



Authors and article citation: de-la-Torre A. Virus-Induced Anterior Uveitis (VIAU) in Immunocompromised Patients. *Ocul Immunol Inflamm.* 2018;26(5):807-817.

Year: 2018

Title: Virus-Induced Anterior Uveitis (VIAU) in Immunocompromised Patients

Summary: Frequent ocular examinations are recommended in HIV patients with CD-4 counts below 100 in order to rule out opportunistic ocular coinfections. It is essential to bear in mind the potential side-effects of therapeutic interventions and consider the possibility of Immune Recovery Uveitis (IRU) in eyes with treated viral retinitis after the initiation of HAART. Early diagnosis and treatment of VIAU in immunocompromised patients can be achieved with high suspicion, recognizing clinical features, and obtaining specimens for molecular diagnostic testing in order to avoid usually severe ocular morbidity.

Complications

Authors and article citation: Hoeksema L, Jansonius NM, Los LI. Risk Factors for Secondary Glaucoma in Herpetic Anterior Uveitis. *Am J Ophthalmol.* 2017 Sep;181:55-60.

Year: 2017

Title: Risk Factors for Secondary Glaucoma in Herpetic Anterior Uveitis

Summary: A risk factor for the development of glaucoma was the number of endured IOP peaks. Future studies are needed to evaluate whether early and prolonged use of antiviral and IOP- lowering medication may prevent glaucoma.



Authors and article citation: Murata K, Ishida K, Ozawa K, Sawada A, Mochizuki K, Yamamoto T. The characteristics of Posner-Schlossman syndrome: A comparison in the surgical outcome between cytomegalovirus-positive and cytomegalovirus-negative patients. *Medicine (Baltimore).* 2019 Nov;98(48):e18123.

Year: 2019

Title: The characteristics of Posner-Schlossman Syndrome - A comparison in the surgical outcome between cytomegalovirus-positive and cytomegalovirus-negative patients

Summary: CMV-positive PSS patients required more glaucoma surgeries than CMV-negative patients. Long-lasting PSS causes a decrease in BCVA, MD, and CEC density. A prompt diagnosis and appropriate treatment is required in PSS patients to improving their prognosis. For PSS patients who develop uncontrolled glaucoma, both Trabeculectomy and trabeculotomy may be effective to control IOP.



Authors and article citation: Hong Y, Wang M, Wu L. In vivo Confocal Microscopy of Posner-Schlossman Syndrome: Comparison with herpes simplex keratitis, HLA-B27 anterior uveitis and acute attack of primary angle closure. *Sci Rep.* 2017 Aug 29;7(1):9832.

Title: In vivo Confocal Microscopy of Posner-Schlossman Syndrome: Comparison with herpes simplex keratitis, HLA-B27 anterior uveitis and acute attack of primary angle closure

Summary: study showed the In vivo Confocal Microscopy(IVCM) findings of PSS patients and compared them with those of patients with HSK, patients with B27AU and patients with aPAC. There were Langerhans cells and keratocyte activation in many eyes with PSS, which was similar to what was observed in eyes with HSK. The IVCM findings also demonstrated that different types of KPs were present in PSS patients. Such findings indicate that the corneal activation of the PSS patients might have a relationship with a viral infection.

Authors and article citation: Pohlmann D, Pahlitzsch M, Schlickeiser S, Metzner S, Lenglinger M, Bertelmann E, Maier AB, Winterhalter S, Pleyer U. Virus-associated anterior uveitis and secondary glaucoma: Diagnostics, clinical characteristics, and surgical options. PLoS One. 2020 Feb 24;15(2):e0229260.

Year: 2019

Title: Virus-associated anterior uveitis and secondary glaucoma: Diagnostics, clinical characteristics, and surgical options

Summary: We conclude that different virus entities in anterior uveitis present specific risks for the development of glaucoma as well as necessary surgery. MIGS can be suggested as first-line-treatment in individual cases, however, the device needs to be carefully chosen by experienced specialists based on the individual needs of the patient. Filtrating glaucoma surgery can be recommended in VAU as an effective therapy to reduce the IOP over a longer period of time.



Authors and article citation: Hoeksema L, Los LI. Visual Prognosis and Ocular Complications in Herpetic versus HLA-B27- or Ankylosing Spondylitis-associated Anterior Uveitis. Ocul Immunol Inflamm. 2016 Jun;24(3):302-12.

Year: 2015

Title: Visual Prognosis and Ocular Complications in Herpetic versus HLA-B27- or Ankylosing Spondylitis-associated Anterior Uveitis

Summary: The most prominent finding was a worse visual prognosis in herpetic AU, which is probably related to higher prevalence of corneal scarring and glaucoma. In addition, herpetic AU patients have more ocular complications overall.



Treatment

Authors and article citation: Zandi S, Bodaghi B, Garweg JG. Review for Disease of the Year: Treatment of Viral Anterior Uveitis: A Perspective. *Ocul Immunol Inflamm.* 2018;26(7):1135-1142.

Year: 2018

Title: Review for Disease of the Year: Treatment of Viral Anterior Uveitis: A Perspective

Summary: Oral acyclovir, valacyclovir, and famciclovir are the mainstay of treatment for HSV- and VZV- induced infections. Brivudin serves as an alternative in insufficiently responsive cases. CMV-induced infections respond well to valganciclovir. A 3- to 12-month course of prophylactic treatment against recurrences is worth considering.



Authors and article citation: Choi JA, Kim JE, Ju HH, Lee J, Jee D, Park CK, Paik SY. The effects of losartan on cytomegalovirus infection in human trabecular meshwork cells. *PLoS One.* 2019 Jun 19;14(6):e0218471.

Year: 2019

Title: The effects of losartan on cytomegalovirus infection in human trabecular meshwork cells

Summary: Losartan inhibited the expression of TGF- β 1 and fibrogenic molecules in human TM cells. Thus, losartan has the potential to decrease TM fibrosis in patients with CMV-induced hypertensive anterior uveitis.



Authors and article citation: Antoun J, Willermain F, Makhoul D, Motulsky E, Caspers L, Relvas LJ. Topical Ganciclovir in Cytomegalovirus Anterior Uveitis. *J Ocul Pharmacol Ther.* 2017 May;33(4):313-318.

Year: 2017

Title: Topical Ganciclovir in Cytomegalovirus Anterior Uveitis

Summary: Patients treated with 0.15% topical ganciclovir have a decreased frequency of CMV anterior uveitis recurrences, most preserve a relatively good central vision over time. However, glaucoma is a frequent and severe complication.

Posterior uveitis Clinical features

Authors and article citation: Goldhardt R, Patel H, Davis JL. Acute Posterior Multifocal Placoid Pigment Epitheliopathy Following Dengue Fever: A New Association for an Old Disease. *Ocul Immunol Inflamm.* 2016 Dec;24(6):610-614.

Year: 2016

Title: Acute Posterior Multifocal Placoid Pigment Epitheliopathy Following Dengue Fever: A New Association for an Old Disease

Summary: APMPE may be another manifestation of dengue fever. Ophthalmologists should take travel histories and consider ordering dengue serology in appropriate patients with APMPE even if fever is absent, and especially in patients with the possibility of attenuated systemic disease and a primarily immunologic reaction to subsequent exposure.



Authors and article citation: Okafor K, Lu J, Thinda S, Schwab I, Morse LS, Park SS, Moshiri A. Acute Retinal Necrosis Presenting in Developmentally-delayed Patients with Neonatal Encephalitis: A Case Series and Literature Review. *Ocul Immunol Inflamm.* 2017 Aug;25(4):563-568.

Year: 2016

Title: Acute Retinal Necrosis Presenting in Developmentally-delayed Patients with Neonatal Encephalitis: A Case Series and Literature Review

Summary: All patients with a history of herpetic neonatal encephalitis who present with a red eye should be presumed to have acute retinal necrosis until proven otherwise. Early diagnosis with a low threshold for an examination under anesthesia, diagnostic vitrectomy, and lumbar punctures are imperative to ensure a correct diagnosis. Clinicians should consider indefinite prophylactic antiviral therapy when patients with a history of neonatal herpetic infection involving the central nervous system present with poor vision unilaterally.



Authors and article citation: Hedayatfar A, Ebrahimiadib N, Zarei M, Ashraf Khorasani M, Mahbod M, Asgari S, Sedaghat A. Acute retinal necrosis: Clinical manifestation and long-term visual outcomes in a series of polymerase chain reaction-positive patients. *Eur J Ophthalmol.* 2020 Jun 21:1120672120936181.

Year: 2020

Title: Acute retinal necrosis: Clinical manifestation and long-term visual outcomes in a series of polymerase chain reaction-positive patients

Summary: VZV was detected in 78.0% of ARN eyes. 61.1% of eyes experienced RRD. The median time for the occurrence of RRD was 12 weeks (range: 6–25 weeks) after disease onset. Aqueous PCR results are highly consistent with the clinical diagnosis of ARN. Regardless of the method of management, the rate of RRD is high and is associated with a poor visual outcome.

Authors and article citation: Miserochi E, Iuliano L, Fogliato G, Modorati G, Couto C, Schlaen A, Hurtado E, Llorenç V, Adan A, Bandello F. Bilateral Acute Retinal Necrosis: Clinical Features and Outcomes in a Multicenter Study. *Ocul Immunol Inflamm.* 2019;27(7):1090-1098.

Year: 2018

Title: Bilateral Acute Retinal Necrosis: Clinical Features and Outcomes in a Multicenter Study

Summary: Bilateral acute retinal necrosis was associated with severe visual outcome and high rate of ocular complications. Although Bilateral acute retinal necrosis is a rare disease, the course is aggressive, regardless prompt referral in tertiary-care uveitis centres.



Authors and article citation: Agarwal A, Invernizzi A, Jain S, Acquistapace A, Riva A, Sharma A, Gupta V, Singh R. Choroidal Thickness in Patients Diagnosed with Human Immunodeficiency Virus Infection: Results from Two Populations of Different Ethnicities. *Ocul Immunol Inflamm.* 2019;27(4):560-566.

Year: 2018

Title: Choroidal Thickness in Patients Diagnosed with Human Immunodeficiency Virus Infection: Results from Two Populations of Different Ethnicities

Summary: Patients with HIV infection, especially with HIV microangiopathy, have thicker choroid compared to age- and gender-matched healthy control subjects. These changes may be related to HIV-associated choroidal vascular dysfunction.



Authors and article citation: Souissi S, Fardeau C, Le HM, Rozenberg F, Bodaghi B, Le Hoang P. Chronic Herpetic Retinitis: Clinical Features and Long-Term Outcomes. *Ocul Immunol Inflamm.* 2018;26(1):94-103.

Year: 2017

Title: Chronic Herpetic Retinitis: Clinical Features and Long-Term Outcomes

Summary: Recurrent granulomatous uveitis associated, at the time of the first examination, with pigmented atrophic retinal lesions could be related to an intraocular herpetic replication in immunocompetent patients. In such clinical forms, a specific antiherpetic treatment could help to preserve visual acuity when the macular area is not impaired by the atrophic lesion. This description should be added to the broad repertoire of clinical polymorphisms associated with herpetic ocular infection.



Authors and article citation: Calvo CM, Khan MA, Mehta S, Garg SJ, Dunn JP. Correlation of Clinical Outcomes with Quantitative Polymerase Chain Reaction DNA Copy Number in Patients with Acute Retinal Necrosis. *Ocul Immunol Inflamm.* 2017 Apr;25(2):246-252.

Year: 2016

Title: Correlation of Clinical Outcomes with Quantitative Polymerase Chain Reaction DNA Copy Number in Patients with Acute Retinal Necrosis

Summary: Anterior chamber fluid Quantitative DNA copy number of $\geq 5.0 \times 10^6/\text{mL}$ is associated with more extensive retinitis, worse visual acuity, and development of retinal detachment in patients with acute retinal necrosis.



Authors and article citation: Port AD, Orlin A, Kiss S, Patel S, D'Amico DJ, Gupta MP. Cytomegalovirus Retinitis: A Review. *J Ocul Pharmacol Ther.* 2017 May;33(4):224-234.

Year: 2017

Title: Cytomegalovirus Retinitis: A Review

Summary: The diagnosis is generally a clinical one, and treatment modalities include systemic and in-travitreal antiviral medications. Retinal detachment and immune recovery uveitis are sight-threatening complications of CMV retinitis that require specific treatments.



Authors and article citation: Kawali A, Mahendradas P, Mohan A, Mallavarapu M, Shetty B. Epidemic Retinitis. *Ocul Immunol Inflamm.* 2019;27(4):571-577.

Year: 2018

Title: Epidemic Retinitis

Summary: We suggest a term “Epidemic Retinitis” for RpFI due to its seasonal variation and to differentiate it from other sporadic forms of retinitis. Although RpFI has aggressive presentation, it resolves over 3–4 months and the overall visual outcome is satisfactory.



Authors and article citation: Wons J, Kempen J, Garweg JG. HIV-induced Retinitis. *Ocul Immunol Inflamm.* 2020 Sep 23:1-10.

Year: 2020

Title: HIV-induced Retinitis

Summary: Targeted antiviral treatment and secondary recurrence prophylaxis prevent vision loss of the retina prior to immune recovery. have dramatically decreased under ART, immune restoration has led to immunologic restoration-related retinal findings such as IRU after recovery from CMV retinitis and inherent drug toxicities still limit the long-term visual prognosis in many affected individuals.



Authors and article citation: Yang CS, Hsieh MH, Su HI, Kuo YS. Multiple Evanescent White Dot Syndrome Following Acute Epstein-Barr Virus Infection. *Ocul Immunol Inflamm.* 2019;27(2):244-250.

Year: 2017

Title: Multiple Evanescent White Dot Syndrome following Acute Epstein-Barr Virus Infection

Summary: MEWDS may be associated with acute systemic EB virus infection. Ocular symptoms might develop due to this infection or represent virus-induced autoimmune inflammatory retinitis.



Authors and article citation: Tsui I, Neves LM, Adachi K, Gaw SL, Pereira JP Jr, Brasil P, Nielsen-Saines K, Moreira MEL, Zin AA. Overlapping Spectrum of Retinochoroidal Scarring in Congenital Zika Virus and Toxoplasmosis Infections. *Ophthalmic Surg Lasers Imaging Retina.* 2019 Dec 1;50(12):779-784.

Year: 2019

Title: Overlapping Spectrum of Retinochoroidal Scarring in Congenital Zika Virus and Toxoplasmosis Infections

Summary: As children infected with congenital ZIKV grow older, subclinical eye abnormalities may be indistinguishable from toxoplasmosis.



Authors and article citation: Benito-Pascual B, Gegúndez JA, Díaz-Valle D, Arriola-Villalobos P, Carreño E, Culebras E, Rodríguez-Avial I, Benitez-Del-Castillo JM. Panuveitis and Optic Neuritis as a Possible Initial Presentation of the Novel Coronavirus Disease 2019 (COVID-19). Ocul Immunol Inflamm. 2020 Aug 17;28(6):922-925.

Year: 2020

Title: Panuveitis and Optic Neuritis as a Possible Initial Presentation of the Novel Coronavirus Disease 2019 (COVID-19)

Summary: panuveitis and optic neuritis could be initial features of SARS-CoV-2 infection, but this remains as a hypothesis. Further studies are warranted to properly describe all the systemic manifestations of SARS- CoV-2



Viral uveitis -General Pathophysiology

Authors and article citation: Fazil Z, Ten Berge JC, Langerak AW, Rothova A, Dik WA. An Intraocular Inflammatory Profile of Rubella Associated Uveitis. *Ocul Immunol Inflamm.* 2019;27(3):418-423.

Year: 2018

Title: An Intraocular Inflammatory Profile of Rubella Associated Uveitis

Summary: Rubella Associated Uveitis patients exhibited high intraocular levels of MCP-1, IL-6 α , and TARC, whilst patients with noninfectious uveitis were characterized by high levels of PlGF. Cataract patients showed high levels of IL-2 and IL-23. Intraocular cell population of RVU patients disclosed mainly T-cells and monocytes/macrophages and B-cells were scarcely detected.



Authors and article citation: Spekker-Bosker K, Ufermann CM, Maywald M, Zimmermann A, Domröse A, Woite C, Däubener W, Eller SK. hCMV-Mediated Immune Escape Mechanisms Favor Pathogen Growth and Disturb the Immune Privilege of the Eye. *Int J Mol Sci.* 2019 Feb 16;20(4):858.

Year: 2019

Title: hCMV-Mediated Immune Escape Mechanisms Favor Pathogen Growth and Disturb the Immune Privilege of the Eye

Summary: An active human CMV infection in the eye might favour the replication of pathogens causing co-infections in immunosuppressed individuals. An human CMV caused blockade of indoleamine 2,3-dioxygenase-1 might weaken the eye's immune privilege and favor the development of post-infectious autoimmune uveitis.



Authors and article citation: Oliver GF, Orang AV, Appukuttan B, Marri S, Michael MZ, Marsh GA, Smith JR. Expression of microRNA in human retinal pigment epithelial cells following infection with Zaire ebolavirus. *BMC Res Notes.* 2019 Oct 1;12(1):639.

Year: 2019

Title: Expression of microRNA in human retinal pigment epithelial cells following infection with Zaire ebolavirus

Summary: This work provides new information about the potential post-transcriptional regulation of the human RPE cell response to infection with EBOV. Future studies of the regulatory activities of these miRNAs in human RPE cells should delineate their involvement in the intraocular persistence of EBOV and EBOV-associated uveitis in EVD survivors.

Authors and article citation: Williams-Wietzikoski CA, So ID, Bull ME, Samleerat T, Pathanapitton K, Kunavisarut P, Kongyai N, Ngo-Giang-Huong N, Frenkel LM, Sirirungsi W. Genetic analyses of HIV env associated with uveitis in antiretroviral-naive individuals. *AIDS*. 2017 Aug 24;31(13):1825-1830.

Year: 2017

Title: Genetic analyses of HIV env associated with uveitis in antiretroviral-naïve individuals

Among ARV-naïve individuals with uveitis attributed to HIV, the universal compartmentalization and decreased diversity of eye compared to blood sequences suggests time-limited passage of a small subset of variants from each subject's viral population into the eye tissues, followed by limited immune selection despite the inflammatory uveitis.



Authors and article citation: Zhu S, Luo H, Liu H, Ha Y, Mays ER, Lawrence RE, Winkelmann E, Barrett AD, Smith SB, Wang M, Wang T, Zhang W. p38MAPK plays a critical role in induction of a pro-inflammatory phenotype of retinal Müller cells following Zika virus infection. *Antiviral Res*. 2017 Sep;145:70-81.

Year: 2017

Title: p38MAPK plays a critical role in induction of a pro-inflammatory phenotype of retinal Müller cells following Zika virus infection

Summary: Data suggest that Müller cells play an important role in ZIKV-induced ocular pathology by induction of inflammatory and growth factors in which the p38MAPK pathway has a central role. Blocking p38MAPK may provide a novel approach to control ZIKV-induced ocular inflammation.



Authors and article citation: Smith JR, Todd S, Ashander LM, Charitou T, Ma Y, Yeh S, Crozier I, Michael MZ, Appukuttan B, Williams KA, Lynn DJ, Marsh GA. Retinal Pigment Epithelial Cells are a Potential Reservoir for Ebola Virus in the Human Eye. *Transl Vis Sci Technol*. 2017 Jul 14;6(4):12.

Year: 2017

Title: Retinal Pigment Epithelial Cells are a Potential Reservoir for Ebola Virus in the Human Eye

Summary: Human retinal pigment epithelial cells may serve as an intraocular reservoir for EBOV, and the molecular response of infected cells may contribute to the persistence of live EBOV within the human eye.

Diagnostics

Authors and article citation: Chronopoulos A, Roquelaure D, Souteyrand G, Seebach JD, Schutz JS, Thumann G. Aqueous humor polymerase chain reaction in uveitis - utility and safety. *BMC Ophthalmol.* 2016 Oct 28;16(1):189.

Year: 2016

Title: Aqueous humor polymerase chain reaction in uveitis – utility and safety

Summary: The overall PCR positivity was 48.9 %. Aqueous PCR altered the diagnosis and treatment in over a third of our patients and was relatively safe. Aqueous PCR should be considered for uveitis of atypical clinical appearance, recurrent severe uveitis of uncertain etiology, and therapy refractory cases.



Authors and article citation: Kumar A, Singh MP, Bansal R, Gupta A, Ram J, Ratho RK. Development and evaluation of multiplex real-time PCR for diagnosis of HSV-1, VZV, CMV, and *Toxoplasma gondii* in patients with infectious uveitis. *Diagn Microbiol Infect Dis.* 2017 Nov;89(3):191-196.

Year: 2017

Title: Development and evaluation of multiplex real-time PCR for diagnosis of HSV-1, VZV, CMV, and *Toxoplasma gondii* in patients with infectious uveitis

Summary: The in-house multiplex real-time PCR was found to be highly sensitive, specific and had the ability to pick up common viral agents and *Toxoplasma* in approximately 26% of the patients. It had high reproducibility and can be useful for the determination of pathogen load in prospective studies. The ability for early diagnosis using multiplex real-time PCR can be helpful in early treatment initiation thereby preventing the damage to the ocular structures.



Authors and article citation: Miyazaki D, Shimizu D, Shimizu Y, Inoue Y, Inoue T, Higaki S, Ueta M, Sugita S; Real-time PCR for ocular cytomegalovirus infection study group. Diagnostic efficacy of real-time PCR for ocular cytomegalovirus infections. *Graefes Arch Clin Exp Ophthalmol.* 2018 Dec;256(12):2413-2420.

Year: 2018

Title: Diagnostic efficacy of real-time PCR for ocular cytomegalovirus infections

Summary: Quantitative PCR with standardization is specific and accurate; however, the inclusion and knowledge of the clinical characteristics improve the diagnostic efficacy.

Authors and article citation: Nakano S, Tomaru Y, Kubota T, Takase H, Mochizuki M, Shimizu N, Sugita S; Strip PCR Project Group. Evaluation of a Multiplex Strip PCR Test for Infectious Uveitis: A Prospective Multicenter Study. *Am J Ophthalmol.* 2020 May;213:252-259.

Year: 2019

Title: Evaluation of a multiplex Strip PCR test for infectious uveitis: a prospective multicenter study

Summary: Easy-to-use Strip PCR is recommended for rapid diagnosis of infectious uveitis as its results are equivalent to that of conventional qPCR.



Authors and article citation: Smit DP, Meyer D, Esterhuizen TM, De Groot-Mijnes JDF. Polymerase Chain Reaction and Goldmann-Witmer Coefficient Testing in the Diagnosis of Infectious Uveitis in HIV-Positive and HIV-Negative Patients in South Africa. *Ocul Immunol Inflamm.* 2019;27(2):189-196.

Year: 2017

Title: Polymerase Chain Reaction and Goldmann-Witmer Coefficient Testing in the Diagnosis of Infectious Uveitis in HIV-positive and HIV-negative Patients in South Africa

Summary: PCR is useful to diagnose herpetic NAU in HIV+ patients while GWC is useful to diagnose herpetic anterior uveitis.



Authors and article citation: Selvaraj JR, Sudharshan S, Therese LK, Janani MK, Selvamuthu P, Rewri P, Biswas J. Real-time polymerase chain reaction for diagnosis and management of HIV-induced uveitis. *Indian J Ophthalmol.* 2018 Nov;66(11):1634-1636.

Year: 2018

Title: Real-time polymerase chain reaction for diagnosis and management of HIV-induced uveitis

Summary: In contrast to immune related uveitis where the HAART increases the symptoms and flares up the inflammation, HAART brings down the inflammation in HIV-induced uveitis. RT PCR for HIV RNA in HIV-induced uveitis will not only serve as a diagnostic tool but can be a guide to treatment.

Clinical features

Authors and article citation: Shantha JG, Crozier I, Yeh S. An update on ocular complications of Ebola virus disease. *Curr Opin Ophthalmol*. 2017 Nov;28(6):600-606.

Year: 2017

Title: An update on ocular complications of Ebola virus disease

Summary: Uveitis is the most common ophthalmic finding in Ebola virus disease survivors and can lead to vision loss. Further studies into the clinical manifestations and mechanisms of disease are needed to improve therapies for Ebola virus disease survivors.



Authors and article citation: Seah I, Agrawal R. Can the Coronavirus Disease 2019 (COVID-19) Affect the Eyes? A Review of Coronaviruses and Ocular Implications in Humans and Animals. *Ocul Immunol Inflamm*. 2020 Apr 2;28(3):391-395.

Year: 2020

Title: Can the Coronavirus Disease 2019 (COVID-19) Affect the Eyes? A Review of Coronaviruses and Ocular Implications in Humans and Animals

Summary: Firstly, CoVs are capable of producing a wide spectrum of ocular manifestations from anterior segment pathologies like conjunctivitis and anterior uveitis to sight-threatening conditions like retinitis and optic neuritis. Secondly, it may also be prudent to recognize that CoVs can also develop in-vivo mutations which drastically alter the manifestations of the disease. Given the anecdotal nature of evidence regarding SARS-CoV-2 transmission through ocular tissue, more research has to be done to confirm its ability to infect ocular tissue and its pathogenic mechanisms



Authors and article citation: Yeh S, Shantha JG, Hayek B, Crozier I, Smith JR. Clinical Manifestations and Pathogenesis of Uveitis in Ebola Virus Disease Survivors. *Ocul Immunol Inflamm*. 2018;26(7):1128-1134.

Year: 2018

Title: Clinical Manifestations and Pathogenesis of Uveitis in Ebola Virus Disease Survivors

Summary: Ophthalmic manifestations in Ebola virus disease survivors include a spectrum of disease ranging from anterior uveitis to panuveitis. Ocular inflammation recently observed in EVD survivors is thought to involve direct viral infection, inflammation, and tissue edema. Future research is needed to understand the timing of uveitis onset and management strategies, including the role of antiviral and anti-inflammatory therapies.

Authors and article citation: Groen-Hakan F, van de Laar S, van der Eijk-Baltissen AA, Ten Dam-van Loon N, de Boer J, Rothova A. Clinical Manifestations, Prognosis, and Vaccination Status of Patients With Rubella Virus-Associated Uveitis. *Am J Ophthalmol.* 2019 Jun;202:37-46.

Year: 2019

Title: Clinical Manifestations, Prognosis, and Vaccination Status of Patients With Rubella Virus-Associated Uveitis

Summary: RV-associated uveitis and FUS are not exchangeable. Chronic anterior uveitis, vitritis, early development of cataract, and the absence of posterior synechiae and CME characterize RV-associated uveitis. Almost all FUS cases had documented intraocular RV infection, but only some of the patients with RV-associated uveitis presented with FUS.



Authors and article citation: Babu K, Mahendradas P, Sudheer B, Kawali A, Parameswarappa DC, Pal V, Philips M. Clinical Profile of Herpes Zoster Ophthalmicus in a South Indian Patient Population. *Ocul Immunol Inflamm.* 2018;26(2):178-183.

Year: 2017

Title: Clinical Profile of Herpes Zoster Ophthalmicus in a South Indian Patient Population

Summary: Anterior uveitis with or without keratitis was the most common presentation observed in more than 50% cases. The overall visual outcome was good.



Authors and article citation: Shantha JG, Mattia JG, Goba A, *et al.*. Ebola Virus Persistence in Ocular Tissues and Fluids (EVICT) Study: Reverse Transcription-Polymerase Chain Reaction and Cataract Surgery Outcomes of Ebola Survivors in Sierra Leone. *EBioMedicine.* 2018 Apr;30:217-224.

Year: 2018

Title: Ebola Virus Persistence in Ocular Tissues and Fluids (EVICT) Study: Reverse Transcription-Polymerase Chain Reaction and Cataract Surgery Outcomes of Ebola Survivors in Sierra Leone

Summary: Ebola virus persistence by RT-PCR was not identified in ocular fluid or conjunctivae of fifty EVD survivors with ocular disease. Cataract surgery can be performed safely with vision restorative outcomes in patients who test negative for Ebola virus RNA in ocular fluid specimens. These findings impact the thousands of West African EVD survivors at-risk for ocular complications who may also require eye surgery during EVD convalescence.

Authors and article citation: Oliver GF, Carr JM, Smith JR. Emerging infectious uveitis: Chikungunya, dengue, Zika and Ebola: A review. Clin Exp Ophthalmol. 2019 Apr;47(3):372-380.

Year: 2018

Title: Emerging infectious uveitis: Chikungunya, dengue, Zika and Ebola—A review

Summary: While molecular biological testing, including RT-PCR and immunoassays, are providing reliable means to diagnose the emerging viral forms of uveitis, treatment of these conditions continues to be challenging. Corticosteroid therapies may be effective in limiting the inflammation. However, knowledge that the uveitis may reflect the presence of virus within the eye means decisions around timing of such treatment in the absence of specific anti-viral treatment are difficult. Understanding how these viruses access, replicate and persist within, and finally are cleared from the eye may provide a useful basis for specific medical approaches to these diseases.



Authors and article citation: Cunningham ET Jr, Khairallah M, Rathinam SR, Belfort R Jr, Zierhut M. Mosquito-Borne Uveitis. Ocul Immunol Inflamm. 2018;26(5):651-653.

Year: 2018

Title: Mosquito-Borne Uveitis

Summary: Conjunctivitis and anterior uveitis are the most common findings, posterior segment involvement may also occur, including vitritis, retinal vasculitis, retinochoroiditis, serous retinal detachment, and involvement of the RPE. Undoubtedly, other ocular complications will be described – including complications caused by arboviruses not yet reported to affect the eye or cause ocular inflammation



Authors and article citation: Capretti MG, Marsico C, Guidelli Guidi S, Ciardella A, Simonazzi G, Galletti S, Gabrielli L, Lazzarotto T, Faldella G. Neonatal and long-term ophthalmological findings in infants with symptomatic and asymptomatic congenital cytomegalovirus infection. J Clin Virol. 2017 Dec;97:59-63.

Year: 2017

Title: Neonatal and long-term ophthalmological findings in infants with symptomatic and asymptomatic congenital cytomegalovirus infection

Summary: Ophthalmological abnormalities were common in symptomatic infants though often not associated with long-term visual impairment, and correlated with the presence of CNS involvement. Neonatal and peri-odical ophthalmological evaluations throughout childhood seem prudential for symptomatic babies. No ophthalmological abnormalities were detected in asymptomatic infants, who might therefore undergo more deferred evaluations.

Authors and article citation: Joye A, Gonzales JA. Ocular manifestations of cytomegalovirus in immunocompetent hosts. *Curr Opin Ophthalmol.* 2018 Nov;29(6):535-542.

Year: 2018

Title: Ocular manifestations of cytomegalovirus in immunocompetent hosts

Summary: Intraocular reactivation, replication, and invasion of the trabecular meshwork and endothelium lead to recurrent bouts of ocular hypertension and endothelial cell loss, the complications of which may be tempered with initiation of antivirals. Topical ganciclovir is a promising therapy that needs investigation. CMV retinitis, an entity previously believed isolated to the severely immunosuppressed population, has been reported on numerous occasions in presumably immunocompetent individuals, particularly following local steroid injections. Further studies may elucidate the pathogenesis of CMV in immunocompetent populations.



Authors and article citation: Martínez-Pulgarín DF, Chowdhury FR, Villamil-Gomez WE, Rodriguez-Morales AJ, Blohm GM, Paniz-Mondolfi AE. Ophthalmologic aspects of chikungunya infection. *Travel Med Infect Dis.* 2016 Sep-Oct;14(5):451-457.

Year: 2016

Title: Ophthalmologic aspects of chikungunya infection

Summary: Ocular manifestations of chikungunya fever are not frequent, but of great relevance. Common manifestations include conjunctivitis, optic neuritis, iridocyclitis, episcleritis, retinitis and uveitis. Diagnostic and monitoring investigations would include optical coherence tomography, fundus fluorescein and indocyanine green angiography, visual field analysis, and electrophysiologic tests.



Authors and article citation: Ventura CV, Maia M, Travassos SB, Martins TT, Patriota F, Nunes ME, Agra C, Torres VL, van der Linden V, Ramos RC, Rocha MÂ, Silva PS, Ventura LO, Belfort R Jr. Risk Factors Associated With the Ophthalmoscopic Findings Identified in Infants With Presumed Zika Virus Congenital Infection. *JAMA Ophthalmol.* 2016 Aug 1;134(8):912-8.

Year: 2016

Title: Risk Factors Associated With the Ophthalmoscopic Findings Identified in Infants With Presumed Zika Virus Congenital Infection

Summary: Ocular involvement in infants with presumed ZIKV congenital infection were more often seen in infants with smaller cephalic diameter at birth and in infants whose mothers reported symptoms during the first trimester.

Authors and article citation: Nakao K, Abematsu N, Sakamoto T. Systemic diseases in patients with HTLV-1-associated uveitis. *Br J Ophthalmol.* 2018 Mar;102(3):373-376.

Year: 2017

Title: Systemic diseases in patients with HTLV-1- associated uveitis

Summary: HTLV-1 carriers with HAU may develop HAM/TSP more frequently than general carriers. HTLV-1 carriers undergoing treatment for hyperthyroidism may be prone to developing HAU.



Authors and article citation: Kawali A, Mahendradas P, Sanjay S, Shetty R. Viral Kerato-Uveitis with Choroidal Vitiligo. *Ocul Immunol Inflamm.* 2020 Apr 7:1-4.

Year: 2020

Title: Viral Kerato-Uveitis with Choroidal Vitiligo

Summary: We presume multiple hypopigmented choroidal lesions are due to loss of melanin from choroidal melanocytes secondary to the VZV infection and propose a term “choroidal vitiligo” to describe these novel fundus findings.



Authors and article citation: Zhao Z, Yang M, Azar SR, Soong L, Weaver SC, Sun J, Chen Y, Rossi SL, Cai J. Viral Retinopathy in Experimental Models of Zika Infection. *Invest Ophthalmol Vis Sci.* 2017 Aug 1;58(10):4355–4365.

Year: 2017

Title: Viral Retinopathy in Experimental Models of Zika Infection

Summary: Our data suggest that ZIKV can infect infant eyes with immature blood–retinal barrier and cause structural damages to the retina. The ocular findings in microcephalic infants may not be solely caused by ZIKV-induced impairment of neurodevelopment.

Authors and article citation: De Paula Freitas B, Ventura CV, Maia M, Belfort R Jr. Zika virus and the eye. *Curr Opin Ophthalmol.* 2017 Nov;28(6):595-599.

Year: 2017

Title: Zika virus and the eye

Summary: Infants with congenital Zika syndrome might have vision-threatening fundus abnormalities. Although the full spectrum of ocular lesions caused by the ZIKV infection is not yet determined, a distinctive new disease has been observed. Recognition of these lesions by ophthalmologists can help ensure appropriate etiologic evaluation and clinical investigation to define the range of anomalies in an affected infant and determine essential follow-up and ongoing care.



Treatment

Authors and article citation: Boonsopon S, Maghsoudlou A, Kombo NE, Foster CS. A therapeutic trial of valganciclovir in patients with uveitis and positive Epstein-Barr virus early antigen D IgG titers. *Eur J Ophthalmol.* 2016 Jan-Feb;26(1):30-5.

Year: 2016

Title: A therapeutic trial of valganciclovir in patients with uveitis and positive Epstein-Barr virus early antigen D IgG titers

Summary: Uveitis can be caused by EBV infection/reactivation. A therapeutic trial with valganciclovir 450 mg twice a day for 1 month in patients with uveitis with positive EBV EA antibody may be beneficial.



Authors and article citation: Thomas AS, Lin P. Local treatment of infectious and noninfectious intermediate, posterior, and panuveitis: current concepts and emerging therapeutics. *Curr Opin Ophthalmol.* 2020 May;31(3):174-184.

Year: 2020

Title: Local treatment of infectious and noninfectious intermediate, posterior, and panuveitis: current concepts and emerging therapeutics

Summary: Local antivirals, such as foscarnet and ganciclovir, used in conjunction with systemic antivirals may provide superior outcomes to systemic antivirals alone in the management of viral retinitis.



Complications

Authors and article citation: Li AL, Berry DE, Shantha JG, Yeh S. Cataract management in Ebola virus disease survivors: clinical and scientific implications. *Future Virol.* 2019 Feb;14(2):55-59.

Year: 2019

Title: Cataract management in Ebola virus disease survivors: clinical and scientific implications

Summary: Cataract management remains a key issue in their long-term vision care. Results from the EVICT study showed that surgery can be safely performed to restore vision loss in Ebola virus disease (EVD) survivors, although a number of factors warrant consideration prior to surgery. Specifically, careful preoperative planning, ocular fluid sampling and infection control practices were paramount in the medical and surgical management of cataract in EVD survivors. As a consequence of the delayed timing of ocular fluid assessment of EVD survivors in the EVICT cohorts the true prevalence of ebola virus persistence in ocular fluid and dynamics of clearance require further investigation.



Authors and article citation: Schaftenaar E, Meenken C, Baarsma GS, McIntyre JA, Verjans GM, Peters RP. Early- and late-stage ocular complications of herpes zoster ophthalmicus in rural South Africa. *Trop Med Int Health.* 2016 Mar;21(3):334-9.

Year: 2016

Title: Early- and late-stage ocular complications of herpes zoster ophthalmicus in rural South Africa

Summary: HZO patients present with relatively late-stage ocular complications, and blindness among these patients is common. The delayed presentation to the ophthalmology outpatient department of hospitals in our rural setting is of concern, and efforts to improve ocular outcomes of HZO are urgently needed.



Authors and article citation: Choi JA, Kim JE, Noh SJ, Kyoung Kim E, Park CK, Paik SY. Enhanced cytomegalovirus infection in human trabecular meshwork cells and its implication in glaucoma pathogenesis. *Sci Rep.* 2017 Feb 27;7:43349.

Year: 2017

Title: Enhanced cytomegalovirus infection in human trabecular meshwork cells and its implication in glaucoma pathogenesis

Summary: The data presented in this study definitively demonstrate that human TM cells effectively support CMV replication. This suggests that active viral infection in human TM cells could be the key mechanism underlying the elevation of IOP in anterior viral uveitis (Fig. 9). Importantly, we demonstrated that CMV infection enhanced TGF- β 1 production in human TM cells and that this increase was countervailed by treatment with corticosteroids. This in vitro study provides a potential pathogenic mechanism for the observed associations between CMV infection and elevation of IOP in viral anterior uveitis.



Authors and article citation: Lu LM, McGhee CNJ, Sims JL, Niederer RL. High rate of recurrence of herpes zoster-related ocular disease after phacoemulsification cataract surgery. *J Cataract Refract Surg.* 2019 Jun;45(6):810-815.

Year: 2019

Title: High rate of recurrence of herpes zoster-related ocular disease after phacoemulsification cataract surgery

Summary: Phacoemulsification in eyes with previous herpes zoster-related keratitis or uveitis posed a mildly increased risk for intraoperative and postoperative complications; however, herpes zoster disease recurrence after surgery was common and was severe in some cases. Consideration should be given to maximizing the period of quiescence before surgery and the potential role of antiviral prophylaxis.



Authors and article citation: Touhami S, Vanier A, Rosati A, Bojanova M, Benromdhane B, Lehoang P, Rozenberg F, Bodaghi B. Predictive Factors of Intraocular Pressure Level Evolution Over Time and Glaucoma Severity in Fuchs' Heterochromic Iridocyclitis. *Invest Ophthalmol Vis Sci.* 2019 Jun 3;60(7):2399-2405.

Year: 2019

Title: Predictive Factors of Intraocular Pressure Level Evolution Over Time and Glaucoma Severity in Fuchs' Heterochromic Iridocyclitis

Summary: Time to diagnosis, male sex, presence of iris nodules at baseline, and decreased serum/aqueous humor ratio of RV IgGs (Crv) and control antiviral IgGs (Cctl) ratios were associated with increased likelihood of pejorative IOP evolution over time.



Antivirals In Ophthalmology: A Quick Look



Dr. Parthopratin Dutta Majumder

Senior Consultant

Department of Uvea & Intraocular
inflammation Medical Research Foundation,
Sankara Nethralaya, Chennai

Email: drparthopratin@gmail.com

Antivirals In Ophthalmology: A Quick Look

Antiviral drugs interfere with viral replication to stop virus multiplication. An ideal antiviral drug should inhibit viral replication while sparing host cell-directed nucleic acid or protein synthesis. Most of the currently available antiviral drugs are antimetabolites that inhibit nucleic acid synthesis. They target viral enzymes, such as thymidine kinase, to inhibit viral replication. Thymidine kinase helps by incorporating the nucleoside thymidine into DNA. Because thymidine is an integral building block of DNA, inhibiting thymidine kinase's action prevents DNA duplication. The more selective the antiviral agent is for viral enzymes, the less likely are host-side effects. In this write-up, an attempt was made to summarise the common antiviral agents used in ophthalmology. The anti-retroviral agents were not included in this write-up.

Idoxuridine

Idoxuridine was initially synthesized by William Prusoff in the late 1950s as an anticancer drug. In 1962, Herbert Kaufman introduced idoxuridine to the world as the first antiviral drug by treating a viral infection successfully.¹ It is a derivative of thymidine, one of the organic bases incorporated into the nucleic acids.

Mode of action: Idoxuridine irreversibly inhibits the incorporation of thymidine into viral DNA and replaces thymidine. So the newly formed viral particles are ineffective.

Pharmacokinetics: Idoxuridine exhibits poor penetration into the eye. Epithelial lesions are most responsive to therapy, while infections with stromal involvement are less responsive. Idoxuridine is used as 0.1% eye drops and 0.5% eye ointment.

Antiviral profile: It is indicated for use in the treatment of herpes simplex keratitis. Idoxuridine is ineffective against herpes simplex virus type 2 and varicella-zoster.²

Adverse effect: The drug is only used topically because of its cardiotoxicity on systemic use. When applied topically, it is relatively safe, though corneal toxicity can arise if used for prolonged periods. For this reason, it is not used for more than 21 days. It inhibits stromal healing and reduces wound strength and so cannot be used after corneal transplants.

Vidarabine

Vidarabine was the second antiviral drug developed for human use. Interestingly like idoxuridine, vidarabine was also initially synthesized as anticancer drug.

Mode of action: It acts by inhibiting viral DNA synthesis.

Pharmacokinetics: When used topically, it is absorbed to a greater extent than idoxuridine and can be used topically for herpetic infection, but is often given by injection for this condition. Because vidarabine is relatively insoluble, its topical preparation is not available as an eye drop. It is formulated as a 3% ophthalmic ointment. The recommended dosage is five times a day at 3-hour intervals.^{7,8}

Antiviral profile: Vidarabine is effective against herpes simplex (I and II), varicella-zoster, and vaccinia (DNA viruses). Vidarabine was also the first drug shown to be effective systemically in the treatment of herpetic encephalitis.

Adverse effect: Corneal epithelial punctate keratopathy, foreign body sensation, lacrimation, conjunctival hyperaemia, burning, irritation, pain, photophobia, sensitivity, and punctal occlusion.

Trifluridine

Trifluridine is a fluorinated nucleoside analogue of thymidine.

Mode of action: It acts by inhibiting viral DNA synthesis. It is phosphorylated intracellularly to its active form by host cell enzymes and then competes with thymidine triphosphate for incorporation by the viral DNA polymerase.

Pharmacokinetics: Trifluridine has better penetration- it can penetrate intact cornea into the aqueous humour. It is used topically in the form 1 percent solution. It is not used systemically as it rapidly degrades (Half-life 12 minutes) in the bloodstream.

Trifluridine is available as a 1% ophthalmic solution, and the preservative used in this preparation is thimerosal 0.001%. It is used every 2 hours or 9 times daily.

Antiviral profile: Trifluridine is superior to either vidarabine or idoxuridine in the treatment of epithelial keratitis.² It is found to be effective against HSV-1, HSV-2, vaccinia, and some adenoviruses.² Topical trifluridine solution, alone or combined with interferon alfa, has been used successfully in the treatment of acyclovir-resistant HSV infections.

Adverse effect: Corneal toxicity can develop if used for a prolonged period, and the duration of therapy should typically not exceed 21 days.

Acyclovir

Acyclovir is a synthetic purine nucleoside analogue derived from guanine.

Mode of action: Acyclovir interferes with DNA synthesis, thus inhibiting virus replication. The antiviral activity of acyclovir is dependent primarily on the intracellular conversion of acyclovir to acyclovir triphosphate.³ Acyclovir requires three phosphorylation steps for activation to acyclovir triphosphate. It is converted first to the monophosphate derivative by the virus-specified thymidine kinase and then to the di- and triphosphate compounds by host cell enzymes. Because it requires the viral kinase for initial phosphorylation, acyclovir is selectively activated only in infected cells.

Pharmacokinetics: Administration of acyclovir can be by an intravenous, oral, or topical route. The bioavailability of oral acyclovir is 15-20% and is unaffected by food. Topical formulations produce high concentrations in herpetic lesions. Acyclovir is cleared primarily by glomerular filtration and tubular secretion.³ Acyclovir accumulates in patients with renal failure. The half-life is approximately 3 hours in patients with normal renal function. Acyclovir diffuses readily into most tissues and body fluids. Cerebrospinal fluid concentrations are 50% of serum values.^{7,8}

Antiviral profile: Herpes simplex virus (HSV) Types 1 and 2, varicella-zoster virus (VZV), and some Epstein-Barr virus-mediated infections are sensitive to acyclovir.⁴ Acyclovir is the treatment of choice in HSV encephalitis.

Adverse effects: Acyclovir is generally well tolerated. Local irritation may occur from the topical application; headache, diarrhoea, nausea, and vomiting may result after oral administration. The major side effect of acyclovir is on renal function. This is due to the crystallization and deposition of the drug in the kidneys of patients who are dehydrated or have pre-existing renal insufficiency. Renal dysfunction can be avoided by infusing acyclovir slowly over 1 hour and administering 1 liter of fluid with each gram of the drug. Oral acyclovir has rarely been associated with renal dysfunction. Nausea, vomiting, and abdominal pain can occur and probably represent a direct toxic effect on the gastrointestinal tract.

Resistance: Resistant viral strains to acyclovir due to altered or deficient thymidine kinase and DNA polymerases have been found and are most commonly isolated from immunocompromised patients. Cytomegalovirus (CMV) is resistant to acyclovir because it lacks a specific viral thymidine kinase. These strains are cross-resistant to valacyclovir, famciclovir, and ganciclovir also because of their similar mechanism of action. Drugs like foscarnet, cidofovir, and trifluridine do not require activation by viral thymidine kinase and thus can be used against the most prevalent acyclovir-resistant strains.

Valacyclovir:

Valacyclovir is the L-valyl ester of acyclovir, which has greater oral bioavailability than acyclovir.

Mode of action: same as acyclovir

Pharmacokinetics: Valacyclovir is rapidly hydrolysed to acyclovir after oral administration by intestinal and hepatic first-pass metabolism and achieves serum levels that are three to five times greater than those achieved with oral acyclovir and approximate those achieved with intravenous acyclovir administration.⁵ Oral bioavailability is 54%, and cerebrospinal fluid levels are 50% of those in serum. The elimination half-life of the drug is 2.5-3.3 hours.^{7,8}

Antiviral profile: The drug is active against herpes simplex virus (HSV) Types 1 and 2, varicella-zoster virus (VZV). Valacyclovir has also been shown to prevent cytomegalovirus disease after organ transplantation compared with placebo effectively.

Adverse effects: Valacyclovir is usually well-tolerated, although nausea, vomiting, or rash occasionally occur. Agitation, dizziness, headache, liver enzyme elevation, anaemia, and neutropenia are rare. At higher doses, CNS manifestations like confusion, hallucinations, and seizures have been reported.⁵

Famciclovir

Mode of action: Same as acyclovir. It has a lower affinity for the viral DNA polymerase than acyclovir triphosphate, but it achieves higher intracellular concentrations and has a more prolonged intracellular effect than acyclovir.

Pharmacokinetics: After oral administration, famciclovir is rapidly converted by the first-pass metabolism to penciclovir. The bioavailability of penciclovir from orally administered famciclovir is 70%. The drug has an intracellular half-life of 10 hours in HSV-1-infected cells, 20 hours in HSV-2-infected cells, and 7 hours in VZV-infected cells in vitro. Penciclovir is excreted primarily in the urine.^{7,8}

Famciclovir is FDA approved for the treatment of herpes zoster infection at doses of 500 mg three times a day for 7 days. The therapy of ocular HSV, VZV has been adopted from genital HSV data. For acute first episodes, it is 250 mg three times a day for 7-10 days. For recurrent episodes, 125 mg twice a day for 5 days is recommended.

Antiviral profile: Oral famciclovir is active in vitro against HSV-1, HSV-2, VZV, EBV, and HBV. The drug is effectively used to treat first and recurrent attacks of herpes and the treatment of acute zoster.

Adverse effects: Oral famciclovir is usually well-tolerated, although headache, diarrhoea, and nausea may occur.

Resistance: Clinical mutants of HSV, due to altered or deficient thymidine kinase, are cross-resistant to acyclovir and famciclovir.

Ganciclovir

Ganciclovir is a synthetic analogue of deoxyguanosine that has greater activity against CMV.

Mode of action: Ganciclovir acts by selective inhibition of CMV DNA polymerase after phosphorylation in CMV-infected cells. It appears to interfere with DNA synthesis via competition with deoxyguanosine to incorporate into viral DNA and incorporate it into growing viral DNA chains.

Pharmacokinetics: Ganciclovir can be administered intravenously, orally, or via an intraocular implant. Cerebrospinal fluid concentrations are approximately 50% of those in serum. The drug's elimination half-life is 4 hours with normal renal function, and the intracellular half-life is 18 hours. The clearance of the drug is related to creatinine clearance. However, the bioavailability of oral ganciclovir is poor. In intraocular implant, ganciclovir is slowly released into the vitreous cavity at a rate of approximately 1.4 mcg/h.

Sustained release intraocular implant of ganciclovir is effective and safe both as an alternative to intravenous ganciclovir therapy in myelosuppressed patients and as a supplement to intravenous therapy in uncontrolled CMV retinitis. It avoids the risks of systemic toxicity associated with other routes of administration and negates the need for repeated injections. The implant is placed surgically in the vitreous cavity, and can provide therapeutic levels of up to 8 months depending on the rate of drug release. However an increased risk of CMV retinitis developing in the fellow eye and of systemic involvement in the patients who received implants compared with patients who received the drug intravenously has been observed. For which, these patients may be given oral ganciclovir.¹

Antiviral profile: Ganciclovir has been found effective against CMV, HSV, VZV, EBV, HHV-6, and KSHV (Kaposi's sarcoma-associated herpes virus) in vitro. It is currently

recommended for the treatment of CMV retinitis in immunocompromised patients and for CMV prophylaxis in transplant patients. Because ganciclovir is only virustatic, continuous therapy with the IV drug is necessary to prevent viral breakthrough in the immunosuppressed patient. However, despite careful management, many patients have reactivation of the disease.^{7,8}

Adverse effects: Unlike acyclovir, ganciclovir is more susceptible to phosphorylation by enzymes in uninfected (host) cells, especially in rapidly dividing cells like bone marrow. That is why the drug is more toxic to the bone marrow and causes significant neutropenia in more than half of the patients treated. Other less frequent side effects include nausea, neurotoxicity, hepatic dysfunction, fever.

Resistance: Resistant CMV strains have been reported. The drug does not code for thymidine kinase and is, therefore can be used in TK-resistant HSV and VZV strains.

Valganciclovir

Valganciclovir is the L-valyl ester of ganciclovir. Like valacyclovir, valganciclovir has high oral bioavailability.

Mode of action: Same as ganciclovir.

Pharmacokinetics: Valganciclovir is well absorbed and rapidly metabolized in the intestinal wall and liver to ganciclovir. The absolute bioavailability of oral valganciclovir is 60% and plasma protein binding is less than 2%. The major route of elimination is renal.^{7,8}

It may be given in therapeutically effective doses for treatment of CMV retinitis. Dosage is 900 mg twice a day for 3 weeks, then 900 mg once daily as maintenance.

Antiviral profile: Valganciclovir is indicated for the treatment of CMV retinitis in patients with AIDS and for the prevention of CMV disease in high-risk kidney, heart, and kidney-pancreas transplant patients.

Adverse effects: Myelosuppression and CNS or liver toxicity are potential side effects.

Resistance: same as ganciclovir.

Foscarnet

Unlike most of the antiviral agents, foscarnet is not a purine or pyrimidine analogue. Instead, it is a pyrophosphate derivative.

Mode of action: Like other antivirals, foscarnet does not require activation by viral (or human) kinases. It works by reversibly inhibiting viral DNA and RNA polymerases, thereby interfering with viral DNA and RNA synthesis.

Pharmacokinetics: Foscarnet is poorly absorbed orally and must be administered intravenously. It must also be given frequently to avoid relapse when plasma levels fall. It is dispersed throughout the body, cerebrospinal fluid concentrations are 43-67% of steady-state serum concentrations. Although the mean plasma half-life of the drug is 3-6.8 hours, up to 30% of foscarnet may be deposited in bone, with a half-life of several months. The drug is eliminated by glomerular filtration and tubular secretion.^{7,8}

The combination of ganciclovir and foscarnet is synergistic in vitro against CMV and has been shown to be superior to either agent alone in delaying progression of retinitis; however, the risks of combined toxicity increases when both agents are administered concurrently.

Intravitreal foscarnet is especially useful for patients in whom ganciclovir is contraindicated as a result of acyclovir allergy, and in whom intravenous foscarnet is contraindicated because of renal failure. The drug has been used to treat CMV retinitis in patients with AIDS; 1200 µg (0.05 mL) the drug is injected intravitreally. The recommended dose is two injections of foscarnet as induction therapy once per week for 3 weeks, followed by a maintenance dose of one injection per week.^{1,6}

Antiviral profile Foscarnet has broad in vitro antiviral activity. It is approved for CMV retinitis in immunocompromised hosts and for acyclovir-resistant HSV and herpes zoster infections. It has in vitro activity against HSV, VZV, CMV, EBV, HHV-6, KSHV, and HIV-1.⁷

Adverse effects: Adverse effects include nephrotoxicity, anaemia, nausea, and fever. Hypocalcaemia, hypomagnesaemia, hypokalaemia, hypo- and hyperphosphatemia, seizures, and arrhythmias have been reported. The most significant side effect with foscarnet is renal impairment. It is necessary to monitor the serum creatinine levels and adjust the drug dosage before every injections.

Cidofovir

Cidofovir is approved for treatment of CMV-induced retinitis in patients with AIDS. Cidofovir is a nucleotide analogue of cytosine,

Mode of action: Like foscarnet, the phosphorylation of cidofovir is not dependent on viral enzymes. The drug acts by inhibiting viral DNA synthesis.⁷

Pharmacokinetics: Cidofovir is available for intravenous, intravitreal and topical administration. Although the terminal half-life of the drug is about 2.6 hours, its active metabolite, cidofovir diphosphate, has a prolonged intracellular half-life of 17- 65 hours,

which permits prolonged dosage intervals and eliminates frequent dosages used for ganciclovir therapy. Cerebrospinal fluid penetration is poor and the drug is eliminated from body by active renal tubular secretion.^{7,8}

Intravenous cidofovir is administered with probenecid (2 gm. at 3 hours before the infusion and 1 gm. at 2 and 8 hours after the infusion), which blocks active tubular secretion and decreases nephrotoxicity. Direct intravitreal administration of cidofovir is not recommended because of ocular toxicity.

Adverse effects: Cidofovir has significant renal toxicity and it is contraindicated in patients with pre-existing renal impairment. Other side effects include uveitis, ocular hypotony, neutropenia and metabolic acidosis.

References:

1. Hoffman J. Overview of antiviral medications used in ophthalmology. *Community Eye Health*. 2020;33(108):85-88.
2. Wilhelmus KR. Antiviral treatment and other therapeutic interventions for herpes simplex virus epithelial keratitis. *Cochrane Database Syst Rev*. 2015;(1). doi:10.1002/14651858.CD002898.pub5
3. Teich SA, Cheung TW, Friedman AH. Systemic antiviral drugs used in ophthalmology. *Surv Ophthalmol*. 1992;37(1):19-53. doi:10.1016/0039-6257(92)90003-c
4. Acyclovir for the prevention of recurrent herpes simplex virus eye disease. Herpetic Eye Disease Study Group. *N Engl J Med*. 1998;339(5):300-306. doi:10.1056/NEJM199807303390503
5. Beutner KR. Valacyclovir: a review of its antiviral activity, pharmacokinetic properties, and clinical efficacy. *Antiviral Res*. 1995;28(4):281-290. doi:10.1016/0166-3542(95)00066-6
6. Port AD, Orlin A, Kiss S, Patel S, D'Amico DJ, Gupta MP. Cytomegalovirus Retinitis: A Review. *J Ocul Pharmacol Ther Off J Assoc Ocul Pharmacol Ther*. 2017;33(4):224-234. doi:10.1089/jop.2016.0140
7. Baden, L. R., & Dolin, R. (2017). Antiviral chemotherapy, excluding antiretroviral drugs. In 971154798 753889251 D. L. Kasper & 971154799 753889251 A. S. Fauci (Eds.), *Harrison's infectious diseases*. New York: McGraw-Hill Education.
8. Hopkins, G., & Pearson, R. M. (2007). Drugs for the treatment of infections. In *Ophthalmic drugs diagnostic and therapeutic uses*. Edinburgh: Butterworth Heinemann/Elsevier.





Viral Anterior Uveitis and More!



Dr. Sahana Mazumdar

Consultant Retina and Uvea

ICARE EYE Hospital and PG institute

Noida (UP)

Email: sahana.mazumdar@gmail.com

Viral Anterior Uveitis and More!

A 70 years old healthy female presented with blurred vision and mild pain in the left eye since a few weeks. She had suffered dermatomal herpes zoster (back) involvement 5 months ago for which she had taken treatment. For her eye problem she had shown elsewhere and had been prescribed antibiotic drops initially and then changed to topical steroids, which she had started one day before presenting to us. The intraocular pressures had not been recorded.

On examination the BCVA was 6/6 N6, 6/24 N18 and IOP was 20 and 34mmHG.

The anterior segment of the right eye was normal except for early cataract NS1+. In the left eye the cornea was clear, there were multiple medium sized KPs all over the cornea (Figure 1A) with 2+ cells in the anterior chamber, the pupillary reaction and iris pattern were normal. There was NS 3+ cataract (Figure 1A). On gonioscopy the angles were open. The vitreous showed 2+ cells. The retinal view was hazy. Details of disc and macula could not be made out (Figure 1B). There was a patch of white retinal necrosis in the supero-temporal periphery with a small retinal hemorrhage and vitreous clumps over that area (Figure 1C) and on the optic nerve head (Figure 1B). Right eye also showed Vitreous cells 1+ and there were multiple small hypopigmented lesions scattered in all quadrants (Figure 1D). The right eye disc was healthy.

Figure 1-Anterior segment of left eye showing cataract and medium sized KPs deposited over the entire cornea. 1B- Hazy view of the left eye fundus with vitreous clump over the optic nerve head 1C- Left eye -superotemporal patch of retinal necrosis, retinal hemorrhage and vitreous clumps. 1D- Right eye showed multiple small hypopigmented lesions in all quadrants.

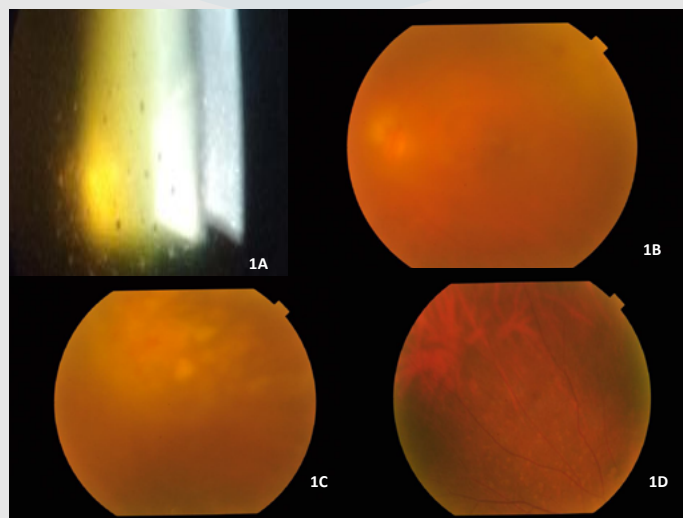


Figure: 1A,1B,1C,1D

Our working diagnosis at this point was left eye-Hypertensive panuveitis with Acute retinal necrosis (ARN) (most likely Herpes Zoster (HZV)) and right eye-? Early ARN.

Rationale for diagnosis was that the hypertensive uveitis and ARN suggested a viral etiology and herpes zoster was most likely due to the history of dermatomal affliction.

She was started on intravenous acyclovir, steroid–cycloplegic and two antiglaucoma eye drops in the left eye.

She returned a week later after 19 Injections of Intravenous Acyclovir but had significantly worsened! The retinitis had progressed to the posterior pole and her vision had dropped to 3/60! The anterior uveitis was better and the intraocular pressures had decreased to 28mmhg. On FFA, the left eye showed staining of disc vessels and the superotemporal retinitis patch extending to the posterior pole (Figure 2B). In the right eye the small multiple lesions were stained (Figure 2A). OCT macula both eyes showed normal contours and the hypopigmented lesions were located sub-RPE (Figure 2C).

Her investigations revealed normal CBC, ESR and Serum ACE. The Mantoux was 8mm. IgG and IgM–ve for Toxoplasma. IgG was positive for Rubella, Cytomegalovirus (CMV) and Herpes Simplex 1&2 (HSV) but their IgMs were negative. Test for Human Immunodeficiency virus (HIV) was negative.

As she was not responding to acyclovir we decided to go ahead with an AC tap and sent it for PCR for viral genomes. PCR came positive for CMV and negative for HSV and HZV (Figure 2D).

Figure 2 -FFA of the right eye highlighted the numerous retinal lesions that stained in the late phases. 2B-In the left eye the extended patch of retinitis and the disc showed staining. There was diffuse leaks from the capillaries elsewhere. 2C- OCT scans of the right eye lesions localised them to be in the sub RPE space. 2D- PCR of aqueous was positive for CMV genome

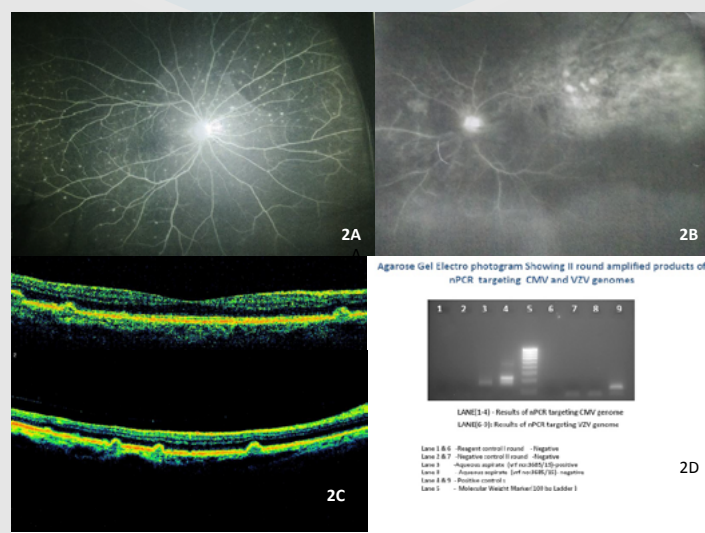


Figure: 2A,2B,2C,2D

Toxoplasmosis seemed very unlikely, as both IgG/IgM were negative. She was started on Tab Valgancyclovir 900 mg BD and other treatment continued. She responded after a week and oral steroids were added. After one month the retinitis had resolved (Figure 3)

Figure 3- Resolving retinitis

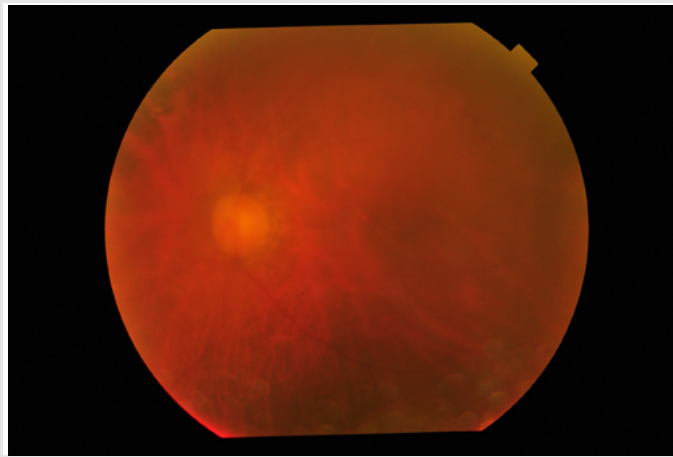


Figure: 3

and the IOP was now controlled. Her BCVA improved to 6/36. The right eye remained the same. Both eyes had vitreous cells 1+. The AGM and topical steroids were tapered. She was put on maintenance valgancyclovir and tapering oral steroids.

But there were many unanswered questions. Why did she have multiple virus infections ? Was she somehow immunocompromised? What were the small sub RPE deposits and the vitritis in right eye due to?

Could the answer to all the questions be that she had an underlying intraocular lymphoma ?

An MRI brain and neurophysician's opinion did not support a diagnosis of lymphoma. A vitreous biopsy was acellular. It was taken after stopping oral steroids for 10 days to improve likelihood of getting lymphoma cells. There was no option but to keep her under observation.

Six weeks later she reported CNS symptoms and went under the care of a neurologist. Repeated investigations (PET scan, MRI, CSF analysis), calls from me could not convince the neurologists of suspicions of lymphoma and she was treated as meningitis. Eventually when she showed no response they performed a brain biopsy confirming a CNS B cell lymphoma. However she succumbed the next day.

Discussion:

Usually anterior uveitis is associated with decreased intraocular pressures due to hyposecretion from an inflamed ciliary body. An elevated intraocular pressure in the setting of anterior uveitis (provided steroids have not been started) is termed as hypertensive uveitis (HTU). Hypertensive uveitis is an often-missed entity, as intraocular pressures may not be recorded in patients with uveitis as in this case.

HTU represents a subset of uveitis that is often suggestive of a viral etiology¹ though it has also been reported with sarcoidosis. The elevated IOP is likely to be due to associated trabeculitis and resolves with topical steroids and anti-virals. Many a times the treating physicians shy from starting full strength topical steroids fearing steroid induced elevation of IOP. In case there is recurrence on tapering of treatment-long term antivirals and low dose steroids are required. Hence an attempt to identify the infecting virus has to be made. Clinical features can give clues to the associated virus and there is a role of PCR of the aqueous to identify the viral genome.

Also all patients with anterior uveitis should have a detailed examination of the vitreous and fundus to look for posterior segment involvement. This may even reveal need for urgent treatment and also offer clues to the etiology. In our patient a dilated examination revealed bilateral vitritis with acute retinal necrosis in the left eye and some widespread hypopigmented lesions both eyes left more than right which gave clues to an underlying condition.

Though the obvious incriminating virus seemed to be herpes zoster due to the earlier dermatomal involvement, our patient did not respond to anti herpetic treatment-intravenous Acyclovir. The PCR of the aqueous then confirmed the presence of a different virus (CMV).² and the patient eventually responded to initiation of anti CMV therapy-Valgancyclovir.

Usually HTU is seen in the setting of an immunocompetent individual. However in the elderly one must look for an associated immunocompromised state. In our patient, older age and the affliction with two different viruses strongly suggested the need to look for a cause for immunosuppression. The diffuse sub RPE deposits in both eyes were suggestive of intraocular lymphoma. However the hunt for underlying Lymphoma with an MRI brain, neurologists review and vitreous biopsy was inconclusive. Eventually a brain biopsy proved the B cell lymphoma and explained the immunocompromised condition.

References:

1. Viral Anterior Uveitis: Babu K, Konana VK, Ganesh SK, Patnaik G, Chan NSW, Chee SP, Sobolewska B, Zierhut M. Indian J Ophthalmol. 2020 Sep;68(9):1764-1773. doi: 10.4103/ijo.IJO_928_20.
2. Cytomegalovirus-associated acute retinal necrosis syndrome B E Silverstein D Conrad, T P Margolis, I G Wong. Case Reports- Am J Ophthalmol.1997 Feb;123(2):257-8. doi: 10.1016/s0002-9394(14)71046-3.





What is New in Viral Uveitis?



Dr. Sudha K Ganesh



Dr. Sharanya Abraham



Dr. Nivedita Nair

Department of Uvea, Medical Research Foundation
Sankara Nethralaya Chennai, Tamil Nadu, India

Email: drskg@gmail.org

What is New in Viral Uveitis?

Introduction: The aim of this tabulated compilation on Viral Uveitis, is to highlight the recent literature on Viral Uveitis. A Pubmed search of the last 5 years [January 2016 – September 2020] literature using terms virus and uveitis and viral uveitis was done. Review articles, original research and few interesting case reports/case series with novel descriptions were included.

The articles are tabulated under the following headings:

Viral Uveitis: Clinical diagnosis, Viral Uveitis: Laboratory diagnosis, Viral Uveitis and ocular imaging, Viral Uveitis: management, and Emerging viral uveitis.

The human immunodeficiency virus (HIV) was excluded, as it was beyond the scope of this compilation. Discussion on COVID is limited in this section, as it is dealt in detail elsewhere in the same newsletter. The authors hope that this compilation will serve as a ready reckoner of recent references pertaining to viral uveitis.

Viral uveitis: Clinical Diagnosis

Year	Authors	Title and Journal	Salient Features
2020	Keorochana N Treesit I Funarunart P	Characteristics and Clinical Outcomes of Hypertensive Anterior Uveitis. Ocul Immunol Inflamm. 2020 May 18; 28(4):538-548.	64 AU participants with increased IOP and Herpes viridae PCR analysis results were included. Viral infection was found in one half of hypertensive AU. Complications of PCR-proven infectious cases were more severe than PCR-negative cases.
2020	Pohlmann D Pahlitzsch M Schlickeiser S <i>et al.</i>	Virus-associated anterior uveitis and secondary glaucoma: Diagnostics, clinical characteristics, and surgical options. PLoS One. 2020 Feb 24;15(2):e0229260.	Observational study, 270 eyes with viral AU were compared for clinical characteristics, glaucoma development, and glaucoma surgery requirement. The authors concluded that different viral AU entities present specific risks for the development of glaucoma as well as necessary surgery.
2020	Kianersi F Taghdiri MH Kianersi H, Bagi A Naderi Beni A	Reactivation of Varicella-Zoster Virus Anterior Uveitis after YAG Peripheral Iridotomy. Ocul Immunol Inflamm. 2020 Mar 13:1-2.	Case report found that YAG PI may be a risk factor for reactivation of herpetic AU. Prophylaxis with acyclovir may be necessary after YAG PI to prevent reactivation of herpetic AU.

2020	Kawali A Mahendradas P Sanjay S Shetty R	Viral Kerato-Uveitis with Choroidal Vitiligo. Ocul Immunol Inflamm. 2020 Apr 7:1-4.	Authors reported a rare posterior segment manifestation of kerato-uveitis caused by VZV, which they called “choroidal vitiligo” as no active inflammation was noted in those lesions.
2020	Accorinti M Petitti L Gaeta A Giannini D De Geronimo D	Viral Acute Anterior Uveitis: Clinical Signs Useful for Differential Diagnosis. Ocul Immunol Inflamm. 2020 May 14:1-8.	To assess the frequency of clinical signs in patients with viral AAU, and their ability to differentiate viral versus non-viral AAU. 84 out of 168 patients with AAU had presumed viral etiology; Unilaterality, IOP \geq 24 mmHg and iris atrophy are significant predictors of possible viral etiology in AAU.
2020	Shirahama S Kaburaki T Takada S <i>et al.</i>	Comparison of visual field defect progression in secondary Glaucoma due to anterior uveitis caused by three types of herpes viruses. Graefes Arch Clin Exp Ophthalmol. 2020 Mar;258(3):639-645.	170 patients with herpetic AU were enrolled in this retrospective observational case series. Patients with visual field (VF) defects and glaucomatous disc abnormalities were diagnosed with secondary glaucoma (SG). Patients with CMV-AU may have a higher risk and faster speed of progression of SG than patients with HSV/VZV-AU.
2020	Kong CL Thompson RR Porco TC Kim E Acharya NR	Incidence rate of herpes zoster ophthalmicus: A retrospective cohort study from 1994 through 2018. Ophthalmology 2020;127:32430.	From 1994 through 2018, 633 474 cases of HZ were reported, with 49 745 (7.9%) having HZO. The incidence of HZO increased from 1994 through 2018 by an estimated 1.1 cases per 100 000 person-years annually (95% confidence interval [CI], 1.0–1.3; P < 0.001).
2020	Khieu C, Kongyai N Pathanapitoon K Van Der Eijk AA Rothova A	Causes of Hypertensive Anterior Uveitis in Thailand. Ocul Immunol Inflamm. 2020 May 18;28(4):559-565.	31 patients with AU and IOP above 25 mmHg were included for PCR analysis for CMV, HSV, VZV, RV, CHIKV and ZIKV. PCR evidence of infection with herpes group viruses was found in one-third of patients with hypertensive AU; CMV being the most common pathogen. The PCR-positive group generally responded well to a combination of antiviral and anti-glaucoma treatment.

2020	Babu K, Konana VK Ganesh SK <i>et al.</i>	Viral anterior uveitis. .Indian J Ophthalmol. 2020 Sep;68(9):1764- 1773.	This review focuses on syndromes associated with viral etiology, different viruses causing AU, clinical features, diagnostic tools, and management of viral anterior uveitis. The authors conclude that raised IOP at presentation, corneal scars, fresh pigmented KPs, and iris atrophy are features of VAU. HSV, VZV, CMV, RV are common etiologies. Diagnostic tests like PCR, GWC analysis for confirmation of etiology may be required. Glaucoma was the most common vision-threatening complication of VAU.
2020	Thomas AS Lin P	Local treatment of infectious and noninfectious intermediate, posterior, and panuveitis: current concepts and emerging therapeutics. Curr Opin Ophthalmol. 2020 May;31(3): 174-184.	Local therapeutics plays an important role in the management of infectious and noninfectious uveitis (NIU) as well as certain masquerade syndromes. This review highlights the established therapeutics and those under investigation for the management of uveitis. Local antivirals may improve outcomes in cases of viral retinitis.
2020	Hedayatfar A Ebrahimiadib N Zarei M <i>et al.</i>	Acute retinal necrosis: Clinical manifestation and long-term visual outcomes in a series of polymerase chain reaction-positive patients. Eur J Ophthalmol. 2020 Jun 21:1120672120936181.	Patients with diagnosis of ARN and a positive aqueous viral PCR were included in this study. 19 eyes had a clinical diagnosis of ARN, of which 18 (94.7%) had a positive viral PCR. ARN was unilateral, except in one patient. Regardless of the method of management, the rate of RRD is high and is associated with a poor visual outcome.
2020	Williams AM Nguyen VQ Botsford BW Eller AW	Bilateral acute retinal necrosis caused by two separate viral etiologies. Am J Ophthalmol Case Rep. 2020 Feb 28;18:100636.	Authors describe an unusual case of bilateral ARN, caused by VZV in one eye and EBV in the fellow eye four months later in an immunocompromised elderly patient.

2020	Battista M Marchese A Bordato A Bandello F Modorati GM Miserocchi E	Ophthalmic Shingles with Simultaneous Acute Retinal Necrosis in the Opposite Eye. Ocul Immunol Inflamm. 2020 Jul 9:1-3.	This is a case report of concurrent acute visual loss in the right eye and ophthalmic shingles skin eruption of the left ophthalmic trigeminal branch. Fundus examination of the right eye revealed ARN. Laboratory tests confirmed the diagnosis.
2020	Elyashiv SM Samson CM Jabs DA	Retinal findings in presumed infectious posterior uveitis and correlation with polymerase chain reaction results. Retina. 2020 Mar;40(3):567-571.	To correlate demographics, retinal lesion characteristics, and host immune status with PCR of aqueous fluid in patients with suspected infectious posterior uveitis. Detection of HSV or VZV on PCR of aqueous was associated with paucifocal lesions (82%, $P = 0.021$) and lesions involving the peripheral retina (91%, $P = 0.023$), consistent with the diagnosis of ARN.
2020	Haw YL Yu TC Yang CS	A CARE-compliant article: a case report of possible association between recurrence of multiple evanescent white dot syndrome and the Herpesviridae family. Medicine (Baltimore). 2020 Apr;99(15):e19794.	A case report of a patient with recurrent episodes MEWDS over 2 years. Serologic data for VZV IgM antibody was positive in the first episode. Two years later, the patient had recurrent episodes of MEWDS in the contralateral eye. Serologic study showed highly elevated IgG titer of EBV capsid antigen (EB-VCA) in the acute stage.
2019	Chan NS Chee S P	Demystifying viral anterior uveitis: A review. Clin Exp Ophthalmol. 2019 Apr;47(3):320-333.	There should be a high index of suspicion for a viral etiology in any case of hypertensive AU or iris atrophy. Newer diagnostic techniques offer opportunities to identify more viruses and may shed light on AU that were previously idiopathic.

2019	Fazil Z Ten Berge JC Langerak AW Rothova A Dik WA.	An Intraocular Inflammatory Profile of Rubella Associated Uveitis. Ocul Immunol Inflamm. 2019;27(3):418-423.	Levels of 15 cytokines (IL-1 β , IL-1ra, IL-2, IL-6, IL-6ra, IL-7, IL-8, IL-10, IL-17A, IL-23, TARC, MCP-1, TNF- α , PIGF, and VEGF) were measured using multiplex assay, and intraocular cell populations were determined by multiparameter flowcytometry. Rubella virus associated uveitis patients exhibit a cytokine profile distinct from noninfectious uveitis and cataract.
2019	Murata K Ishida K Ozawa K Sawada A Mochizuki K Yamamoto T	The characteristics of Posner-Schlossman syndrome: A comparison in the surgical outcome between CMV positive and CMV negative patients. Medicine (Baltimore). 2019 Nov;98(48):e18123.	This retrospective observational study aimed to report the clinical characteristics and surgical results in eyes with PSS syndrome, and compare these outcomes between CMV-positive and -negative eyes.
2019	Groen-Hakan F van de Laar S van der Eijk-Baltissen AA Ten Dam-van Loon N de Boer J Rothova A	Clinical Manifestations, Prognosis, and Vaccination Status of Patients With Rubella Virus-Associated Uveitis. Am J Ophthalmol. 2019 Jun;202:37-46.	The clinical and laboratory manifestations and vaccination status of uveitis patients positive for RV in aqueous were assessed and its relationship to FUS syndrome was investigated. Almost all FUS cases had documented intraocular RV infection, but only some of the patients with RV-associated uveitis presented with FUS.
2019	Gonzales JA Hinterwirth A Shantha J <i>et al.</i>	Association of Ocular Inflammation and Rubella Virus Persistence. JAMA Ophthalmol. 2019 Apr 1;137(4):435-438.	A case series of 6 patients with detectable rubella virus RNA in the intraocular compartment exhibited typical and atypical characteristics of FHI. Metagenomic deep sequencing (MDS) demonstrates that persistent and active RV infection is associated with FHI.

2019	Khairallah M Mahendradas P Curi A Khohtali S Cunningham ET Jr	Emerging Viral Infections Causing Anterior Uveitis. Ocul Immunol Inflamm. 2019;27(2):219-228.	Clinical diagnosis of any emerging infectious disease is based on epidemiological data, history, systemic symptoms and signs, and the pattern of ocular involvement. The diagnosis is usually confirmed by detection of virus-specific DNA or antiviral antibodies in serum.
2019	Qian Z Fan H Tao Y Li W Gu W	Herpetic Anterior Uveitis in a Chinese Referral Center: Clinical Manifestations and Laboratory Test Results. Ocul Immunol Inflamm. 2019 Oct 1:1-6.	Thirty-two eyes herpetic AU were studied. Amongst them, 24 had VZV-AU and 8 had HSV-AU. Compared with HSV-AU, the intraocular inflammation was more severe in VZV-AU.
2019	Sakai JI Usui Y Suzuki J Kezuka T Goto H	Clinical features of anterior uveitis caused by three different herpes viruses. Int Ophthalmol 2019;39:278595.	Clinical findings of HSV-AU and VZV-AU were similar; however, more inflammatory findings were observed in VZV-AU. Iris atrophy morphologically differed in HSV-AU and VZV-AU. Inflammatory findings in CMV-AU were mild, and clinical features of iritis differed from those of the two former groups. A difference in the etiology between CMV-AU and PS syndrome was observed.
2019	Lu LM McGhee CNJ Sims JL Niederer RL	High rate of recurrence of herpes zoster related ocular disease after phacoemulsification cataract surgery. J Cataract Refract Surg 2019;45:8105.	The outcomes of phacoemulsification cataract surgery in eyes with herpes zoster-related keratitis and/or uveitis were evaluated. 57 eyes were included. Herpes zoster disease recurrence after surgery was common and was severe in some cases. Maximizing the period of quiescence before surgery and the potential role of antiviral prophylaxis should be considered.

2019	Kawali A Mahendradas P Mohan A Mallavarapu M Shetty B	Epidemic Retinitis. Ocul Immunol Inflamm. 2019;27(4):571-577.	The authors study demography, seasonal variation, clinical presentation, and treatment outcome of “retinitis post febrile illness.” (RpFI) and name it epidemic retinitis. Epidemic retinitis has an aggressive presentation, but resolves over 3-4 months. Chikungunya IgM, Dengue IgM, and Weil-Felix test was positive in 22.22%, 15.38%, and 39.75%, respectively, in investigated cases. Majority of fever was of unknown etiology
2019	Kunavisarut P Srisomboon T Patikulsila D <i>et al.</i>	Risk Factors for Development of Rhegmatogenous Retinal Detachment in Patients with Uveitis. Ocul Immunol Inflamm. 2019;27(4):681-685.	Prevalence of RRD in uveitis was 7% and development of RRD was encountered in posterior and panuveitis. Infectious uveitis (specifically ARN) formed a high risk for RRD.
2019	Miserochi E Iuliano L Fogliato G <i>et al.</i>	Bilateral Acute Retinal Necrosis: Clinical Features and Outcomes in a Multicenter Study. Ocul Immunol Inflamm. 2019;27(7):1090-1098.	BARN was most commonly seen with HSV-1 infection. It was associated with poor visual outcome and high rate of ocular complications in form of RD and optic atrophy. Although BARN is a rare disease, the course is aggressive.
2019	Tsui I Neves LM Adachi K <i>et al.</i>	Overlapping Spectrum of Retinochoroidal Scarring in Congenital Zika Virus and Toxoplasmosis Infections. Ophthalmic Surg Lasers Imaging Retina. 2019 Dec 1;50(12):779-784.	Congenital Zika infection retinochoroidal subclinical lesions may become indistinguishable from toxoplasmosis.

2019	Fuller R Strauss D Steinberg A <i>et al.</i>	A lymphoma patient with Cytomegalovirus retinitis and post-autologous hematopoietic cell transplantation immune reconstitution uveitis: A case report and review of the literature. Transpl Infect Dis. 2019 Aug;21(4):e13099.	CMV retinitis in patients with lymphoma has variable clinical presentations, may occur at any time during the course of the disease and chemotherapy, and was associated with significant morbidity.
2019	Takayama K Kaburaki T Takeuchi M	Development of Acute Retinal Necrosis in a Patient with Ocular Sarcoidosis: A Case Report. Ocul Immunol Inflamm. 2019;27(7):1067-1070.	Case report of a 75 year old lady with ocular sarcoidosis on oral steroids, with extended yellowish white peripheral retinal lesion in the right eye suggesting ARN. PCR testing using ocular fluid detected VZV DNA.
2019	de-la-Torre A Valdés-Camacho J de Mesa CL <i>et al.</i>	Coinfections and differential diagnosis in immunocompetent patients with uveitis of infectious origin. BMC Infect Dis. 2019 Jan 25;19(1):91.	Clinical diagnosis can be changed by laboratory examination in a significant proportion of cases of uveitis. The use of multiple laboratory methods is necessary to identify co-infections and viral infections that can mimic ocular toxoplasmosis in immunocompetent patients.
2018	Wensing B Mochizuki M De Boer JH	Clinical Characteristics of Herpes Simplex Virus Associated Anterior Uveitis. Ocul Immunol Inflamm. 2018;26(3):333-337.	The clinical characteristics of HSV anterior uveitis could mimic other viral and non-infectious anterior uveitis entities especially at onset. Aqueous humor analysis for PCR and Goldmann-Witmer coefficient (GWc) may be useful in case of suspected viral uveitis
2018	Touhami S Qu L Angi M <i>et al.</i>	Cytomegalovirus Anterior Uveitis: Clinical Characteristics and Long-term Outcomes in a French Series. Am J Ophthalmol. 2018 Oct;194:134-142.	Characteristics of immunocompetent CMV anterior uveitis were studied. Early initiation of antiviral therapy seemed to reduce the severity of glaucoma.

2018	Tugal-Tutkun I Cimino L Akova YA	Review for Disease of the Year: Varicella Zoster Virus-Induced Anterior Uveitis. Ocul Immunol Inflamm. 2018;26(2):171-177.	HZO AU is often accompanied by keratitis with a chronic recurrent course, and leads to sectoral iris atrophy, pupillary distortion, and ocular hypertension. Diagnosis is clinical and confirmed by analysis of aqueous humor for viral genome or antiviral antibodies. Systemic antiviral agents and topical steroids are the mainstay of treatment. Visual prognosis is favorable with timely diagnosis and appropriate treatment.
2018	Chan NS Chee S P Caspers L Bodaghi B	Clinical Features of CMV-Associated Anterior Uveitis. Ocul Immunol Inflamm. 2018;26(1):107-115.	The acute CMV-associated AU presents as PS Syndrome. Asian patients present as Fuchs Uveitis Syndrome while the European patients present with a chronic hypertensive AU, with fewer KPs. Characteristic features of CMV anterior uveitis are mild anterior uveitis, elevated IOP, stromal iris atrophy and may be associated with corneal endothelitis. Sequelae included glaucomatous optic neuropathy and cataract.
2018	Relvas LJ Caspers L Chee SP Zierhut M Willermain F	Differential Diagnosis of Viral-Induced Anterior Uveitis. Ocul Immunol Inflamm. 2018;26(5):726-731.	This review details how the clinician can differentiate viral from nonviral AU, and focuses on the key features that aid in differentiating the viruses that cause anterior uveitis.
2018	Relvas LJM Antoun J de Groot-Mijnes JDF <i>et al.</i>	Diagnosis of Cytomegalovirus Anterior Uveitis in Two European Referral Centers. Ocul Immunol Inflamm. 2018;26(1):116-121.	Combining PCR and GWC were very helpful to confirm the clinical diagnosis of CMV AU. In case of very high clinical suspicion and negative results, repeated aqueous tap were recommended.
2018	Biswas J Kharel Sitaula R Multani P.	Changing uveitis patterns in South India - Comparison between two decades. Indian J Ophthalmol. 2018 Apr;66(4):524-527.	A comparative study was done between uveitis patients of 2013 and 1995. The incidence of viral anterior and posterior uveitis was found to have increased owing to changing patterns and better diagnostic modalities.

2018	Babu K Mahendradas P Sudheer B <i>et al.</i>	Clinical Profile of Herpes Zoster Ophthalmicus in a South Indian Patient Population. Ocul Immunol Inflamm. 2018;26(2):178-183.	The clinical profile of HZO patients in a South Indian population was studied. AU with or without keratitis was the most common presentation in more than 50% cases. The overall visual outcome was good.
2018	Siak J Chee S P	Cytomegalovirus Anterior Uveitis Following Topical Cyclosporine A. Ocul Immunol Inflamm. 2018;26(1):90-93.	The authors report the first case of an immunocompetent individual who presented with CMV anterior uveitis after the use of topical cyclosporine A 0.05% ophthalmic emulsion for the treatment of symptomatic dry eyes.
2018	Babu K Parameswarappa DC Sudheer B	Tonic Pupil in Cytomegalovirus Anterior Uveitis in an Immunocompetent Adult Male - A Case Report. Ocul Immunol Inflamm. 2018;26(1):104-106.	The authors describe a unique finding of tonic pupil on a follow-up examination in an immunocompetent adult male with CMV anterior uveitis.
2018	Harada Y Fukuda K Nakahira A Tada K Sumi T Fukushima A	Requirement of longer term antiviral therapy in patients with cytomegalovirus anterior uveitis with corneal endothelial cell damage. Clin Ophthalmol 2018;12:13116.	Patients with corneal endothelial cell loss are likely to require longer term antiviral therapy than those without endothelial damage. Definitive diagnosis of CMV anterior uveitis required the detection of CMV DNA in aqueous humor by PCR. One-fifth of patients in the study tested negative on initial examination.
2018	Cunningham ET Jr Miserocchi E Tugal-Tutkun I Zierhut M	Varicella Zoster Virus-Associated Uveitis. Ocul Immunol Inflamm. 2018;26(2):167-170.	Studies related to VZV-associated uveitis were highlighted. The common and variable presentation of uveitis in patients with HZO, and poor outcomes associated with VZV-induced necrotizing retinitis and orbital apex syndrome were discussed. Greater than four-fold increase in ischemic stroke following HZO highlighted the importance of prompt diagnosis and treatment of active inflammation, and of prophylactic vaccination in those over 50 years of age.

2018	Kim JY Lee JH Lee CS Lee SC	VZV-associated Chorioretinitis: a case report. BMC Ophthalmol. 2018 Feb 5;18(1):28.	VZV-associated posterior uveitis may present as multifocal chorioretinitis (described using serial OCT images). Intraocular fluid analysis was found to be important in diagnosis.
2018	Hamouda M Kahloun R Jaballah L <i>et al.</i>	Cytomegalovirus Ocular Involvement in a Kidney Transplant Recipient. Exp Clin Transplant. 2018 Aug;16(4):495-498.	The authors report cytomegalovirus retinitis and AU, within a year of renal transplant. PCR for CMV in plasma and in aqueous was positive. The patient was treated with intravenous and oral ganciclovir.
2018	Yu J Ashworth J Hughes S Jones N	Varicella-zoster virus necrotising retinitis, retinal vasculitis and panuveitis following uncomplicated chickenpox in an immunocompetent child. BMJ Case Rep. 2018 Apr 5;2018:bcr2017223823	A 4-year-old girl had acute visual loss left eye 4 weeks following chickenpox. She had necrotising retinitis, retinal vasculitis and vitritis. Aqueous humour was PCR positive for VZV. Combined intravenous and intravitreal antiviral treatment led to rapid improvement.
2018	Souissi S Fardeau C Le HM Rozenberg F Bodaghi B Le Hoang P	Chronic Herpetic Retinitis: Clinical Features and Long-Term Outcomes. Ocul Immunol Inflamm. 2018;26(1):94-103.	A case series of 4 patients treated for uveitis. They all had atrophic retinal lesions resulting in an unfavorable outcome with worsening and vision loss under immunosuppressive treatment. VZV and HSV type 2 were detected in ocular samples. Antiherpetic treatments improved the control of intraocular inflammation.
2018	Moussa K Doan T Stewart JM <i>et al.</i>	Cytomegalovirus retinitis associated with occlusive vasculopathy in an elderly, human immunodeficiency virus-negative man. Retin Cases Brief Rep. 2018 Fall;12 Suppl 1(Suppl 1):S114-S117.	A case report of CMV retinitis associated with occlusive vasculopathy presenting as sudden unilateral loss of vision in an elderly diabetic man who was treated with oral valganciclovir and intravitreal foscarnet injections with resolution.

2018	Gupta R Tyagi M Balakrishnan D Rani PK	Acute retinal necrosis following chickenpox in a patient of VKH syndrome using immunosuppressants. BMJ Case Rep. 2018 Nov 28;11(1):e227290.	<p>The authors describe the case of a young woman treated for VKH with pulse steroid and immunosuppression with resolution. However, she developed chickenpox and discrete yellowish white retinitis patches in the periphery of the right eye which were consistent with a diagnosis of acute retinal necrosis. She was started on oral antivirals for the same and retinitis patches resolved with treatment.</p>
2018	Joye A Gonzales JA	Ocular manifestations of CMV in immunocompetent hosts. Curr Opin Ophthalmol. 2018 Nov;29(6):535-542.	<p>This review highlights recent studies that have increasingly implicated cytomegalovirus (CMV) as a significant cause of keratouveitis and retinitis in immunocompetent hosts.</p>
2018	Sato T Kitamura R Kaburaki T Takeuchi M	Retinitis associated with double infection of EBV and VZV: A case report. Medicine (Baltimore). 2018 Aug;97(31):e11663.	<p>Elderly patients under immunosuppression may be susceptible to develop retinitis associated with infection of multiple human herpes viruses, and multiplex PCR is an excellent tool to diagnose an unidentified panuveitis resembling this case.</p>

2017	<p>Lee J H Agarwal A Mahendradas P <i>et al.</i></p>	<p>Viral posterior uveitis. <i>Surv Ophthalmol.</i> 2017; 62(4):404-445.</p>	<p>A comprehensive review of viral posterior uveitis due to HHV, HIV, measles, rubella, arboviruses (dengue, chikungunya, Rift Valley virus, and WNV), and other rare causes such as influenza, Ebola, and ZIKV.</p> <p>Reports herpetic retinitis in patients following intraocular corticosteroid injections.</p> <p>Reports ARN due to HSV1 was common with HSV encephalitis whereas HSV2 was associated with HSV meningitis. VZV accounts for approximately half of ARN cases in non-HIV patients, more than one-third of ARN cases in HIV patients, and more than 70% of PORN cases. Complications of EBV include conjunctivitis, episcleritis, keratitis, iritis, optic neuritis, ARN, and retinal vasculitis.</p> <p>Posterior uveitis associated with EBV typically presents as chorioretinitis.</p> <p>EBV posterior uveitis is usually self-limiting as infectious mononucleosis.</p>
2017	<p>Heath G Depledge DP Brown JR <i>et al.</i></p>	<p>ARN Caused by the Zoster Vaccine Virus. <i>Clin Infect Dis.</i> 2017; 65(12):2122-2125.</p>	<p>Authors reported ARN caused by the vaccine Oka strain following immunization of a 78-year-old woman with live zoster vaccine. Whole genome sequencing confirmed the ocular vOka strain to be derived from the vaccine and excluded the presence of new mutations or recombination with wild-type VZV.</p>
2017	<p>Othman K Evelyn-Tai LM Raja-Azmi MN <i>et al.</i></p>	<p>Concurrent hyphema and orbital apex syndrome following HZO in a middle aged lady. <i>Int J Surg Case Rep.</i> 2017; 30:197-200.</p>	<p>A diabetic woman presented with total hyphema, and complete ophthalmoplegia suggestive of orbital apex syndrome two weeks after HZO. She was treated with combination of intravenous acyclovir and oral corticosteroids, and regained full recovery of ocular motility.</p>

2017	Hsia YC Chin-Hong PV Levin MH	Epstein-Barr Virus Neuroretinitis in a Lung Transplant Patient. J Neuro ophthalmol. 2017; 37(1):43-47.	The authors describe a case of bilateral EBV neuroretinitis following solid organ transplant. The diagnosis of EBV neuroretinitis was strongly supported by a high CSF EBV titer and the resolution of systemic symptoms, stabilization of vision loss, and a decline in CSF EBV viral load upon initiation of high-dose acyclovir.
2017	Yanai R Harada D Uchi SH <i>et al.</i>	Poor prognosis of elderly individuals >80 years of age with acute retinal necrosis. Am J Ophthalmol Case Rep. 2017; 7:107-112.	The authors studied 6 consecutive patients of unilateral ARN. VZV DNA was detected in aqueous by the PCR in all patients. All received intravenous acyclovir, oral steroids, valaciclovir and five of the six patients underwent vitrectomy. The BCVA of the affected eye was worse for the elderly patients than for the middle-aged patients.
2017	De Hoog J Ten Berge JC Groen F Rothova A	Rhegmatogenous retinal detachment in uveitis. J Ophthalmic Inflamm Infect. 2017; 7(1):22.	A retrospectively study amongst 851 uveitis patients, showed that RRD occurred in 26 patients (3.1%; 29 affected eyes) and was significantly associated with posterior uveitis ($p < 0.001$), infectious uveitis ($p < 0.001$), and male gender ($p = 0.012$). Among cases of infectious uveitis, CMV and VZV were most commonly associated with RRD.
2016	Sabhapandit S Murthy SI Balne PK Sangwan VS Sumanth V Reddy AK	Clinical spectrum, diagnostic criteria, and polymerase chain reaction of aqueous humor in viral and toxoplasma detection in Fuchs' uveitis syndrome. Indian J Ophthalmol. 2016; 64(8):555-558.	90 patients were enrolled in the study in three groups [Fuch's uveitis, anterior uveitis and no uveitis]. Serum and aqueous PCR was negative for detection of VZV, CMV, toxoplasma, and rubella in all groups. The authors concluded that the diagnosis of FU is mainly clinical. There was no role of aqueous humor testing for viruses by PCR to aid in etiological diagnosis.

2016	Keorochana N	A case report of Epstein-Barr virus-associated retinal vasculitis: successful treatment using only acyclovir therapy. Int Med Case Rep J. 2016; 9:213-218.	The authors describe a presumed case of EBV-associated retinal vasculitis. Vitreous PCR for viral DNA was positive for EBV. Intravenous acyclovir, 10 mg/kg/d, was prescribed for 14 days followed by oral acyclovir for 3 months. All lesions healed completely without recurrences.
------	---------------------	---	---

Viral uveitis: Laboratory Diagnosis

Year	Authors	Title and Journal	Salient Features
2020	Groen-Hakan F Van Der Eijk AA Rothova A	The Usefulness of Aqueous Fluid Analysis for Epstein-Barr Virus in Patients with Uveitis. Ocul Immunol Inflamm. 2020; 28(1):126-132.	Retrospective study of patients who underwent diagnostic aqueous fluid analysis. Low EBV-GWC values combined with multiple positive GWC and/or PCR for other infectious agents. Intraocular assessment for EBV in the initial examination of uveitis patients has limited value.
2020	Nakano S Tomaru Y Kubota T <i>et al.</i>	Evaluation of a Multiplex Strip PCR Test for Infectious Uveitis: A Prospective Multicenter Study. Strip PCR Project Group. Am J Ophthalmol. 2020 May; 213:252-259.	A novel multiplex PCR test (Strip PCR) for 24 common ocular infectious disease pathogens was established. 722 samples at 14 institutions were examined. Genomic DNA from aqueous humor and vitreous fluid was analyzed by qPCR and Strip PCR. Easy-to-use Strip PCR is recommended for rapid diagnosis of infectious uveitis, as its results are equivalent to that of conventional qPCR.
2019	Hsiao YT Kuo MT Chiang WY Chao TL Kuo HK	Epidemiology and clinical features of viral anterior uveitis in southern Taiwan- diagnosis with polymerase chain reaction. BMC Ophthalmol. 2019 Apr 3;19(1):87.	PCR analysis of the anterior chamber fluid is important for the confirmation of the diagnosis of viral anterior uveitis. CMV anterior uveitis is not uncommon in patients in southern Taiwan, and it may follow an uneventful cataract extraction in immunocompetent patients.

2019	Neumann R Barequet D Rosenblatt A <i>et al.</i>	Herpetic Anterior Uveitis - Analysis of Presumed and PCR Proven Cases. Ocul Immunol Inflamm. 2019;27(2):211-218.	Different HAU-causing Herpes viridae produce common clinical findings; therefore, PCR should be used more often to confirm specific diagnosis. Iris atrophy was associated with more severe disease. HSV eyes, compared to VZV, had a higher recurrence rate, corneal involvement, KPs, iris atrophy, elevated IOP and posterior synechia.
2019	De Simone L Belloni L Aldigeri R <i>et al.</i>	Aqueous tap and rapid diagnosis of cytomegalovirus anterior uveitis: the Reggio Emilia experience. Graefes Arch Clin Exp Ophthalmol. 2019 Jan;257(1):181-186.	The authors suggest that to improve the diagnostic accuracy of CMV anterior uveitis, PCR and intraocular antibody index (AI) are both useful and complimentary. In this series, AI was the most sensitive diagnostic tool. One single aqueous tap is sufficient to achieve 100% sensitivity in CMV diagnosis.
2019	Martín Ramírez A Cardeñoso Domingo L González Guijarro JJ	PCR Multiplex for CMV Detection in Patients with Anterior UveitiGs. Ocul Immunol Inflamm. 2019;27(2):197-202.	High intraocular pressure in anterior uveitis eyes should be considered for CMV-PCR aqueous analysis due to possible treatment modifications.
2019	Cao G Tan C Zhang Y <i>et al.</i>	Digital droplet PCR analysis of common viruses in the aqueous humour of patients with PS syndrome in Chinese population. Clin Exp Ophthalmol. 2019 May;47(4):513-520.	CMV was the leading cause of pathogen-induced PSSyndrome in the Chinese population. Digital droplet PCR (ddPCR) was a promising tool for early detection, accurate diagnosis and therapeutic validity monitoring of pathogen-induced PSS. The high sensitivity of ddPCR could avoid repeated anterior chamber tap.
2019	Smit D Meyer D Maritz J de Groot-Mijnes JDF	PCR and Goldmann-Witmer Coefficient to Examine the Role of EBV in Uveitis. Ocul Immunol Inflamm. 2019;27(1):108-113.	The authors found no evidence of active intraocular replication or antibody production to prove that EBV caused uveitis. In most cases an alternative treatable cause of uveitis was identified.

2019	Smit DP Meyer D Esterhuizen TM De Groot-Mijnes JDF	PCR and Goldmann-Witmer Coefficient Testing in the Diagnosis of Infectious Uveitis in HIV-Positive and HIV-Negative Patients in South Africa. Ocul Immunol Inflamm. 2019;27(2):189-196.	<p>PCR is useful to diagnose herpetic non-anterior uveitis (NAU) in HIV+ patients while GWC is useful to diagnose herpetic anterior uveitis.</p>
2019	Minkus CL Bispo PJM Papaliadis GN Sobrin L	Real-Time Multiplex PCR Analysis in Infectious Uveitis. Semin Ophthalmol. 2019;34(4):252-255.	<p>Real-time multiplex PCR is a highly sensitive and specific laboratory assay that allows for rapid and reliable molecular diagnosis of causative agents in infectious uveitis. This in turn facilitates swift initiation of effective therapy and prevents long-term ocular damage and vision loss.</p>
2018	Bispo PJM Davoudi S Sahm ML <i>et al.</i>	Rapid Detection and Identification of Uveitis Pathogens by Qualitative Multiplex Real-Time PCR. Invest Ophthalmol Vis Sci. 2018 Jan 1;59(1):582-589.	<p>The authors developed and validated a multiplex real-time PCR assay coupled with high-resolution melting (HRM) for rapid detection and identification of HSV-1 and HSV-2, VZV, CMV and T. gondii. This assay allowed rapid, sensitive, and reliable detection and identification of the most common known causes of infectious uveitis.</p>
2018	Choi RY Lauer A Rosenbaum JT	Molecular diagnosis and ocular imaging of varicella zoster virus associated neuroretinitis. Am J Ophthalmol Case Rep. 2018 Jul 18;11:146-148.	<p>The authors report for the first time a case of VZV associated neuroretinitis confirmed by PCR of ocular fluid with imaging.</p>

2018	Kharel Sitaula R Janani MK Madhavan HN Biswas J	Outcome of polymerase chain reaction (PCR) analysis in 100 suspected cases of infectious uveitis. J Ophthalmic Inflamm Infect. 2018 Jan 10;8(1):2.	A retrospective, interventional study of PCR analysis of ocular fluid in suspected infectious uveitis cases from January 2014 to July 2016. PCR assay was found to be an accurate technique with high sensitivity and specificity to diagnose the DNA genome in infectious uveitis.
2018	Ten Berge JC Schreurs MW van Rosmalen J Rothova A	Autoantibody profiling in intraocular fluid of patients with uveitis. Exp Eye Res. 2018 Nov;176:141-146.	High elevations of intraocular anti-ocular antibodies (AOcAs) in uveitis were observed in VZV-induced uveitis, multiple sclerosis-associated uveitis and patients with unexplained uveitis but with a positive quantiferon test. Patients with uveitis are characterized by the presence of a broad spectrum of moderately elevated levels of intraocular AOcAs, and high intraocular AOcA levels were found in several specific uveitis entities.
2018	Keorochana N Intaraprasong W Choontanom R	Herpesviridae prevalence in aqueous humor using PCR. Clin Ophthalmol. 2018 Sep 7;12:1707-1711.	This study showed previous HSV, VZV, EBV and CMV infections by positive serological tests in 90% of the Thai population, while no viral presence was detected in aqueous humor. The serology test was unrelated to the presence of virus in the eye.
2018	Miyazaki D Shimizu D Shimizu Y <i>et al.</i>	Diagnostic efficacy of real-time PCR for ocular cytomegalovirus infections. Real-time PCR for ocular cytomegalovirus infection study group. Graefes Arch Clin Exp Ophthalmol. 2018 Dec;256(12): 2413-2420.	Quantitative real-time PCR (qPCR) with standardization was specific and accurate in CMV infections; the knowledge of clinical characteristics improve the diagnostic efficacy.

2018	Waduthantri S Zhou L Chee SP	Intra-cameral level of ganciclovir gel, 0.15% following topical application for cytomegalovirus anterior segment infection: A pilot study. PLoS One. 2018 Jan 29;13(1):e0191850.	<p>In patients with CMV anterior uveitis and endothelitis treated with ganciclovir gel 0.15%, CMV load in the aqueous humor was measured using CMV RT-PCR and the ganciclovir drug levels in tears and aqueous humor were measured using high-performance liquid chromatography-mass spectrometry. Ganciclovir levels in the aqueous humor was below the 50% inhibitory dose (ID50) for CMV replication, following topical application of the ganciclovir gel, 0.15%.</p>
2018	Rao V Biswas J Lingam G	Real-time polymerase chain reaction in acute retinal necrosis following encephalitis. Indian J Ophthalmol. 2018 Feb;66(2):322-324.	<p>A patient with ARN following HSV encephalitis, managed with intravenous acyclovir and intravitreal ganciclovir, the retinitis healed and the qPCR confirmed a reduction in the viral load. qPCR has a high sensitivity and specificity for HSV and is a useful tool for diagnosis and treatment of viral retinitis.</p>
2017	Lee JH Agarwal A Mahendradas P <i>et al.</i>	Viral posterior uveitis. Surv Ophthalmol. 2017;62(4):404-445.	<p>The tetraplex PCR analysis of intraocular fluids for HSV, VZV, and CMV is effective in confirming pathogen in 59–100% of cases with PCR having a sensitivity of 80.9%–84.0% and a specificity of 97.4%–100.0%. Tetraplex PCR has a greater sensitivity and specificity than the GWC analysis in the diagnosis of herpes viruses.</p>

2017	<p>Hosogai M Nakatani Y Mimura K Kishi S Akiyama H</p>	<p>Genetic analysis of varicella-zoster virus in the aqueous humor in uveitis with severe hyphema. BMC Infect Dis. 2017;17(1):427.</p>	<p>VZV-associated uveitis may develop hyphema that obscures ocular inflammation, Aqueous PCR analysis can help in diagnosis and monitor therapeutic effects. The genetic analysis of multiple open reading frames and the R5 variable repeat region in the VZV genes, using DNA extracted from the aqueous humor at presentation, showed that the isolate was a wild-type clade 2 VZV strain (prevalent in Japan and surrounding countries) with R5A allele and one SNP unique to clade 1 (both are major types in Europe and North America).</p>
2017	<p>Choi JA Kim JE Noh SJ Kyoung Kim E Park CK Paik SY</p>	<p>Enhanced cytomegalovirus infection in human trabecular meshwork cells and its implication in glaucoma pathogenesis. Sci Rep. 2017;7:43349.</p>	<p>Active viral infection in human TM cells could be the key mechanism underlying the elevation of IOP in anterior viral uveitis. Notably, CMV infection enhanced the production of transforming growth factor (TGF)-β1, an upstream molecule that increases the resistance of the outflow pathway in human TM cells. The increase of TGF-β1 was counterbalanced by additional treatment with corticosteroids.</p>
2016	<p>Chronopoulos A, Roquelaure D Souteyrand G Seebach JD Schutz JS Thumann G</p>	<p>Aqueous humor polymerase chain reaction in uveitis - utility and safety. BMC Ophthalmol. 2016;16(1):189.</p>	<p>Records of 45 consecutive patients with anterior and posterior uveitis who underwent aqueous PCR for HSV, VZV, CMV, EBV and Toxoplasma gondii were reviewed. The overall PCR positivity was 48.9 % (22/45). Therapy was changed because of the PCR results in 14/45 patients (37.7 %). The authors concluded that, aqueous PCR altered the diagnosis and treatment in over a third of patients and was relatively safe. Aqueous PCR should be considered for uveitis of atypical clinical appearance, recurrent severe uveitis of uncertain etiology, and therapy refractory cases.</p>

2016	Doan T Wilson MR Crawford ED <i>et al.</i>	Illuminating uveitis: metagenomic deep sequencing identifies common and rare pathogens [published correction appears in Genome Med. 2016 Nov 22; 8(1):123. Genome Med. 2016; 8(1):90.	This study aimed to determine if unbiased MDS can accurately detect pathogens in intraocular fluid samples of patients with uveitis. It concluded that, MDS can identify fungi, parasites, and DNA and RNA viruses in minute volumes of intraocular fluid samples. The identification of chronic intraocular rubella virus infection highlights the eye's role as a long-term pathogen reservoir, with implications for virus eradication.
2016	Choi JA Kim KS Jung Y Park HY Park CK	CMV as a cause of hypertensive anterior uveitis in immunocompetent patients. J Ophthalmic Inflamm Infect. 2016;6(1):32.	21 patients underwent aqueous humor sampling. CMV DNA was detected in 6 of these cases and 15 samples were negative. The corneal endothelial cell counts were significantly lower in the CMV-positive group (CMV positive vs. CMV negative, 1245 ± 560 vs. 1981 ± 387 cells/mm ² ; P = 0.009).

Viral uveitis and Ocular Imaging

Year	Authors	Title and Journal	Salient Features
2019	Kodati S Gangaputra S Sen HN	Multimodal Imaging of Post-Infectious Unilateral Outer Retinopathy and Choroiditis. Ocul Immunol Inflamm. 2019;27(6):927-931.	A case of unilateral outer retinopathy with an optic neuropathy, small vessel vasculitis, and choroiditis following a viral infection was described. The authors concluded that, in the presence of a negative work up, a post-infectious etiology should be considered in the differential of posterior uveitis.
2019	Hashida N Asao K Maruyama K Nishida K	Cornea Findings of Spectral Domain Anterior Segment OCT in Uveitic Eyes of Various Etiologies. Cornea. 2019 Oct;38(10):1299-1304.	AS-OCT image analysis can identify various causes of uveitic diseases based on specific morphological patterns of KPs and can monitor the course on treatment.

2018	<p>Costa de Andrade G Marchesi Mello LG Martines GC Maia A</p>	<p>OCT angiography findings in acute retinal necrosis. Retin Cases Brief Rep. 2018;10.1097/ICB.0000000000000778.</p>	<p>Occlusive arterial vasculopathy is one of the main clinical characteristics of ARN. The authors herein describe for the first time the features of retinal vasculature in ARN. OCTA revealed decreased vascular density of superficial and deep plexuses.</p>
2017	<p>Lee JH Agarwal A Mahendradas P <i>et al.</i></p>	<p>Viral posterior uveitis. Surv Ophthalmol. 2017;62(4):404-445.</p>	<p>In the acute phase of ARN, OCT shows inner retina hyper-reflectivity with disorganization of the retinal structure, corresponding to areas of retinal necrosis with/without subretinal exudates and macular edema. With resolution, there is marked inner and outer retina thinning within areas of retinal necrosis and resolution of the hyper-reflectivity consistent with retinal tissue loss and scar formation</p> <p>In PORN, although clinically it appears as an outer retinal necrosis, OCT shows widespread full thickness neurosensory retina loss. At presentation, there is extensive perifoveal retinal thickening with hyper-reflectivity corresponding to the retinal edema and posterior shadowing. At resolution, there is total loss of identifiable retina layers corresponding to areas of retinal necrosis.</p>
2017	<p>Akanda M Gangaputra S Kodati S Melamud A Sen HN</p>	<p>Multimodal Imaging in Dengue-Fever-Associated Maculopathy. Ocul Immunol Inflamm. 2018; 26(5):671-676.</p>	<p>OCT findings of dengue maculopathy include hyper-reflectivity of the outer nuclear layer (ONL) and outer plexiform layer (OPL) in the acute phase, followed by irreversible outer segment disruption and outer nuclear layer thinning that persist long term with scotomas even after visual recovery.</p>

2017	Tripathy K Chawla R Mittal K Farmania R Venkatesh P Gulati S	Ophthalmic examination as a means to diagnose Subacute Sclerosing Panencephalitis: an optical coherence tomography and ultrawide field imaging evaluation. Eye Vis (Lond). 2017; 4:1.	A 12-year-old boy diagnosed with SSPE UWFA showed capillary non-perfusion, drop out of retinal vessels and arteriovenous loop (star) formation. OCT showed retinal atrophy with overlying detached internal limiting membrane which progressed to cavitary changes in outer retina and retinal thinning.
	Gupta MP Patel S Orlin A <i>et al.</i>	Spectral domain optical coherence tomography findings in macula-involving cytomegalovirus retinitis. Retina. 2018;38(5):1000-1010.	Microstructural abnormalities were frequently noted on OCT of CMV retinitis, including in the outer retina layers beyond the leading edge of retinitis.
2016	Balci O Ozsutcu M	Evaluation of Retinal and Choroidal Thickness in Fuchs' Uveitis Syndrome. J Ophthalmol. 2016;2016:1657078.	Affected eyes in patients with FUS tend to have thinner choroids as compared to eyes of unaffected fellow eyes and healthy individuals, which might be a result of the chronic inflammation associated with the disease.

Viral uveitis: Management

Year	Authors	Title and Journal	Salient Features
2019	Hänsli C Meier F Barthelmes D Böni C	Prophylaxis of Recurrent Cytomegalovirus Uveitis with Topical Ganciclovir. Klin Monbl Augenheilkd. 2019 Apr;236(4):511-515.	Topical ganciclovir was found to be an effective treatment. Inflammatory activity was well controlled by using an individually assessed prophylactic dose. But authors recommended a larger prospective study.

2019	Choi JA Kim JE Ju HH <i>et al.</i>	The effects of losartan on cytomegalovirus infection in human trabecular meshwork cells. PLoS One. 2019 Jun 19;14(6):e0218471.	Losartan inhibited the expression of TGF- β 1 and fibrogenic molecules in human TM cells. Thus, losartan has the potential to decrease TM fibrosis in patients with CMV-induced hypertensive anterior uveitis.
2019	Ivert LU Wahlgren CF Ivert L Lundqvist M Bradley M	Eye Complications During Dupilumab Treatment for Severe Atopic Dermatitis. Acta Derm Venereol. 2019 Apr 1;99(4):375-378.	Conjunctivitis, recurrence of HSV uveitis and VZV meningitis were the adverse effects noted with Dupilumab, the first biologic approved for treatment of atopic dermatitis. Modification of immunological signal pathways may interfere with defense against viral infections, as has been described in patients with rheumatoid arthritis and ulcerative colitis treated with JAK inhibitors.
2018	Zandi S Bodaghi B Garweg JG	Review for Disease of the Year: Treatment of Viral Anterior Uveitis: A Perspective. Ocul Immunol Inflamm. 2018;26(7):1135-1142.	Oral acyclovir, valacyclovir, and famciclovir are the mainstay of treatment for HSV- and VZV-induced infections. Brivudin serves as an alternative in insufficiently responsive cases. CMV-induced infections responded well to valganciclovir. A prophylactic treatment for 3 to 12 months against recurrences was considered.
2018	Zhao XY Xia S Chen YX	Role of diagnostic pars plana vitrectomy in determining the etiology of uveitis initially unknown. Retina. 2018;10.1097/IAE.0000000000002372.	To estimate the success and safety of diagnostic pars plana vitrectomy (PPV) in determining the etiology of uveitis. Among patients whose diagnostic PPV yielded a definitive diagnosis, 69% were infectious uveitis, the most frequent pathogen was viruses.
2017	Lee JH Agarwal A Mahendradas P <i>et al.</i>	Viral posterior uveitis. Surv Ophthalmol. 2017;62(4):404-445.	Oral antivirals such as valacyclovir and famciclovir have greater bioavailability and systemic concentrations similar to that of IV acyclovir allowing outpatient management of HSV and VZV associated posterior uveitis.

2017	Patel CV Kishore K	Concomitant Intravitreal Ganciclovir and Dexamethasone Therapy in the Management of ARN in a Patient Previously Treated with Oral Famciclovir. Case Rep Ophthalmol Med. 2017;2017:4613624.	A case report of unilateral ARN following HZO 5 weeks prior which was treated with oral famciclovir. VZV DNA was detected by PCR from the aqueous. He was treated with intravitreal ganciclovir and dexamethasone injection and oral valacyclovir with complete resolution of necrotizing retinal lesions in 2 months.
2016	Wong JX Agrawal R Wong EP Teoh SC	Efficacy and safety of topical ganciclovir in the management of CMV-related anterior uveitis. J Ophthalmic Inflamm Infect. 2016;6(1):10.	Topical ganciclovir may be beneficial in reducing the frequency of recurrence in patients with CMV anterior uveitis, but it was not statistically associated with prolonging the time-to-recurrence. The time-to-quiescence was also not significantly affected by topical ganciclovir.
2016	Choopong P Vivittaworn K Konlakij D Thoongsuwan S Pituksung A Tesavibul N	Treatment outcomes of reduced-dose intravitreal ganciclovir for CMV retinitis. BMC Infect Dis. 2016;16:164. Published 2016 Apr 18.	Reduced-dose intravitreal ganciclovir (2 mg/0.04 mL) was a safe and effective treatment option. It provided comparable results to other weekly regimens. Induction with intravenous ganciclovir was not crucial in a resolution of retinitis, although it may be necessary to reduce systemic cytomegalovirus loads and mortality rates.

Emerging viral uveitis (2016 to 2020)

Year	Authors	Title and Journal	Salient Features
2016	Vetter P Dayer JA Schibler M <i>et al.</i>	The 2014–2015 Ebola outbreak in West Africa: Hands On. Antimicrob Resist Infect Control. 2016;5:17. Published 2016 May 5.	Anterior uveitis and panuveitis were the most common subtypes of the disease. Aqueous humour of the eye has been tested positive for 10 weeks after onset of disease, in a patient presenting with severe uveitis, while no virus could be retrieved in the tears/ conjunctival swab.

2016	Gargouri S Khohtali S Zina S <i>et al.</i>	Ocular involvement associated with varicella in adults. J Ophthalmic Inflamm Infect. 2016;6(1):47.	Ocular manifestations with chicken pox in adults included acute anterior uveitis in four eyes, with associated stromal keratitis in one of them, epithelial ulcerative keratitis in the two eyes of one patient, and acute retinal necrosis in one eye.
2017	Lee JH Agarwal A Mahendradas P <i>et al.</i>	Viral posterior uveitis. Surv Ophthalmol. 2017;62(4):404-445.	Features of EBV posterior uveitis include relative afferent pupillary defect, mild anterior chamber inflammation, vitritis, chorioretinitis, yellow-white fluffy retinal opacifications, multifocal choroiditis, localized choroidal effusions, hemorrhage, vasculitis, and optic neuritis. Rare findings of EBV infection include subretinal fibrosis and punctate outer retinitis with retinal pigment epithelial clumping and depigmentation.
2017	Shantha JG Crozier I Hayek BR <i>et al.</i>	Ophthalmic Manifestations and Causes of Vision Impairment in Ebola Virus Disease Survivors in Monrovia, Liberia. Ophthalmology. 2017;124(2):170-177.	A total of 96 survivors of EVD were examined. A total of 21 patients developed an EVD-associated uveitis, and 3 patients developed an EVD-associated optic neuropathy.
2017	Shantha JG Crozier I Yeh S	An update on ocular complications of Ebola virus disease. Curr Opin Ophthalmol. 2017;28(6):600-606.	Uveitis is the most common finding during EVD convalescence and leads to severe vision impairment or blindness in 40% of affected individuals. Ocular complications includes cataract, retinal scarring, optic neuropathy, hypotony and phthisis bulbi.
2017	Smith JR Todd S Ashander LM <i>et al.</i>	RPE Cells are a Potential Reservoir for Ebola Virus in the Human Eye. Transl Vis Sci Technol. 2017;6(4):12.	Human RPE cells were permissive to infection with Ebola virus, and supported viral replication and release of virus in high titer.

2017	Majumder PD Ghosh A Biswas J	Infectious uveitis: An enigma. Middle East Afr J Ophthalmol. 2017;24(1):2-10.	The authors have reviewed the emerging viral infectious uveitis including dengue, chikungunya and WNV. The clinical presentations, diagnosis and management are discussed.
2017	Imai A Takase H Imadome KI <i>et al.</i>	Development of Extranodal NK/T-cell Lymphoma Nasal Type in Cerebrum Following EBV positive Uveitis. Intern Med. 2017;56(11):1409-1414.	A 74-year-old woman developed bilateral uveitis with high EBV DNA load in the vitreous fluid without lymphoma cells. Four years after the onset, T2-weighted contrast-enhanced MRI revealed hyperintense lesions in the right occipital and parietal lobe. A biopsy resulted in the diagnosis of extranodal NK/T-cell lymphoma nasal type (ENKL). The repeat region of <i>LMP1</i> , an EBV gene, detected in the brain lesion was identical to that detected in the vitreous fluid.
2017	Platt DJ Miner JJ	Consequences of congenital Zika virus infection. Curr Opin Virol. 2017;27:1-7.	Congenital ZIKV infection in humans causes a variety of ocular abnormalities including chorioretinal atrophy, optic neuritis, retinal hemorrhages, lens subluxation, retinal mottling, and bilateral iris coloboma. ZIKV infection in adult humans causes nonpurulent conjunctivitis (55%) and rarely uveitis.
2017	de Andrade GC Ventura CV Mello Filho PA Maia M Vianello S Rodrigues EB	Arboviruses and the eye. Int J Retina Vitreous. 2017;3:4.	The authors have summarised the ocular features due to arboviruses CHIKV, DFV and ZIKV. Anterior uveitis, optic neuritis, and retinitis are the most common manifestations during the acute infection.

2017	<p>Yepez JB Murati FA Pettito M <i>et al.</i></p>	<p>Ophthalmic Manifestations of Congenital Zika Syndrome in Colombia and Venezuela. JAMA Ophthalmol. 2017;135(5):440-445.</p>	<p>43 patients were included in this series. All patients had bilateral ophthalmic manifestations. Optic nerve findings included hypoplasia with the double-ring sign, pallor, and increased cup-disc ratio in 11.6%. Macular abnormalities in 63% and lacunar maculopathy in 6.9%.Chorioretinal scarring in 7%. 26% had a combination of lesions in the posterior pole and 12% were diagnosed with congenital glaucoma.</p>
2017	<p>Aleman TS Ventura CV Cavalcanti MM <i>et al.</i></p>	<p>Quantitative Assessment of Microstructural Changes of the Retina in Infants With Congenital Zika Syndrome. JAMA Ophthalmol. 2017;135(10):1069-1076.</p>	<p>A study of 8 infants with congenital zika syndrome. All 8 had foveal abnormalities including discontinuities of the ellipsoid zone, thinning of the central retina with increased backscatter, and severe structural disorganization and macular pseudocolobomas in 3 eyes. Pericentral retina with normal lamination showed a thinned (<30% of normal thickness) ganglion cell layer (GCL) with more or less normal photoreceptor layer and inner nuclear layer.</p>
2017	<p>Roy S Takkar B Chawla R Kumar A</p>	<p>Macular phlebitis in a case of dengue retinopathy. BMJ Case Rep. 2017;2017: bcr2017221362.</p>	<p>A 32-year-old woman with dengue fever a week prior to presentation, was diagnosed with bilateral macular phlebitis. FFA showed tortuous macular venules with dye leakage in late phase. OCT showed CME in both eyes with SRF in the left eye. The patient was treated with oral prednisolone and had complete resolution of vascular tortuosity, inflammation and restoration of vision at 1 month.</p>

2017	Benage M Fraunfelder FW	Vaccine-Associated Uveitis. <i>Mo Med.</i> 2016;113(1):48-52.	A total of 289 cases of vaccine-associated uveitis were reported between 1984 and 2014 from the National Registry of Drug-Induced Ocular Side Effects (www.eyedrugregistry.com), the WHO Monitoring Centre (Uppsala, Sweden), and the FDA spontaneous reporting system (Bethesda, MD). Vaccines most commonly reported in association with uveitis were as follows, in descending order of frequency: hepatitis B vaccine, 115 cases; HPV vaccine, 44 cases; influenza vaccine, 28 cases; BCG vaccine, 21 cases; and MMR vaccine and varicella vaccine, 13 cases each.
2018	Kumar JS Saxena D Parida M Rathinam S	Evaluation of real-time reverse-transcription loop-mediated isothermal amplification assay for clinical diagnosis of West Nile virus in patients. <i>Indian J Med Res.</i> 2018; 147(3): 293-298.	The RT-LAMP test was a sensitive and specific method for rapid detection of WNV infection and would be useful for rapid screening of a large number of clinical samples in endemic areas during outbreaks.
2018	Lin J Chen RWS Hazan A Weiss M	Chikungunya Virus Infection Manifesting as Intermediate Uveitis. <i>Ocul Immunol Inflamm.</i> 2018; 26(5):680-682.	AU and retinitis are the most common ocular manifestations of chikungunya infection, the authors report a case of chikungunya infection presenting as an intermediate uveitis, responding well to oral corticosteroids.
2018	Rocha VFD de Oliveira AHP Bandeira AC <i>et al.</i>	Chikungunya Virus Infection Associated with Encephalitis and Anterior Uveitis. <i>Ocul Immunol Inflamm.</i> 2018;26(5):677-679.	A case of a 57-year-old man with meningoencephalitis and AU. The patient developed bilateral anterior uveitis with iris atrophy and a cotton wool spot in the left eye, and his serum, urine, saliva, and CSF were positive for Chikungunya virus by RT-PCR.

2018	Cunningham ET Jr, Khairallah M Rathinam SR Belfort R Jr Zierhut M	Mosquito-Borne Uveitis. Ocul Immunol Inflamm. 2018;26(5):651-653.	One review, two original articles and five letters address various aspects of the diagnosis, clinical characteristics, management and outcome of eyes with uveitis following mosquito-borne viral infections including Zika, Chikungunya, West Nile virus and dengue.
2018	Ulloa-Padilla JP Dávila PJ Izquierdo NJ García-Rodríguez O Jiménez IZ	Ocular Symptoms and Signs of Chikungunya Fever in Puerto Rico. P R Health Sci J. 2018 Jun; 37(2):83-87.	Patients with confirmed IgM (ELISA) positivity manifested with red eyes, conjunctivitis, and anterior uveitis. The relevance of this study lies in the fact that this disease remains an important public health issue.
2018	Merle H Donnio A Jean-Charles A et al.	Ocular manifestations of emerging arboviruses: Dengue fever, Chikungunya, Zika virus, West Nile virus, and yellow fever. J Fr Ophtalmol. 2018 Jun;41(6):e235-e243.	The goal of this review was to describe the ophthalmological manifestations of Dengue fever, Chikungunya virus, Zika virus, West Nile virus, and yellow fever.
2018	Agrawal R Oo HH, Balne PK Ng L Tong L Leo YS	Zika Virus and the Eye. Ocul Immunol Inflamm. 2018;26(5):654-659.	Ocular manifestations were mild in adults with nonpurulent conjunctivitis, uveitis, maculopathy, and hypertensive iridocyclitis. Ocular signs were more significant in congenital ZIKV-macular pigment mottling, neuroretinal atrophy with macular involvement, iris coloboma, and changes in retinal vasculature.
2018	Manangeeswaran M Kielczewski JL Sen HN et al.	ZIKA virus infection causes persistent chorioretinal lesions. Emerg Microbes Infect. 2018 May 25;7(1):96.	The authors describe the partial recovery of chorioretinal lesions in an immunocompetent patient diagnosed with bilateral posterior uveitis associated with Zika infection and show that some lesions resolved with focal atrophy evident as pigmentary changes on funduscopy.

2018	Singh MS Marquezan MC Omiadze R Reddy AK Belfort R Jr May WN	Inner retinal vasculopathy in Zika virus disease. Am J Ophthalmol Case Rep. 2018 Jan 17;10:6-7.	In addition to outer retinal abnormalities which are well-described in infants and adults, inner retinal vascular abnormalities may also occur and may be temporally associated with post-viral neurological sequelae of Zika virus infection.
2018	Singh S Kumar A	Ocular Manifestations of Emerging Flaviviruses and the Blood-Retinal Barrier. Viruses. 2018 Sep 28;10(10):530.	This article discusses how flaviviruses modulate retinal innate response and breach the protective BRB to cause ocular or retinal pathology. Recently identified infection signatures of ZIKV are described and it discusses whether these system biology-predicted genes or signaling pathways could contribute to the pathogenesis of ocular manifestations and assist in the development of ocular antiviral therapies against ZIKV and other flaviviruses.
2018	Yeh S Shantha JG Hayek B Crozier I Smith JR	Clinical Manifestations and Pathogenesis of Uveitis in EBV Disease Survivors. Ocul Immunol Inflamm. 2018;26(7):1128-1134.	Clinical studies in EVD survivors, animal models of EVD and translational investigation, have provided early insight into eye disease pathogenesis. Specifically, ocular inflammation observed in EVD survivors was thought to involve direct viral infection, inflammation, and tissue edema. Future research was suggested to understand the timing of uveitis onset and management strategies, including the role of antiviral and anti-inflammatory therapies.
2018	Ito T Hoshina T Mizuki K Fukuda T Ishibashi S Kusuhara K	A pediatric case with parvovirus B19-associated uveitis without autoantibody formation. Nagoya J Med Sci. 2018 Nov;80(4):611-614.	Uveitis is rarely caused by B19. Autoantibody formation was confirmed in 2 previously reported cases with B19-associated uveitis. However, whether B19-associated uveitis is caused by the direct invasion of the virus or the induction of autoimmunity remains unclear.

2018	Shah A Babu R Biswas J	Retinitis as the presenting feature of subacute sclerosing panencephalitis in an Indian male: A case report. Indian J Ophthalmol. 2018 Oct;66(10):1491-1493.	A case report of a young Indian male with acute viral retinitis who subsequently developed SSPE. It is important to consider measles virus and SSPE as a cause in an immunocompetent young adult with necrotizing viral retinitis.
2018	Okada A Harada Y Inoue T Okikawa Y Ichinohe T Kiuchi Y	A case of primary extranodal natural killer/T-cell lymphoma in the orbit and intraocular tissues with cerebrospinal fluid involvement. Am J Ophthalmol Case Rep. 2018 May 17;11:37-40.	ENKTL should be considered differential diagnosis in patients with steroid-resistant orbital tumors. In the event of anterior uveitis or vitritis with an orbital mass lesion at presentation, orbital incisional biopsy, as well as quantitative PCR for EBV-DNA using aqueous or vitreous humor samples, is essential to facilitate an early diagnosis.
2018	De Groot-Mijnes JDF Chan ASY Chee SP Verjans GMGM	Immunopathology of Virus-Induced Anterior Uveitis. Ocul Immunol Inflamm. 2018;26(3):338-346.	Viral infections are commonly associated with ocular infiltration of T cells and B/plasma cells, and expression of cytokines and chemokines typical of a proinflammatory immune response. The infections differ in that the herpes viruses cause an acute lytic infection and inflammation, whereas rubella virus is a chronic low-grade infection with slowly progressing immunopathological responses.
2019	Vairo F Haider N Kock R Ntoumi F Ippolito G Zumla A	Chikungunya: Epidemiology, Pathogenesis, Clinical Features, Management, and Prevention. Infect Dis Clin North Am. 2019 Dec;33(4):1003-1025.	Serious complications associated with CHIK viral infection included myocarditis, uveitis, retinitis, hepatitis, acute renal disease, severe bullous lesions, meningoencephalitis, Guillain-Barré syndrome, myelitis, and cranial nerve palsies. Treatment was supportive; there is no specific antiviral treatment and no effective vaccine.

2019	Jimenez P Kestelman E Kestelman B Vizzoni AG Cerbino-Neto J Curi ALL	Multifocal Choroiditis Secondary to Acute Zika Virus Infection. Ocul Immunol Inflamm. 2019 Sep 30:1-4.	Ophthalmological examination in a patient during acute episode of Zika Virus infection revealed multifocal choroiditis in both eyes. Lesions improved and visual acuities returned to normal level without any treatment.
2019	Oliver GF Carr JM Smith JR	Emerging infectious uveitis: Chikungunya, dengue, Zika and Ebola: A review. Clin Exp Ophthalmol. 2019 Apr;47(3):372- 380.	Anterior, intermediate, posterior and pan-uveitis have been described in individuals infected with CHIKV. Maculopathy is a common manifestation of dengue eye disease, and Zika eye disease may cause hypertensive anterior uveitis or mimic a white dot syndrome. Up to one-third of Ebola survivors develop aggressive uveitis, which is frequently associated with vision loss and complicated by cataract. There are no specific anti-viral drugs for these forms of uveitis, and thus treatment is largely supportive.
2019	Sneller MC Reilly C Badio M <i>et al.</i>	A Longitudinal Study of Ebola Sequelae in Liberia. PREVAIL III Study Group, N Engl J Med. 2019 Mar 7;380(10):924-934.	This was a longitudinal study among 966 antibody positive Ebola survivors and 2305 antibody negative close contacts (controls). At baseline, 149 survivors (26.4%) had evidence of uveitis in at least one eye, as compared with 77 controls (12.1%) ($P < 0.0001$). Among these participants, 30 survivors (5.3%) and 13 controls (2.0%) had active uveitis ($P = 0.003$). The prevalence of uveitis increased to 33.3% in survivors at one year.
2019	Oliver GF Orang AV Appukuttan B <i>et al.</i>	Expression of microRNA in human retinal pigment epithelial cells following infection with Zaire ebolavirus. BMC Res Notes. 2019 Oct 1;12(1):639.	The authors studied the impact of miRNA changes in EBOV-infected RPE cells to further understanding of intraocular viral persistence and the pathogenesis of uveitis in EVD survivors.

2019	Kamoi K Okayama A Izumo S <i>et al.</i>	Adult T-Cell Leukemia/ Lymphoma-Related Ocular Manifestations: Analysis of the First Large-Scale Nationwide Survey. <i>Front Microbiol.</i> 2019 Jan 8;9:3240.	Intraocular infiltration and cytomegalovirus retinitis are common among manifestations in Adult T-cell leukemia/lymphoma patients.
2019	Yang CS Hsieh MH Su HI Kuo YS	MEWDS Following Acute EBV Infection. <i>Ocul Immunol Inflamm.</i> 2019;27(2):244-250.	During acute onset of MEWDS in 5 cases, EBV infection was confirmed by positive EBV serology test. MEWDS may be associated with acute systemic EBV infection. Ocular symptoms may be due to infection or virus-induced autoimmune inflammatory retinitis.
2019	Takahashi H Takase H Arai A Mochizuki M Ohno-Matsui K	Bilateral granulomatous panuveitis in two patients with T-cell type of chronic active EBV infection. <i>BMC Ophthalmol.</i> 2019 Mar 29;19(1):83.	Granulomatous panuveitis can develop in eyes with chronic active EBV (CAEBV) as a primary symptom (2 cases). Ophthalmologists should rule out CAEBV when EBV-DNA is positive in the intraocular fluids of steroid-resistant panuveitis.
2019	Kumar JS Rathinam S Karithia D Parida M	Cloning, expression & evaluation of potential immunogenic recombinant capsid premembrane protein of West Nile virus. <i>Indian J Med Res.</i> 2019;149(5):656-661.	The recombinant CprM protein-based WNV-specific ELISA reported in this study may be useful for rapid screening of large numbers of blood samples in endemic areas during outbreaks with sensitivity and specificity of 100 and 97 per cent, respectively
2020	Hartley C Bavinger JC Kuthyar S Shantha JG Yeh S	Pathogenesis of Uveitis in EBV Disease Survivors: Evolving Understanding from Outbreaks to Animal Models. <i>Microorganisms.</i> 2020 Apr 20;8(4):594.	Retrospective and more recent prospective studies of ebola virus disease? (EVD) survivors from West Africa show that uveitis occurs in 13–34% of patients. Prevalence increases from baseline to 12-month follow-up. The uveitis may be mild AU to severe, sight-threatening panuveitis.

2020	Rojas M Monsalve DM Pacheco Y <i>et al.</i>	Ebola virus disease: An emerging and re- emerging viral threat. J Autoimmun. 2020 Jan; 106:102375.	<p>The article describes a "Post-Ebola virus disease syndrome" that resembles inflammatory and autoimmune conditions with uveitis. The mechanisms include a high formation of neutrophil extracellular traps, an uncontrolled "cytokine storm", and formation of auto-antibodies. The molecular biology, pathogenesis, clinical manifestations, and treatment of EBV disease are discussed.</p>
2020	Kamoi K Okayama A Izumo S <i>et al.</i>	Tackling HTLV-1 infection in ophthalmology: a nationwide survey of ophthalmic care in an endemic country, Japan. Br J Ophthalmol. 2020 Mar 9; bjophthalmol -2019-315675.	<p>In ophthalmology, awareness of the association between HTLV-1 infection and uveitis has been increasing since the 1990s. Here, the authors describe a nationwide survey and analysis of the current state of medical care for HTLV-1-associated uveitis (HAU) at ophthalmic facilities in Japan. Facilities with experience in providing medical care for HAU accounted for 67.6% while 85.5% of facilities had seen no decrease in the number of patients with HAU.</p>
2020	Seah I Agrawal R	Can the Coronavirus Disease 2019 (COVID-19) Affect the Eyes? A Review of Coronaviruses and Ocular Implications in Humans and Animals. Ocul Immunol Inflamm. 2020 Apr 2;28(3):391-395.	<p>CoVs are capable of producing a wide spectrum of ocular manifestations from anterior segment pathologies like conjunctivitis and anterior uveitis to sight-threatening conditions like retinitis and optic neuritis. CoVs can also develop in-vivo mutations which drastically alter the manifestations of the disease.</p>

2020	<p>Hung JCH Li KKW</p>	<p>Implications of COVID-19 for uveitis patients: perspectives from Hong Kong. Hung JCH, Li KKW. Eye (Lond). 2020 Jul;34(7):1163-1164.</p>	<p>In view of the current pandemic, consideration may be given to bridging therapy with local or regional corticosteroids, thus delaying starting systemic immunosuppression. Patients due to start systemic therapy should be considered for screening for SARS-CoV-2 in addition to the usual panel of infection diseases, If a patient tests positive for SARS-CoV-2 and is already on systemic immunosuppression, it is recommended to taper off their systemic therapy where possible, until they have recovered from COVID-19. A multidisciplinary approach including rheumatologists, ophthalmologists, and internists may be necessary.</p>
2020	<p>Stanescu-Segall D Sales de Gauzy T Reynolds R <i>et al.</i></p>	<p>Expert Opinion on the Management and Follow-up of Uveitis Patients during SARS-CoV-2 Outbreak. Expert Rev Clin Immunol. 2020 Jul 2.</p>	<p>Management should proceed as usual when access to health care possible in patients who do not belong to a group at high risk of severe SARS-CoV-2 infection, and in uncontrolled uveitis cases. In non-severe uveitis cases, the use of systemic steroids should be avoided, and local steroids preferred. In uncontrolled situations where there is real risk of permanent visual loss, high-dose intravenous steroids and/or systemic immunosuppressants and/or biotherapies can be administered.</p>
2020	<p>Sadhu S Agrawal R Pyare R <i>et al.</i></p>	<p>COVID-19: Limiting the Risks for Eye Care Professionals. Ocul Immunol Inflamm. 2020 Apr 20:1-7.</p>	<p>The authors discuss current evidence around detection of SARS-CoV-2 in human tears and forms of transmissions reported to date. They also provide a comprehensive approach that may be implemented in an ophthalmic care facility to protect healthcare personnel, as well as patients, from contracting the virus.</p>

2020	<p>Ho D Low R Tong L Gupta V Veeraraghavan A Agrawal R</p>	<p>COVID-19 and the Ocular Surface: A Review of Transmission and Manifestations. Ocul Immunol Inflamm. 2020 Jun 16:1-9.</p>	<p>The exact pathophysiology of ocular transmission of the virus remains incompletely understood, although there is preliminary evidence of SARS-CoV-2 being detected in ocular secretions. The ocular tropism of the virus and its potential to cause localized ocular disease are worth considering.</p>
2020	<p>Gupta V Rajendran A Narayanan R <i>et al.</i></p>	<p>Evolving consensus on managing vitreo-retina and uvea practice in post-COVID-19 pandemic era. Indian J Ophthalmol. 2020 Jun; 68(6):962-973.</p>	<p>The present preferred practice patterns have been formulated by a leading group of experts constituted from the representatives of Vitreoretinal Society of India (VRSI), Uveitis Society of India (USI), iROP and from major institutes and the IJO leadership. Guidelines for a new patient of uveitis were described and caution with initiation of immunosuppressants was highlighted.</p>
2020	<p>Thng ZX De Smet MD Lee CS <i>et al.</i></p>	<p>COVID-19 and immunosuppression: a review of current clinical experiences and implications for ophthalmology patients taking immunosuppressive drugs. Br J Ophthalmol. 2020 Jun 12;bjophthalmol-2020-316586.</p>	<p>Preliminary clinical experiences based on case reports, small series and observational studies show the morbidity and mortality rates in immunosuppressed patients may not differ largely from the general population. Overwhelmingly, current best practice guidelines worldwide recommended the continuation of immunosuppression treatment in patients who require them except for perhaps high-dose corticosteroid therapy and in patients with associated risk factors for severe COVID-19 disease.</p>

2020	<p>Arora R Goel R Kumar S <i>et al.</i></p>	<p>Evaluation of SARS-CoV-2 in Tears of Patients with Moderate to Severe COVID-19. Ophthalmology 2020;_:1-10 (article in press)</p>	<p>Tears were collected within 48 hours of laboratory confirmation using 3 methods: conjunctival swab plus Schirmer's test strips (group 1), conjunctival swab (group 2), and Schirmer's test strips (group 3) and subjected to RT-PCR. SARS-CoV-2 RNA was detected in tears of 24% of patients with moderate to severe COVID-19. Conjunctival swab was considered the gold standard of tear collection for RT-PCR assay.</p>
------	--	--	---





Paracentral Acute Middle Maculopathy Associated with Viral Retinitis and Amaurosis Fugax



Dr. Eliza Anthony

Aravind Eye Hospital, Chennai

Email: aelizacorin@yahoo.com

Paracentral Acute Middle Maculopathy Associated with Viral Retinitis and Amaurosis Fugax

ABSTRACT

A 44 year old male patient presented with diminished vision in left eye for two weeks. Best corrected visual acuity(BCVA) in LE was 6/9 and fellow eye was 6/6. Ophthalmoscopic examination of right eye was normal and left eye revealed PAMM lesion and patchy retinitis in temporal peripherally. OCT showed hyper-reflective lesions in the inner nuclear layer (INL) in the parafoveal region. Flourescein angiography showed late hyperfluorescence corresponding to areas of retinitis and mild hypoflourecence in the macular region. Blood tests and radiological workup was normal. He was started on oral valacyclovir 1000 mg thrice daily initially. Oral steroids, 0.5 mg/kg body weight, were started after three days. Symptomatic improvement was observed at one week follow up. His visual acuity improved to 6/6 although there was no change in the PAMM lesion.

Case report

A 44 year old male patient presented with diminished vision in left eye(LE) for two weeks. He gave history of amaurosis fugax in LE during early hours of the day which disappeared within five hours associated with headache, 3 weeks before the onset of his ocular symptoms. He had no underlying systemic disease. He was a chronic smoker. BCVA in right eye(RE) was 6/6 and LE was 6/9. Intraocular pressure was 18 mmHg in both eyes. Relative afferent pupillary defect was not present. Right eye fundus was normal and left eye revealed a wedge shaped patch of retinal whitening temporal to the fovea with deep retinitis in circumferential pattern in the temporal peripheral retina. But there was no evidence of anterior segment inflammation or vitritis.(Figure 1)

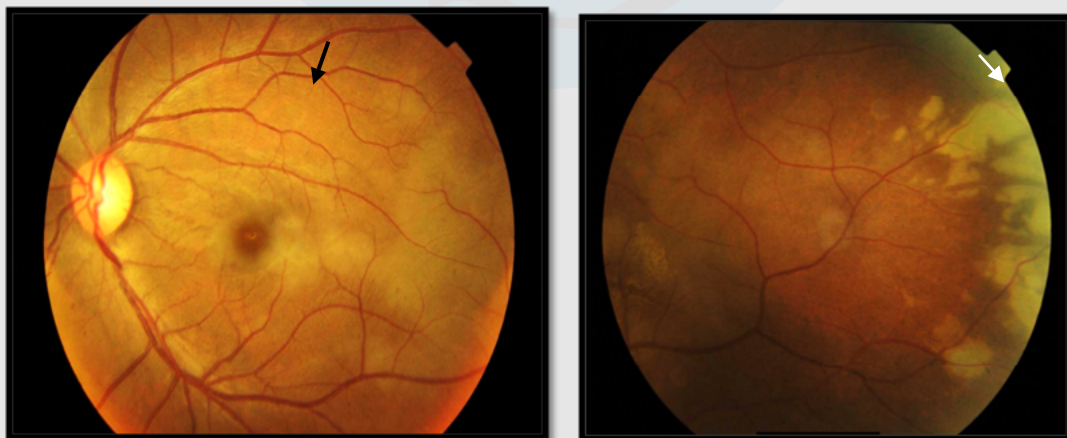


Figure 1

Figure 1- Left eye revealed a wedge shaped patch of retinal whitening temporal to the fovea (black arrow) with deep retinitis(white arrow) in circumferential pattern in the temporal peripheral retina.

Spectral domain optical coherence tomography (SDOCT) showed hyper-reflective lesions in the INL in the parafoveal region. (Figure 2)

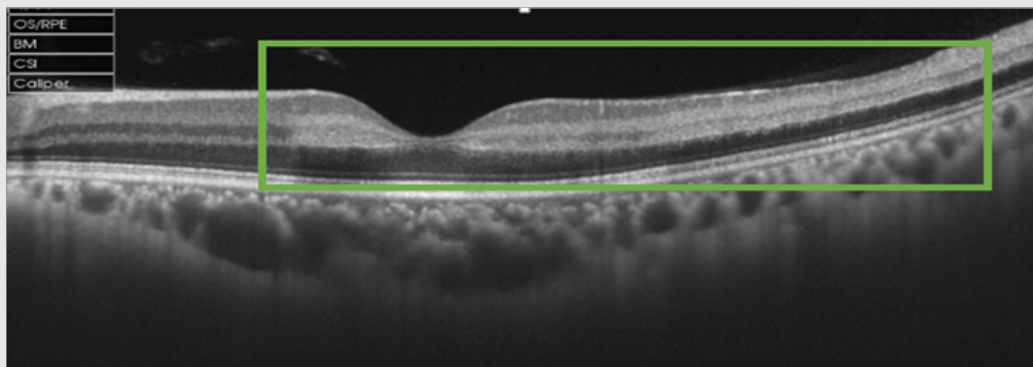


Figure 2

Figure 2- SDOCT showed hyper-reflective lesions in the INL in the parafoveal region

FFA showed mild hypofluorescence corresponding to the wedged shaped area at the macula. Retinitis patches were hyperfluorescent(Figure 3)

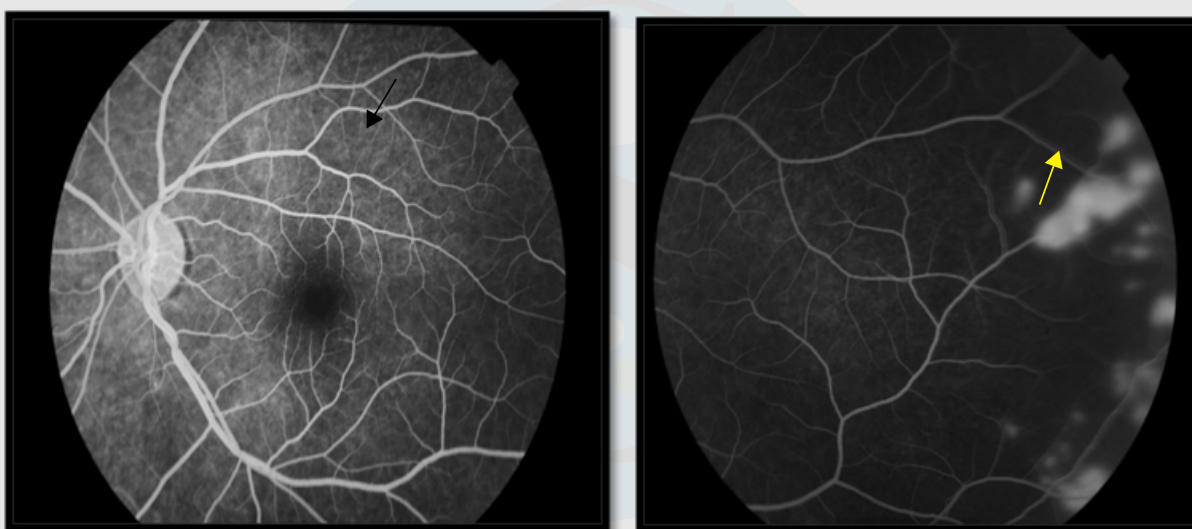


Figure 3

Figure 3- Mild hypofluorescence corresponding to the wedged shaped area (black arrow) at the macula and retinitis patches were hyperfluorescent(yellow arrow).

Optical coherence tomography angiography(OCTA) showed flow void areas in middle and deep capillary plexus. (Figure 4)

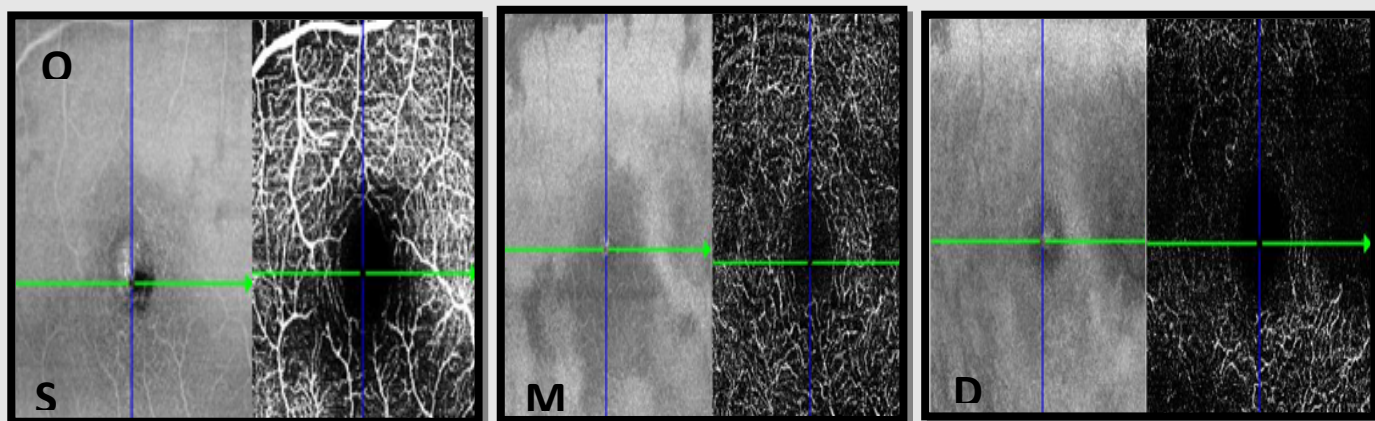


Figure 4

Figure 4 - Optical coherence tomography angiography(OCTA) showed flow void areas in superficial(S), middle(M) and deep capillary plexus(D).

We made a diagnosis of viral retinitis associated with paracentral acute middle maculopathy (PAMM). ANA, cANCA, pANCA,ESR,CRP, lipid profile, complete blood count, coagulation profile, peripheral smear and radiological workup was normal. Mantoux and TPHA were negative. A cardiovascular work up was done and other possible systemic causes of amaurosis fugax and PAMM were all ruled out. The patient was started on oral valacyclovir 1000 mg thrice daily initially and oral steroids, 0.5 mg/kg body weight, were initiated after three days. He reported symptomatic improvement at one week follow up with complete resolution of retinitis lesions. (Figure 5)

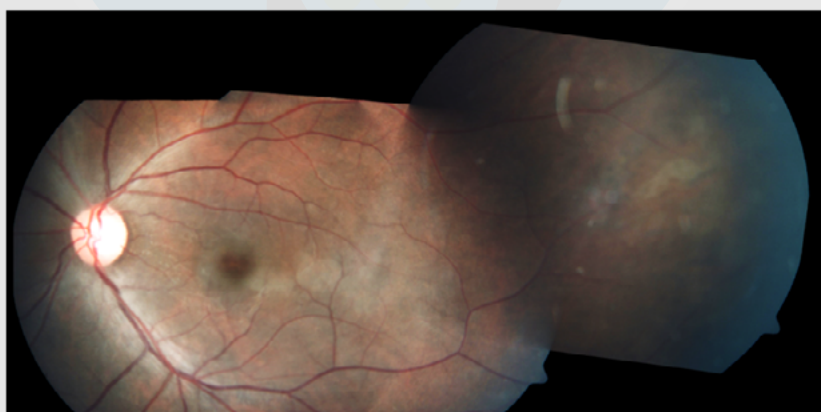


Figure 5

Figure 5 - At one week follow up complete resolution of retinitis lesions

Left eye BCVA improved to 6/6 although there was no change in the PAMM lesion (Figure 6). Patient's next review is awaited.

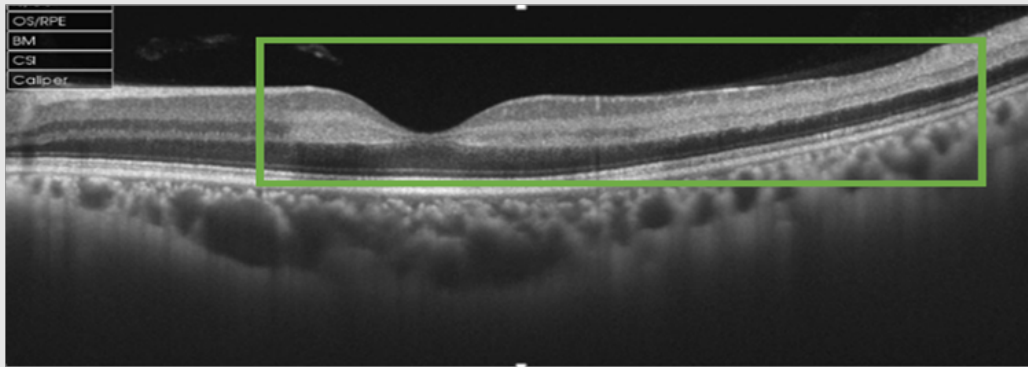


Figure 6

Figure 6- at one week follow up there was no change in the PAMM lesion-persistent hyperreflective band at INL.

Discussion

PAMM was first described by Saraf and associates as type 1 variant of acute macular neuroretinopathy (AMN), characterized by hyperreflective band like lesion located at the level of INL parafoveally on SDOCT unlike type 2 AMN where lesions are present at level of outer plexiform layer (OPL) and outer nuclear layer (ONL). Proposed pathogenesis is ischemic insult at the level of inner plexiform layer (IPL) and INL junction, that is superficial capillary plexus. (1) Later vascular complexes were redefined into three capillary plexuses in retina, superficial capillary plexuses (SCP) located at nerve fiber layer, ganglion cell layer and inner portion of inner plexiform layer, intermediate/middle capillary plexuses (ICP/MCP) located at outer portion of inner plexiform layer and inner portion of inner nuclear layer and deep capillary plexuses (DCP) located at outer portion of inner nuclear layer and outer plexiform layer. Recent study shows that it is the deep vascular plexus composed of ICP and DCP which gets affected in PAMM. PAMM can also extend vertically to involve superficial SCP in few cases. (2), (3), (4) In our case too, patient had wedge shaped area of retinal whitening extending from fovea temporally with corresponding band of hyperreflectivity at INL level subfoveally extending temporally, suggestive of a PAMM lesion. Fluorescein angiography at PAMM lesions was hyperfluorescent but the areas of peripheral retinitis were hyperfluorescent. This shows that the posterior pole lesions and peripheral lesions were different pathologies. OCTA also showed flow void areas in SCP, MCP and DCP at PAMM lesions. History of acute onset of blurring with amaurosis fugax which resolved over five hours also suggest an ischemic insult to eye. But the most interesting feature was presence of active peripheral retinitis temporally in a circumferential manner. Clinical picture and good response to oral antiviral further confirms the viral etiology of the retinitis patches. However, in absence of vitritis vitreous tap was not considered as an option. Absence of vitritis could be explained as result of deeper lesions and early presentation. Varicella zoster associated occlusive vasculopathy has been already reported previously. (5), (6) Serotonin has

been recently described as proinflammatory mediator in virus associated diseases. In experimental studies in monkeys, Hayreh has already described role of serotonin, released due to platelet aggregation at atherosclerotic plaques, in causing severe vasospasm of central retinal artery, and a possible mechanism for amaurosis fugax. (7),(8) We also hypothesize the possibility that it could be the viral retinitis which caused vasculopathic effect and lead to PAMM. Amaurosis fugax as well as PAMM both can be attributed to serotonin release secondary to viral retinitis however further studies are needed to prove this pathogenesis. This is a first case which reported PAMM associated with presumed viral retinitis and amaurosis fugax.

Conclusion: In the presence of amaurosis fugax, it is very important to rule out other systemic factors and to keep close watch over the patient. Early diagnosis, high degree of suspicion and early treatment can give good visual prognosis to the patient.

References

1. Sarraf D, Rahimy E, Fawzi AA, Sohn E, Barbazetto I, Zacks DN, Mitra RA, Klancnik JM, Mrejen S, Goldberg NR, Beardsley R. Paracentral acute middle maculopathy: a new variant of acute macular neuroretinopathy associated with retinal capillary ischemia. *JAMA ophthalmology*. 2013 Oct 1;131(10):1275-87.
2. Chen X, Rahimy E, Sergott RC, Nunes RP, Souza EC, Choudhry N, Cutler NE, Houston SK, Munk MR, Fawzi AA, Mehta S. Spectrum of retinal vascular diseases associated with paracentral acute middle maculopathy. *American journal of ophthalmology*. 2015 Jul 1;160(1):26-34.
3. Campbell JP, Zhang M, Hwang TS, Bailey ST, Wilson DJ, Jia Y, Huang D. Detailed vascular anatomy of the human retina by projection-resolved optical coherence tomography angiography. *Scientific reports*. 2017 Feb 10;7:42201.
4. Chu S, Nesper PL, Soetikno BT, Bakri SJ, Fawzi AA. Projection-resolved OCT angiography of microvascular changes in paracentral acute middle maculopathy and acute macular neuroretinopathy. *Investigative ophthalmology & visual science*. 2018 Jun 1;59(7):2913-22.
5. Narayanan S, Gopalakrishnan M, Giridhar A, Anthony E. Varicella Zoster-related Occlusive Retinal Vasculopathy—A Rare Presentation. *Ocular Immunology and Inflammation*. 2016 Mar 3;24(2):227-30.
6. Attia S, Khochtali S, Mbarek S, Amor SB, Zaouali S, Messaoud R, Khairallah M. Acute retinal necrosis associated with central retinal artery occlusion followed after its resolution by keratouveitis. *Ocular Immunology and Inflammation*. 2013 Oct 1;21(5):405-7.
7. Foster T, Battaglia D, Sanchez-Pino MD, Nichols C. Virus-induced serotonin production correlates with severity of inflammation-associated ocular disease: Therapeutic potential of 5HT_{2A} receptor agonists. *Investigative Ophthalmology & Visual Science*. 2020 Jun 10;61(7):429-.
8. Hayreh SS, Zimmerman MB. Amaurosis fugax in ocular vascular occlusive disorders: prevalence and pathogenesis. *Retina*. 2014 Jan 1;34(1):115-22.





Clinical pearls in ARN diagnosis and management



Dr. Shishir Narain

Shroff Eye Centre, New Delhi

Email: shishirnarain@gmail.com



Dr. Manisha Agarwal

Shroff Charity Eye Hospital, New Delhi

Email: agarwalmannii@yhoo.co.in

Clinical pearls in ARN diagnosis and management

Introduction

Acute Retinal Necrosis (ARN) by definition is a unilateral necrotizing retinitis which may become bilateral ARN (BARN) in up to 10 -15% patients. It is a vision threatening disease entity if not diagnosed and treated in time. To diagnose ARN in clinical practice is difficult and an error of judgement may be very unforgiving. It's management has instilled fear, frustration and fascination, all at once in the minds of the treating ophthalmologist. Hence we need to be fully aware of it's varied clinical manifestations and hazards of delayed diagnosis.

ARN was first described as "Kirisawa uveitis" a syndrome of acute panuveitis with retinal periarteritis progressing to diffuse necrotizing retinitis and retinal detachment (RD).¹ The treating ophthalmologist was often puzzled seeing a relentless progression of an initially innocuous looking lesion in the peripheral retina which then rapidly progressed to retinal necrosis, RD and eventual blindness as a rapid succession of events. In recent times ARN syndrome is said to represent a specific pattern of clinical presentation for certain herpes virus infections in the posterior segment of the eye.

Although viral diseases occur more frequently in immunocompromised individuals, ARN is an affliction in both the immunocompromised as well as immunocompetent persons. It is an immune response to the viral infection that sets in the necrotic reaction within the retinal tissue, commencing in the periphery and spreading in a circumferential and confluent fashion akin to forest fire. Since the initial clinical picture may appear like retinal vasculitis it is not uncommon for a initial mistaken diagnosis of retinal vasculitis or vitritis. An error of giving periocular steroids at this stage will make the condition worse. Hence a high index of suspicion is absolutely necessary to avert this disaster. Zhang *et al.* have reported the development of ARN following intravitreal dexamethasone implant for macular edema, alarming caution and judicious use of intravitreal and periocular steroids unless sure of a non-infectious cause.²

Laboratory investigations

The mainstay of diagnosis is primarily clinical and the laboratory tests are ancillary to help determine the viral etiology. Polymerase chain reaction (PCR) of anterior chamber tap (AC tap) helps to identify the etiology in a fairly large proportion of cases. Sugita *et al.*, in a retrospective analysis of 100 patients with uveitis and 16 cases of ARN were tested for ocular fluids had either HSV1 (2), HSV2 (3), or VZV (11) genome detected. In all patients, high copy numbers of the viral DNA were also noted, indicating the presence of viral replication.³ Schoenberger *et al.* in a recent report showed that the PCR testing of aqueous and vitreous specimens were both sensitive and specific & positive for HSV or VZV in 79% to 100% of cases of suspected ARN.⁴

Clinical diagnosis

It is imperative to thoroughly examine any patient of anterior uveitis for posterior segment involvement and exclude any hidden pathology. The use of protective gloves to thoroughly examine herpes zoster ophthalmicus (HZO) cannot be overemphasized, which has anyways become universal way of examining patients since the COVID pandemic! The anterior segment can sometimes give vital clues for early suspicion of ARN.

Anterior segment signs:

1. Mild anterior chamber reaction in the form of 0.5 to 1+ cells (SUN classification).⁵
2. Pigment dusting on the corneal endothelium or a dendritic ulcer
3. Irregular pupil with transillumination defects (indicating present or previous viral uveitis)

Posterior segment signs: the classical triad

1. Arteritis and phlebitis of the retinal and choroidal vasculature
2. Tongue shaped confluent, necrotizing retinitis patches in the peripheral retina
3. Vitritis - moderate to severe in intensity

Complications

1. Optic neuritis
2. Rhegmatogenous retinal detachment (RRD)
3. Arteriolar occlusion (BRAO or CRAO) or combined occlusion

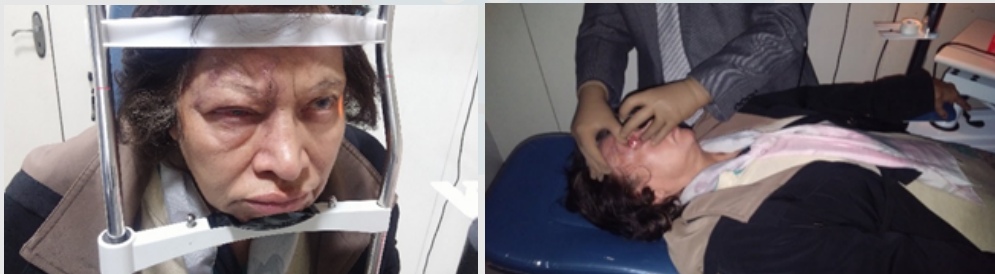


Fig - 01

Fig-1: Anterior Segment examination of a lady with Right sided HZO. Gloved hands while doing indirect ophthalmoscopy to examine peripheral retina in HZO

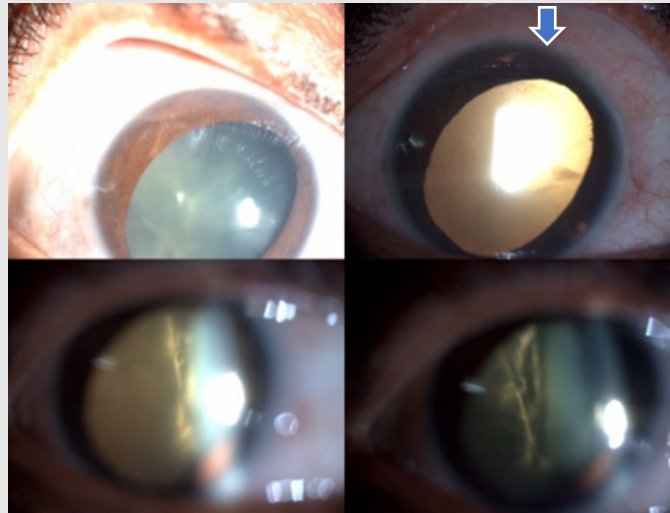


Fig - 02

Fig-2: Slit lamp photos (a) sphincter iris atrophy and irregular pupil in direct illumination. (b) Retro-illumination showing transmission defects (blue arrows). (c) anterior & posterior vitreous showing dense vitritis obscuring retinal view

Management

Antiviral therapy: The standard of care for ARN includes intravenous acyclovir in a dose of 5 to 10 mg/kg IV every 8 hours for 2 to 7 days or until clinical improvement is observed, followed by oral antiviral therapy to complete at least 10 days of total therapy. This is with a presumed diagnosis of herpetic etiology unless proven otherwise. Oral Valaciclovir (1gram thrice a day) is an efficacious alternative to intravenous acyclovir and has shown to attain equivalent plasma drug levels comparable to intravenous acyclovir. There is level II and III evidence supporting the use of intravenous and oral antiviral therapy for the treatment of ARN.⁴ A combination of intravitreal foscarnet (dose-1.2mg/0.05ml) and systemic antiviral therapy is said to have greater therapeutic efficacy alone.⁴

Laser photocoagulation and Vitrectomy: The effectiveness of prophylactic laser or early pars plana vitrectomy (PPV) to clear the media haze and facilitate laser photocoagulation is considered to decrease retinal detachment (RD), however its role still remains controversial.⁴ Management of RRD is done by pars plana vitrectomy with instillation of higher centistokes silicone oil. It is a complex PPV as the vitreous is inflamed and induction of posterior vitreous detachment (PVD) has to be accomplished cautiously in the thin and atrophic retina with multiple holes secondary to retinitis and tends to develop iatrogenic breaks or tear on slightest pull. Often these patients need to have the silicone oil in situ indefinitely for several years or even permanently due to a high risk of recurrence of RRD.

Case-1

A 42 years young healthy immunocompetent male presented to the anterior segment clinic with red eye for last 5 days. BCVA in both the eyes was 6/6, N6 and 16mm Hg IOP in both eyes. Slit lamp examination of the right eye showed herpetic dendrite (Fig-3). Routine fundus examination revealed one large patch of ARN in the superonasal quadrant and multiple patches in the peripheral retina. A loading dose of intravenous acyclovir was followed by 360 degree laser photocoagulation and also surrounding each retinitis patch.(Fig-4) Later the areas of resolved retinitis appeared as empty islands surrounded by laser. Six months later patient developed a thick ERM with macular distortion and cystoid macular edema on optical coherence tomography (OCT),which was removed surgically. The retina has been stable over the next 5 years without any reactivation.(Fig-5) This case highlights that early detection with aggressive initial treatment is the key to success in ARN

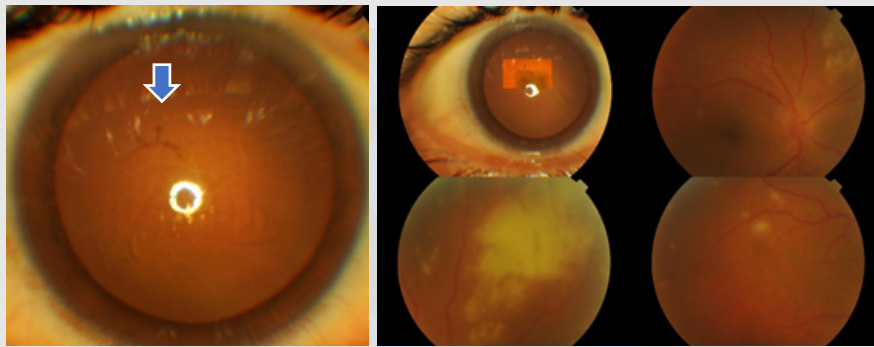


Fig - 03

Fig-3: (a) Slit lamp photo showing a corneal dendrite (white arrow), (b and c) Fundus photo showing yellowish white creamy tongue shaped retinitis patch in the peripheral retina with multiple small patches of early retinitis

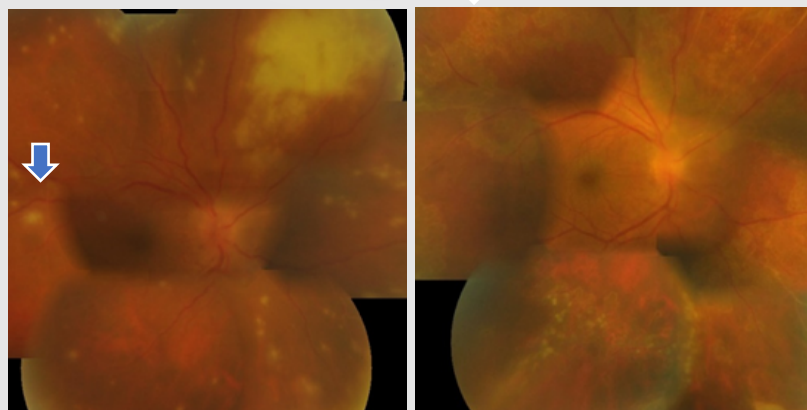


Fig - 04

Fig-4: (a) Color fundus montage of the right eye showing active retinitis with multiple satellite lesions (blue arrow) (b) post-laser showing laser surrounding resolved retinitis patches individually along with 360 degree laser barrage (white arrow)

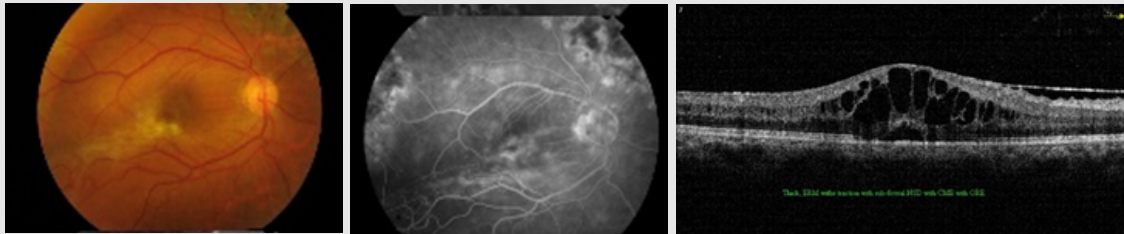


Fig - 05

Fig-5: Posterior pole shows thick ERM with leakage and distorted vessels on Fluorescein Angiogram. OCT showing ERM with CME and NSD

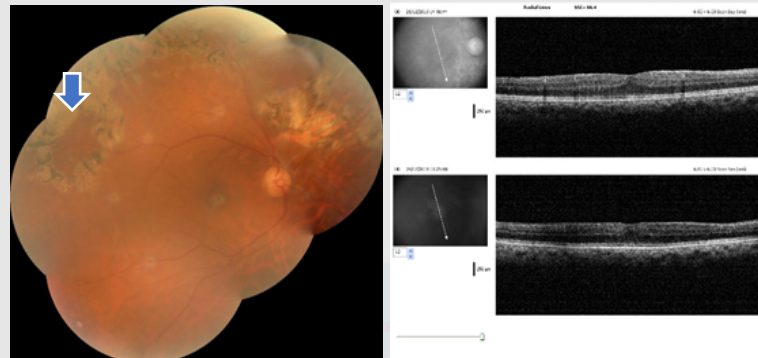


Fig - 06 a

Fig-6: (a) Color montage of the right eye at 5 years follow up showing well attached retina with resolved patches of retinitis surrounded by laser barrage chorio-retinal atrophy. (b) OCT of the right eye showing normal foveal contour post ERM removal surgery.

Case-2

A healthy immunocompetent South American Argentinian student presented with sudden visual disturbance. Large areas of ARN were prophylactically barraged. However there was tearing of the retina following the development of acute PVD secondary to inflammation.

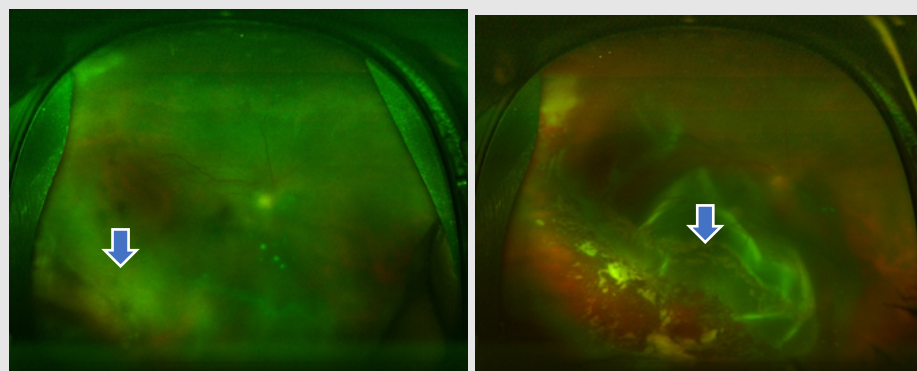


Fig - 06

Fig-6: Ultra Wide-Field photo showing (a) Laser barrage in active ARNtearing of the retina secondary to induction of PVD. Note multiple rows of barrage laser marks in the lifted detached retina

Case-3

A 68-year-old male patient presented with sudden diminution of vision in the right eye for 10 days and now developed blurred vision in the left eye. He had left facial paralysis 6 years back, hypertensive for last 6 years and bypass surgery for coronary artery disease and had stopped antiplatelet treatment 6 months back. He had been diagnosed as branch arteriolar occlusion in the right eye and the treating cardiologist restarted antiplatelet treatment. The best corrected visual acuity in the right eye was finger counting at 3 meters and in the left eye 6/36,N36. Slit lamp examination showed granulomatous KPs in the left eye. Fundus examination of the right eye showed hyperemic disc with blurred margins and retinal edema secondary to BRAO.(Fig-7) and the left eye showed media haze with disc swelling and tongue shaped lesions in the periphery.(Fig-8) Patient was treated with Oral Valcyclovir 1gm three times a day along with with Intravitreal injection of ganciclovir (2 mg/0.05 mL) + Dexamethasone (400µg) twice weekly and a total of 6 injections were given. Oral corticosteroids (1mg/kg) were added and prophylactic laser photocoagulation was done after vitritis decreased. At 3 weeks follow up he recovered a vision of 3/60 in the left eye due to optic disc pallor and sclerosed vessels. This case highlights that vascular occlusion can be the presenting sign of ARN. ^{5,6} Therefore a thorough examination of the retinal periphery of both eyes is mandatory as was missed an early disease in the fellow leading to delayed treatment & final poor visual outcome in the left eye

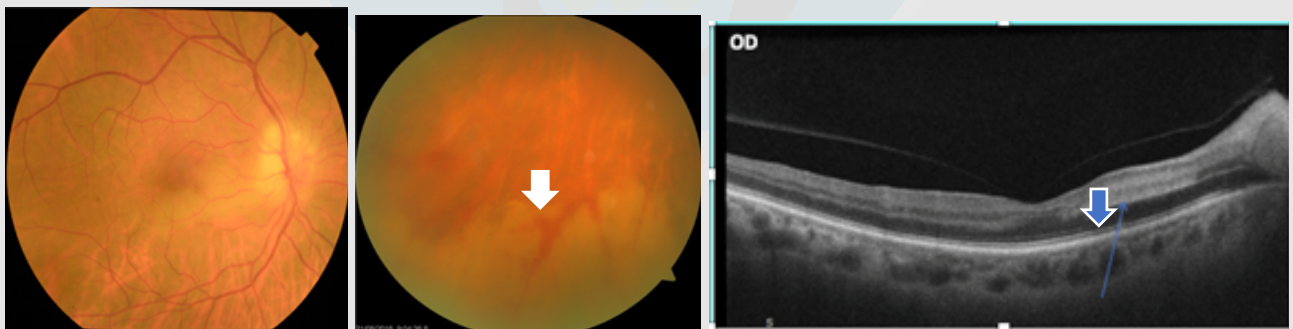


Fig - 07

Fig-7: (a) Color fundus photo of the right eye showing disc edema and retinal edema (white arrow) corresponding to BRAO. (b) OCT of the right eye showing hyper-reflective band corresponding to BRAO (blue arrow)

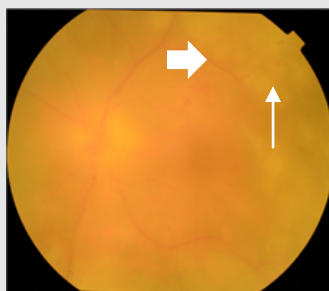


Fig - 08

Fig-8: Color fundus photo of the fellow left eye showing tongue shaped lesions of ARN in the periphery reaching till the arcade.

Differential Diagnosis

Since ARN is essentially a morphological diagnosis there are other necrotizing retinal inflammations that may mimic the ‘typical’ herpetic ARN.⁷ The most common masquerader is the toxoplasmic retinochoroiditis that is often referred to as atypical Toxoplasmic retinochoroiditis (Fig 9). Successful anti-toxoplasma treatment is the key to managing these cases.

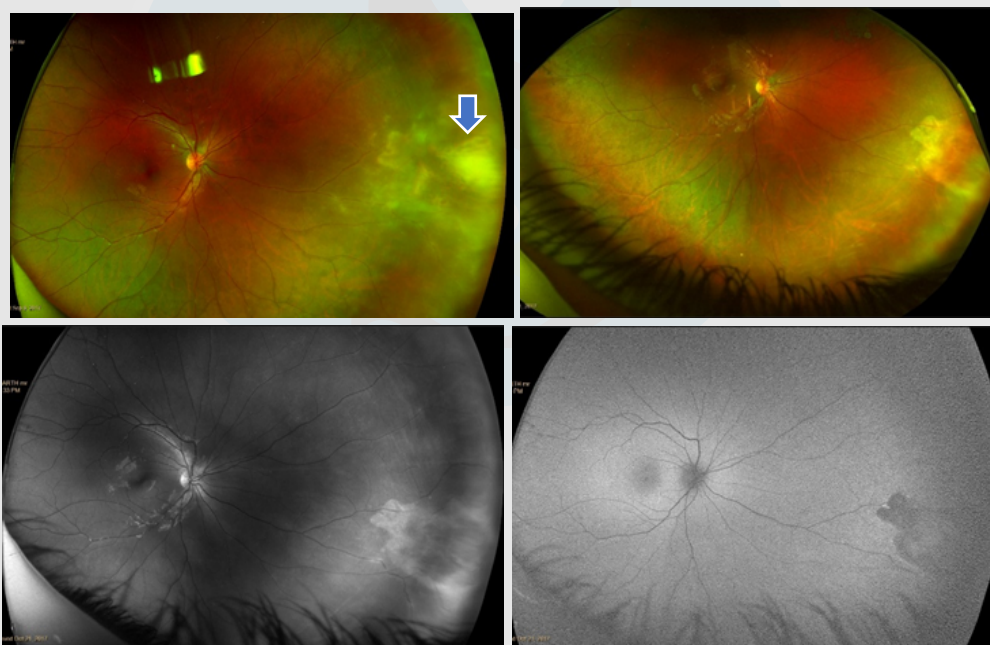


Fig - 09

Fig-9: A far peripheral yellowish necrotizing retinitis patch in the right eye nasal quadrant of a 17 years old immunocompetent male. Complete healing of the lesion seen on color, red-free and autofluorescence after anti-toxoplasma treatment.

REFERENCES

1. Urayama A, Yamada N, Sasaki T, *et al.* Unilateral acute uveitis with retinal periarteritis and detachment. *Jpn J Clin Ophthalmol.* 1971; 25: 607-619.
2. Zhang ZY, Liu XY, Jiang T. Acute retinal necrosis following dexamethasone intravitreal implant administration in an immunocompetent adult with a history of HSV encephalitis: a case report. *BMC Ophthalmol.* 2020;20(1):247.
3. Sugita S, Shimizu N, Watanabe K, *et al.* Use of multiplex PCR and real-time PCR to detect human herpes virus genome in ocular fluids of patients with uveitis. *Br J Ophthalmol.* 2008;92(7):928-932.
4. Schoenberger SD, Kim SJ, Thorne JE, *et al.* Diagnosis and Treatment of Acute Retinal Necrosis: A Report by the American Academy of Ophthalmology. *Ophthalmology.* 2017;124(3):382-392.
5. Yeh S, Fahle G, Flaxel CJ, Francis PJ. Central Retinal Vascular Occlusion Associated With Acute Retinal Necrosis. *Arch Ophthalmol.* 2012;130(4):514–517.
6. Kang SW, Kim SK. Optic neuropathy and central retinal vascular obstruction as initial manifestations of acute retinal necrosis. *Jpn J Ophthalmol.* 2001 Jul-Aug;45(4):425-8.
7. Balansard B, Bodaghi B, Cassoux N, Fardeau C, Romand S, Rozenberg F, Rao NA, Lehoang P. Necrotising retinopathies simulating acute retinal necrosis syndrome. *Br J Ophthalmol.* 2005 Jan;89(1):96-101.





Does response to treatment clinch the diagnosis in viral uveitis?



Dr. Mudit Tyagi

Email: drmudittyagi@gmail.com



Dr. Hrishikesh Kaza

Email: hrishikesh.kaza@gmail.com



Dr. Soumyava Basu

Email: eyetaik@gmail.com

Uveitis and Ocular Immunology Services
L V Prasad Eye Institute, Hyderabad

Does response to treatment clinch the diagnosis in viral uveitis?

Viral infections of the eye can have myriad presentations. They may manifest as both anterior or posterior segment inflammation. ⁽¹⁾

The common viral etiologies for uveitis are CMV, VZV, HSV-1, HSV-2, Chikungunya (Epidemic/Post-fever retinitis) and Epstein Barr virus (EBV). ^(1,2)

Viral uveitis entities remain a clinical diagnosis with their presentation. Characteristic features on the slit lamp and dilated fundus examination are used to diagnose viral uveitis.

In many cases, the anterior uveitis is associated with characteristic diffuse pigmented or stellate, granulomatous or non-granulomatous keratic precipitates, iris atrophy, with or without posterior synechiae, reduced corneal sensitivity, raised intraocular pressure (IOP) and presence of active or healed keratitis (keratouveitis), corneal foot print scars or scleritis (Sclerokeratouveitis). CMV anterior uveitis can have coin shaped keratic precipitates or may develop nodular endothelial lesions/endothelitis with raised IOP or a Posner-Schlossman syndrome. ⁽³⁾

On the other spectrum viral posterior uveitis manifests mostly as retinitis. The spectrum of viral retinitis presentations ranges from acute retinal necrosis (ARN) in immunocompetent patients to CMV retinitis and progressive outer retinal necrosis (PORN) in immunocompromised patients. ^(4,5)

Viral posterior uveitis may present with symptoms of decreased visual acuity, visual field defects, floaters, photopsia, photophobia, and occasionally pain. Patient of Acute retinal necrosis can also present with pain due to involvement of long anterior ciliary nerve. Retinal examination may reveal a diverse set of manifestations including inflammatory infiltrates on the retina, confluent or patchy retinitis, retinal vascular sheathing and macular edema in acute cases or scarring, retinal pigment epithelium (RPE) hyperplasia, retinal detachment, optic neuritis and optic atrophy with subnormal vision as a long term sequelae. ^(4,5)

Retinal imaging including fundus photography, optical coherence tomography (OCT), fundus fluorescein angiography (FFA) and wide field retinal imaging have added more insights to understanding the disease, identifying it and can even help in monitoring response of retinitis lesions to treatment ⁽⁶⁾

However in atypical presentations, viral serology for polymerase chain reaction (PCR) of intraocular fluids can be used to confirm the diagnosis. Aqueous or vitreous sample sent for quantitative PCR or Goldmann-Witmer coefficient assay can give us a clue of true diagnosis in atypical presentations or in those with inadequate response to treatment.

Chorioretinal biopsy is another diagnostic tool that may be useful in confirming the diagnosis in selected cases where both the PCR and Goldmann-Witmer coefficient analyses are negative, and there is still a high index of suspicion. [7]

In few atypical uveitis PCR can be positive for multiple viruses. Tyagi M *et al.* [8] had reported a case of CMV Retinitis in a patient of Non Hodgkins Lymphoma wherein the patient had dense vitritis and a non-haemorrhagic retinitis mimicking intraocular lymphoma. However the vitreous sample was positive for cytomegalovirus (CMV) and herpes simplex virus 1 (HSV-1) DNA. Hence PCR can be useful in such atypical cases to give a clue towards the underlying diagnosis and can help in guiding treatment.

Harper *et al.* [9] had done PCR tests of 105 aqueous and 38 vitreous specimens of suspected infectious uveitis and found a sensitivity of 80.9%, specificity of 97.4%, positive predictive value of 98.7% and a negative predictive value of 67.9% of PCR for diagnosing infectious uveitis. On the other hand Chronopoulos *et al.* [10] found that overall PCR positivity to be only 48.9 %.

Thus there are times when the clinicians may be faced with a diagnostic dilemma where even the PCR or biopsy reports may be inconclusive.

In some of these occasions therefore, it is the response to treatment which may be an indicator of an underlying etiology.

In the attempt to eradicate active intraocular infection, minimise retinal necrosis and damage from the inflammatory response, antivirals may be initiated even without waiting for microbiological confirmation. Intravitreal injections of antivirals are also known to provide adjunctive support, given at the time of diagnostic tap and repeated as clinically indicated. Indications include sight-threatening lesions involving optic disc head or macula, and in conjunction with systemic treatment.

The response to treatment in such cases may not only aid in ruling in a disease but can also sometimes be of immense help in ruling out the disease.

We hereby present 3 cases where the response to treatment was used as a clue to arrive at the underlying infective etiology.

Case 1

A 36-year-old male patient presented with a chief complaint of blurred vision in the left eye since 1 month. On examination, RE vision was 20/20. The anterior & posterior segment examination was within normal limits. LE vision was 20/80, N36, not improving with correction. Fundus examination revealed a patch of retinitis superonasally along with peripheral vasculitis lesions (Figure 1a). The patient's uveitis investigations were negative for Tuberculosis, HIV and Ocular Syphilis. An initial vitreous tap was done

along with PCR. However the PCR reports were inconclusive. A clinical diagnosis of left eye viral retinitis was made and the patient received 2 intravitreal gancyclovir injections along with a course of systemic antivirals (Tablet Valacyclovir 1000 mg TID). However no improvement was noted. On re-evaluation a pigmented lesion was reassessed and a provisional diagnosis of Ocular Toxoplasmosis was made.

The patient was treated with intravitreal Clindamycin along with systemic treatment which led to resolution of the retinitis lesions. (Figure 1b)

Figure-1: a. Left eye optos widefield image showing superonasal retinitis lesion with retinal perivascular sheathing. Superonasal pigmented scars may also be noted adjacent to the retinitis lesion. b. Optos image showing resolving superonasal retinitis lesions and inferotemporal pre retinal exudates.

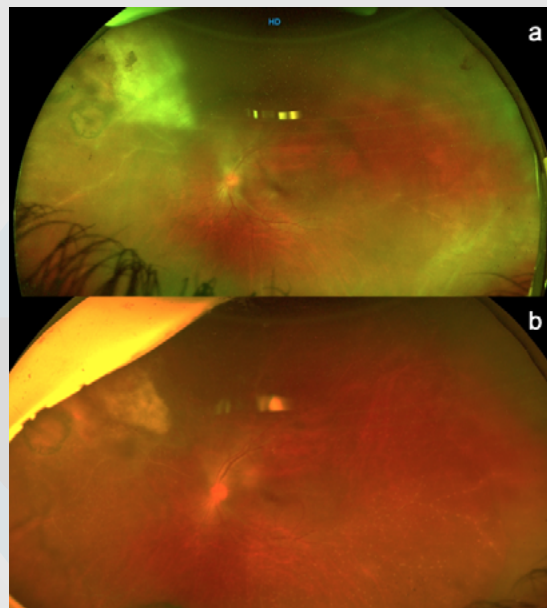


Figure: 1A, 1B

Patients who are immunocompromised or elderly may present with large, multiple and/or bilateral lesions. Other unusual manifestations of Toxoplasmosis include punctate outer retinal toxoplasmosis, retinal vasculitis, retinal vascular occlusions, rhegmatogenous and serous retinal detachments, a unilateral pigmentary retinopathy mimicking retinitis pigmentosa, neuroretinitis and other forms of optic neuropathy, and scleritis. ^[11-13]

Case 2

A 45 year lady was initially diagnosed as Panuveitis and treated elsewhere initially with systemic corticosteroids.

At the time of presentation to LVPEI she had a presenting vision of 20/100 in her RE and 20/40 in her LE. Her VDRL was negative and ELISA for HIV was positive. On examination she was noted to have inferior multiple pin point lesions and ground glass retinitis in both her eyes (Figure 2A, B). She was diagnosed as having CMV Retinitis and was treated with Intravitreal Ganciclovir.

However her vision deteriorated from 20/200 to CFCF in right eye and 20/100 in left eye. The retinitis lesions had progressed even after receiving 2 weeks of biweekly intravitreal ganciclovir.

She was subsequently seen in Uveitis clinic and was re-investigated for Ocular Syphilis. Her CD4 counts were 410 cells/ mm³. At this point of time she was noted to have a placoid chorioretinitis lesion in her RE (Figure 2C) and the optical coherence tomography revealed presence of photoreceptor damage and RPE nodularity (Figure 2D). Her TPHA was positive and she was started on IV Penicillin. The lesions regressed and her BCVA improved to 20/125 in RE and 20/30 in LE.

The clues which helped in differentiating between CMV Retinitis and Ocular Syphilis in this case were the absence of retinal hemorrhages which can be seen in CMV retinitis lesion and an elevated CD4 count. Apart from this, the presence of ground glass retinitis (Figure 2A and B), placoid chorioretinitis and the RPE nodularity also pointed towards Ocular Syphilis (14-15)

Figure 2: A. Right eye optos widefield image showing multiple ground glass retinitis lesions along the vessels with inferior multiple pin point lesions and B. a similar picture in the left eye with vitreous membranes. Healed lesions were noted along the superotemporal arcade in the left eye. C. i. Right eye fundus photo showing an outer retinal placoid lesion at the post pole with the corresponding optical coherence tomography (OCT, ii and iii) showing irregularity of ellipsoid zone with hyperreflectivity and nodularity of retinal pigment epithelium (RPE). D. Both eyes fundus photos showing resolution of retinitis after treatment with intravenous crystalline penicillin.

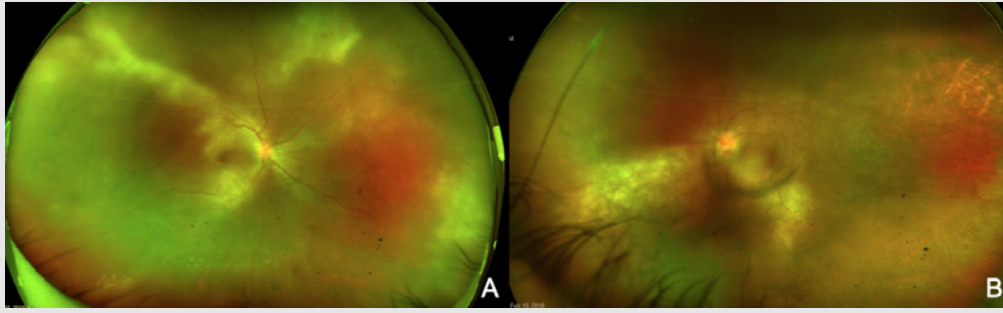


Figure: 2A, 2B

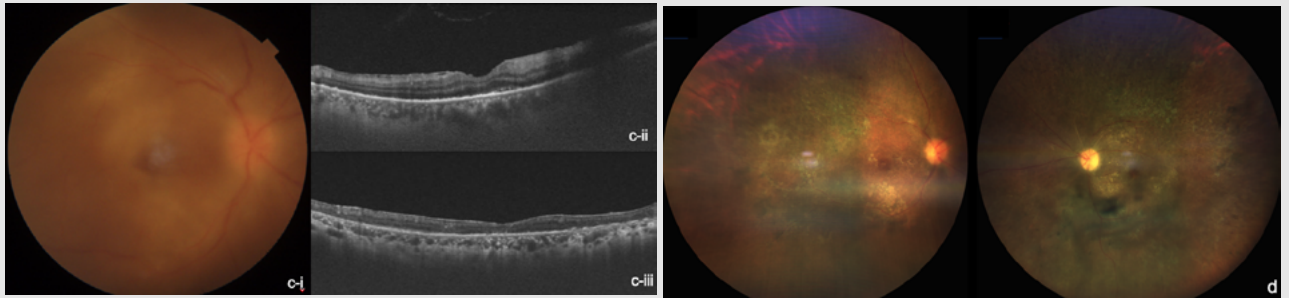


Figure: 2C, 2D

Case 3

A 49-year-old man presented with redness and pain in his right eye for the past one week. He had been diagnosed as non-granulomatous anterior uveitis (NGAU) elsewhere, and tested positive for HLA-B27. He had three similar episodes in his right eye over past one year. The patient also reported inflammatory lower back pain not requiring any treatment, on and off since past 5 years. On examination, we noted mild circumciliary congestion, clear cornea, 2-3 pigmented KPs in central cornea, 1+ AC cells, and iris sphincter atrophy in one clock hour at 7 o' clock in the right eye (Fig 3A). BCVA was 20/20, IOP 17 mm Hg and fundus unremarkable. The left eye was normal, with no signs of active or past inflammation. The iris atrophy and distribution of KPs alerted us about the possibility of viral anterior uveitis, and we noted depressed scars over the right forehead and nose, suggestive of past HZO. (Fig 3B)

Figure 3: A. Right eye slit lamp photograph under broad beam illumination showing pigmented keratic precipitates on the corneal endothelium (white arrows) and an area of sectoral iris atrophy B. Multiple healed scars of herpes zoster infection noted on the forehead and nose on the right side (white solid arrows).

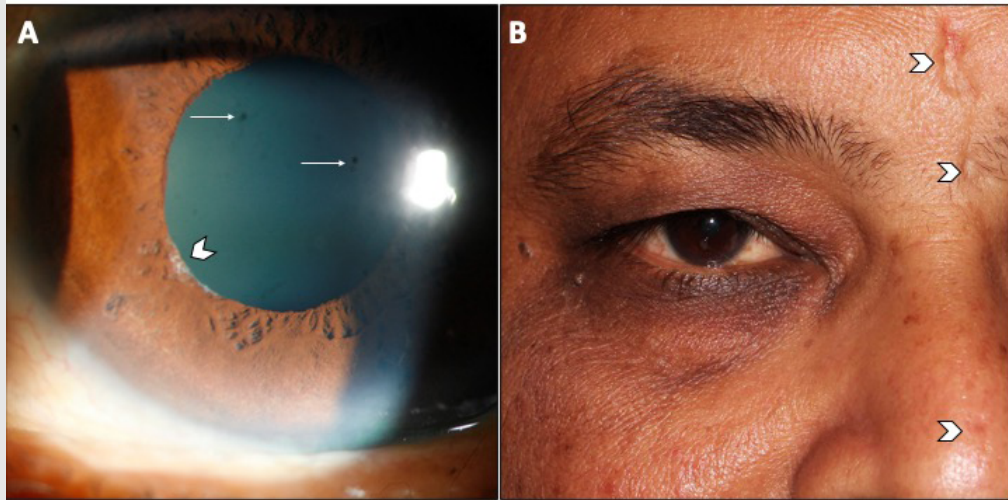


Figure: 3A, 3B

On enquiry, the patient reported right sided herpes infection one year ago. We checked for HIV infection that tested negative. Based on the clinical clues of iris atrophy, distribution of KPs and the depressed scars over the forehead, a clinical suspicion of an underlying viral etiology was considered and the patient was treated with oral acyclovir 800 mg five times a day for two weeks followed by gradual reduction in doses, and prednisolone acetate eye drops four times a day, tapered gradually over two months. No recurrence was noted over a follow up period of two months.

In both Case 1 and 2 it was the initial worsening even in spite of patient being on intravitreal ganciclovir injections that made the clinicians reassess the diagnosis.

Case 1 had a peripheral retinitis lesion which was mimicking a viral retinitis. Necrotising retinopathies can often present as diagnostic and therapeutic challenge. Viral etiologies may lead to the involvement of the entire peripheral retina within a few days or a few weeks leading to retinal necrosis. However Atypical toxoplasmosis needs to be considered in cases of necrotizing retinitis not responding appropriately to anti-viral treatment along with syphilis, lymphoma, CMV retinitis in non-HIV patients, and Behcet's disease.

Similarly Case 2 was initially diagnosed as a case of CMV Retinitis. However the presence of elevated CD4 counts, a ground glass retinitis and subsequent development of placoid chorioretinitis were indicating a cause other than CMV retinitis. The non-response to intravitreal as well as systemic antivirals was another indicator which led to a re-evaluation and to an alternate diagnosis.

The positive TPHA as well as the characteristic OCT features helped in establishing the diagnosis of Ocular syphilis. The patient was treated on lines of neurosyphilis as per the guidelines of Center for Disease Control.

Based on the clinical systemic history and ocular evaluation, case 3 was initially diagnosed an HLA-B27 associated NGAU in the right eye. But the clinical features of pigmented keratic precipitates in the acute phase, focal sphincter atrophy and sectoral atrophy of the iris were suggestive of a viral etiology. ^[16]. Multiple recurrences were also indicative of an untreated primary cause of the anterior uveitis, which resolved with oral antivirals.

Thus the response to treatment in such diagnostic dilemmas may be occasionally of immense help in managing these conundrums which can be posed by Viral uveitides.

References:

1. Wensing B, Relvas LM, Caspers LE, *et al.* Comparison of rubella virus And herpes virus-associated anterior uveitis: clinical manifestations and visual prognosis. *Ophthalmology.* 2011;118:1905-1910.
2. Pleyer U, Chee SP. Current aspects on the management of viral uveitis in immunocompetent individuals. *Clin Ophthalmol.* 2015;9:1017-1028.
3. Chee SP, Jap A. Presumed fuchs heterochromic iridocyclitis and Posner-Schlossman syndrome: comparison of cytomegalovirus-positive and negative eyes. *Am J Ophthalmol.* 2008;146:883-889.
4. Lee JH, Agarwal A, Mahendradas P, *et al.* Viral posterior uveitis. *Surv Ophthalmol.* 2017;62(4):404-445.
5. Roy R, Pal BP, Mathur G, Rao C, Das D, Biswas J. Acute retinal necrosis: clinical features management and outcomes - a 10 year consecutive case series. *Ocul Immunol Inflamm.* 2014;22(3):170-174.
6. Invernizzi A, Agarwal AK, Ravera V, Mapelli C, Riva A, Staurenghi G, McCluskey PJ, Viola F. Comparing optical coherence tomography findings in different aetiologies of infectious necrotising retinitis. *Br J Ophthalmol.* 2018 Apr;102(4):433-437
7. Rutzen, AR, Ortega-Larrocea, G, Dugel, PU, *et al.* Clinicopathologic Study of Retinal and Choroidal Biopsies in Intraocular Inflammation. *Am J Ophthalmol.* 1995;119(5):597-611
8. Tyagi M, Ambiya V, Mathai A, *et al.* Atypical cytomegalovirus retinitis in non-Hodgkin's lymphoma. *BMJ Case Reports* 2015;2015:bcr2015210812

9. Harper TW, Miller D, Schiffman JC, Davis JL. Polymerase chain reaction analysis of aqueous and vitreous specimens in the diagnosis of posterior segment infectious uveitis. *Am J Ophthalmol.* 2009;147(1):140-147.e2.
10. Chronopoulos A, Roquelaure D, Souteyrand G, Seebach JD, Schutz JS, Thumann G. Aqueous humor polymerase chain reaction in uveitis—utility and safety. *BMC Ophthalmol.* 2016;16(1):189. Published 2016 Oct 28.
11. Smith JR, Cunningham ET., Jr Atypical presentations of ocular toxoplasmosis. *Curr Opin Ophthalmol.* 2002;13:387-92.
12. Moshfeghi DM, Dodds EM, Couto CA, *et al.* Diagnostic approaches to severe, atypical toxoplasmosis mimicking acute retinal necrosis. *Ophthalmology.* 2004;111(4):716-725.
13. Burke SP, Albin TA. Toxoplasmosis retinitis masquerading as acute retinal necrosis. *Ophthalmic Surgery Lasers and Imaging Retina.* 2016; 47(10), 895-899.
14. Pichi F, Ciardella AP, Cunningham ET Jr *et al.*, Spectral domain optical coherence tomography findings in patients with acute syphilitic posterior placoid chorioretinopathy. *Retina.* 2014 Feb;34(2):373-84
15. Tyagi M, Kaza H, Pathengay A, Agrawal H, Behera S, Lodha D, Pappuru RR, Basu S, Murthy S. Clinical manifestations and outcomes of ocular syphilis in Asian Indian population: Analysis of cases presenting to a tertiary referral center. *Indian J Ophthalmol.* 2020 Sep;68(9):1881-1886.
16. Chan NS, Chee S-P. Demystifying viral anterior uveitis: A review. *Clin Exp Ophthalmol* 2019;47:320-33.





Atypical Viral Uveitis



Dr. Radhika T

Dept. of Uvea Services
Aravind Eye Hospital, Madurai

Email: radhikathundikandy@gmail.com



Dr. Rathinam S R

Chief, Uvea Services
Principal – Postgraduate Institute of
Ophthalmology Aravind Eye Hospital, Madurai

Email: rathinam@aravind.org

Atypical Viral Uveitis

Abstract

Typical viral anterior uveitis is classically unilateral and is characterised by diffuse keratic precipitates, ocular hypertension and iris atrophic patches. Atypical features when present pose a diagnostic dilemma but should be recognized. Clinical characteristics like bilateral presentation or recurrent unilateral anterior uveitis with only one or two of the typical manifestations described, endothelitis with diffuse or localized corneal edema, coin shaped endothelial lesions, diffuse pigment dispersion on endothelium with anterior chamber inflammation are atypical features and should raise suspicions of a possible viral etiology. Likewise atypical posterior segment features mentioned in literature and deserve to be highlighted include necrotising or non necrotising retinitis with slow progression and mild vitritis, multifocal retinitis involving the posterior pole, necrotising retinitis accompanied by significant retinal and vitreous hemorrhage, peripheral arteriolar sheathing with active retinitis. Molecular diagnostics like Polymerase chain reaction of ocular fluids for viruses and Goldman Witmer Coefficient are useful to clinch the etiology in doubtful cases and thereby impact treatment.

Introduction:

Human beings are a natural reservoir for a number of viruses. Viruses of the herpetic family, Rubella virus, Epstein Barr virus and newer viruses like Chikungunya, Dengue and West Nile viruses cause anterior and posterior uveitis. The viruses of the Herpesviridae family which include Herpes simplex virus 1 and 2 [HSV], Varicella zoster virus [VZV] and Cytomegalovirus [CMV] are the commonest viruses causing uveitis.¹ These viruses remain dormant in the neurosensory ganglion and reactivate from time to time causing recurrent disease.² The clinical features of viral uveitis are very characteristic and can easily be recognised.

Viral anterior uveitis is suspected when it is associated with elevated intraocular pressure, granulomatous pigmented keratic precipitates [KP], corneal scars with diminished corneal sensations in the absence of trauma, iris atrophy and unilateral presentation.³ (fig 1).

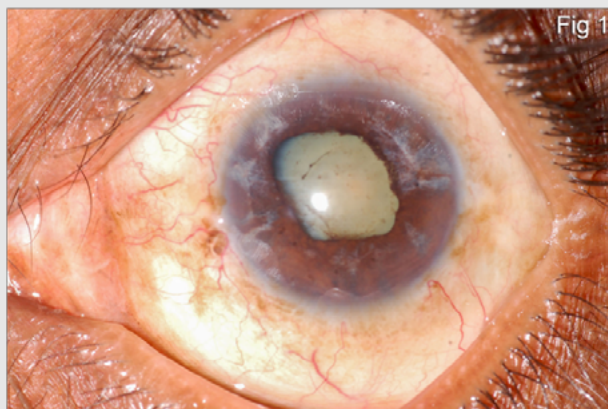


Figure 1

Figure-1: Left eye diffuse anterior segment photograph showing typical iris atrophic patches, posterior synechiae with complicated cataract following viral anterior uveitis zoster.

The course is typically acute with frequent recurrences. Rarely it can become chronic. The distribution of the KPs may be central at the back of the cornea or within the Arlts triangle. Fuchs uveitic syndrome or Fuchs like uveitis is now known to be of viral etiology. Rubella virus in the West⁴ while HSV and CMV in Singapore Taiwan, Japan are proved to cause Fuchs like uveitis.⁵ The classical presentation is unilateral uveitis with diffuse white, stellate KPs, diffuse iris atrophy giving a moth eaten appearance and complicated cataract. Fuchs uveitis can be bilateral in 10% of cases.⁶ CMV is implicated in the cause of Posner Schlossman syndrome which typically manifests unilaterally with few granulomatous or non granulomatous KPs, corneal edema, markedly elevated IOP, minimal anterior chamber reaction and absence of posterior synechiae.⁷ CMV is also proved to cause recurrent anterior uveitis. Here the KPs are granulomatous and the cornea may demonstrate coin lesions with KPs arranged in a circle within them. Vitritis is rare. Rubella virus uveitis starts in the 2nd to 3rd decades and typically presents with low grade uveitis, iris heterochromia, complicated cataract and vitritis.

Viral posterior uveitis is caused by herpetic viruses HSV, VZV, CMV and Rubella, Measles and Arbo virus [Chikungunya, West Nile, Dengue] commonly and rarely Ebola and Zika virus. The most frequent causes of viral posterior uveitis come from the herpetic virus family.⁸ In the immunocompromised patients the 2 common posterior segment presentations are CMV retinitis and Progressive outer retinal necrosis [PORN]. CMV retinitis presents as pale yellow retinitis patches with occlusive vasculitis causing hemorrhages giving the classical appearance of pizza pie and a typical brush fire spread along blood vessels. In PORN there is outer retinal whitening giving a cracked mud appearance. Retinal hemorrhages are usually absent. Acute retinal necrosis [ARN] is seen in both immunocompetent and immunocompromised patients. Usually unilateral but can involve the other eye in 65% of cases. Retinitis with retinal necrosis starts in the peripheral retina and spreads rapidly circumferentially and towards the posterior pole with dense vitritis in immunocompetent individuals. Ocular manifestations of Arbo viruses follow 4-6 weeks after an episode of febrile illness

associated with headache, arthralgia or arthritis and skin rash. Retinitis lesions are bilateral, multifocal involving the posterior pole and there are cotton wool spots, arteritis, optic neuritis and macula edema. Foveolitis has been seen with infections with dengue and chikungunya viruses.⁹ These lesions show poor response to antivirals but respond well with corticosteroids.

Atypical viral anterior uveitis

Viral cause of anterior uveitis may be underestimated. Some of the recurrent idiopathic anterior uveitis may be proved to be of viral origin with the emergence of molecular diagnostics like Polymerase chain reaction [PCR] and Goldman Witmer Coefficient[GWC] assay.¹⁰

Recurrent bilateral granulomatous anterior uveitis:

Viral anterior uveitis is classically unilateral but recurrent attacks of bilateral granulomatous anterior uveitis usually with or rarely without IOP rise should raise the suspicion of viral etiology. Ocular hypertension may be severe enough to cause corneal edema. Torre *et al.*, has described three patients of herpetic bilateral anterior uveitis with elevated IOP, paralytic mydriasis and iris transillumination defects. In all three cases the diagnosis of Herpes simplex was supported by herpes specific antibody titers and aqueous humor PCR. Broad based posterior synechiae classically seen in Sarcoid and Tuberculous uveitis is significantly absent in viral uveitis.

Recurrent unilateral iridocyclitis:

History of multiple episodes of iritis in 1 eye should alert the clinician of a viral cause. There may be a past history of fever with viral exanthem. The presence of any one of the following clinical signs like one or two granulomatous KPs, Descemet's membrane folds, elevated IOP or iris atrophic patches could point to a viral etiology. Furthermore steroid recalcitrant anterior uveitis has a high likelihood of viral infection[67%]. In a study in Thailand CMV was identified by PCR and GWC assay as a cause for unilateral recurrent anterior uveitis.¹¹

Anterior uveitis with pigment dispersion:

This may be an unusual manifestation of viral uveitis.¹² The presentation is unilateral with fine pigments on the endothelium. There may be depigmentation of the iris, pigments and cells in the anterior chamber and a hyperpigmented trabecular meshwork on gonioscopy. Transillumination defects of the iris characteristic of Pseudoexfoliation syndrome and Pigment dispersion syndrome are absent here. This condition may be associated with pigmented, blood streaked hypopyon. Pigment dispersion is due to the virus invading the root of the iris and causing occlusive vasculitis. Another

clinical entity that has to be differentiated here is Bilateral acute depigmentation of the iris[BADI]. This is an idiopathic condition with bilateral symmetrical presentation. Active KPs and intraocular inflammation are characteristically absent.

Corneal endothelitis:

This is an intriguing clinical entity. It may involve a focal area of the cornea or it can be diffuse (fig 2), (fig 3).

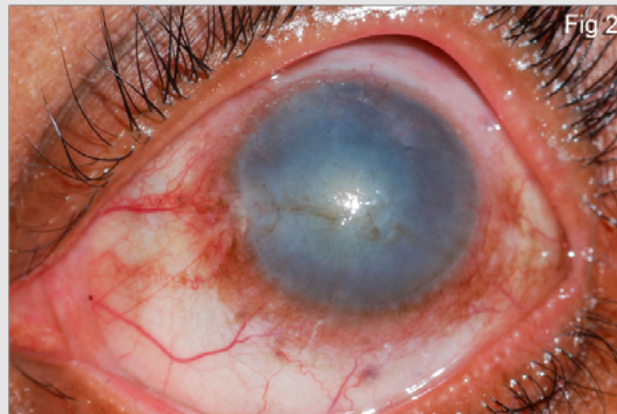


Figure 2

Figure-2: Left eye diffuse anterior segment photograph showing conjunctival and circumciliary congestion with diffuse corneal edema with pigmentation secondary to viral corneal endothelitis.

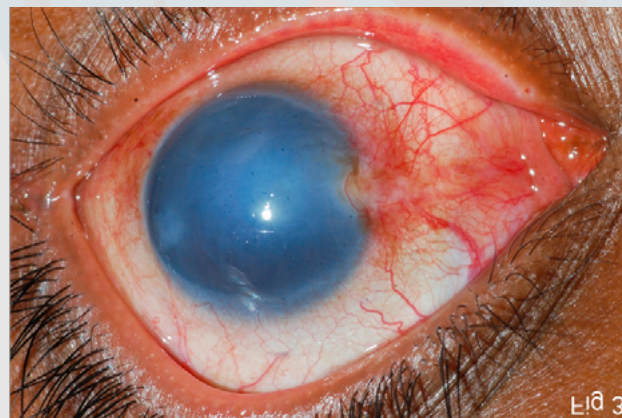


Figure 3

Figure-3: Diffuse anterior segment photograph of the right eye showing nasal pterygium, temporal corneal scar, disciform keratitis with corneal edema secondary to viral endothelitis.

There is stromal edema and Descemet's membrane[DM] folds with few granulomatous KPs in the involved area. IOP may be elevated. Its etiology is mainly attributed to the Herpes viruses. HSV and VZV endothelitis the stroma may progress to scarring.¹³ Adenovirus is also implicated as a cause for endothelitis.¹⁴ This occurs 3-4 weeks after an episode of adenoviral conjunctivitis associated with preauricular lymphadenitis. Besides the stromal edema and DM folds there are typical subepithelial nummular infiltrates. The endothelium has a ground glass appearance and appears blurred on

specular microscopy. There can be immune ring formation similar to HSV keratitis. Epithelial and stromal opacities may not be present. CMV endothelitis can be recognized by coin shaped lesions on the endothelium in addition to stromal edema. Here the KPs are arranged in a ring like fashion (fig 4). Anterior uveitis may be mild or absent

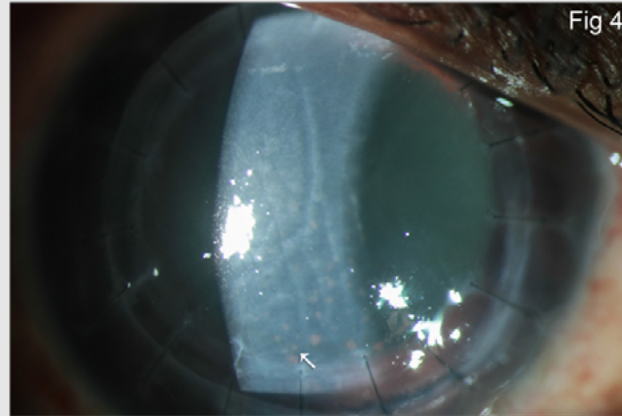


Figure 4

Figure-4: Full thickness penetrating keratoplasty graft with multiple DM folds pigmented coin shaped keratic precipitates in CMV anterior uveitis.

Fuchs like uveitis:

Rubella virus in the West and CMV in Singapore, Taiwan and Japan have been implicated as a cause for Fuchs uveitis syndrome. Besides the classical features like diffuse white stellate KPs and diffuse iris atrophy larger granulomatous pigmented KPs may be seen at the center of the cornea. Patients with this atypical presentation have more significant vitritis, rapid progression of cataract or presence of cataract at presentation.¹In another atypical presentation the iris defects may be significantly absent. Fuchs uveitis requiring topical corticosteroids for symptomatic relief and aggressive uveitis from childhood progressing to secondary glaucoma are very atypical manifestations.¹⁵As Fuchs is classically unilateral a bilateral presentation with dense vitritis and posterior segment signs is atypical and requires detailed investigation.¹⁶

Post viral conjunctivitis anterior uveitis:

Seen rarely following an episode of epidemic keratoconjunctivitis caused by adenovirus. Uveitis follows 1-3 weeks after the episode of viral conjunctivitis. Corneal subepithelial nummular infiltrates or scars with or without disciform keratitis is a clue to the viral etiology. ¹⁷The uveitis is mild to moderate and is associated with fine endothelial dusting. The condition responds well to a course of topical steroids

CMV anterior uveitis:

CMV has also been implicated in Posner Schlossman syndrome[PSS] and as a rare cause of persistent anterior uveitis accompanied by increase in IOP. Acute CMV anterior uveitis is seen in patients in the 3rd to 4th decade. Usually unilateral ocular symptoms are mild with low grade AC reaction and absence of vitritis. White KPs are seen distributed in a ring like fashion or linear pattern near the limbus. Coin shaped lesions and central nodular endothelial lesions surrounded by a halo point to CMV infection.¹⁸ Endothelial nodules can be demonstrated in AS OCT. Bilateral presentation has been reported and is considered atypical.¹⁹

Chronic CMV anterior uveitis is more common in patients in 5th to 7th decade. Cornea shows diffuse stellate KPs like as in Fuchs, coin shaped lesions or endothelitis with DM folds and underlying KPs. Iris stromal atrophy is usually diffuse. CMV positive eyes are more likely to require filtration surgery.

Scleritis/Episcleritis:

This is yet another atypical manifestation of viral infection. Poor response to topical and systemic steroids and all other etiologies ruled out, a prior history of herpes zoster ophthalmicus should alert the clinician of the possibility of a viral cause. Herpetic scleritis is usually unilateral, diffuse anterior scleritis. Rarely limbal devascularization and peripheral corneal thinning are seen. The center of the cornea is usually clear, rarely there can be granulomatous KPs (fig 5).

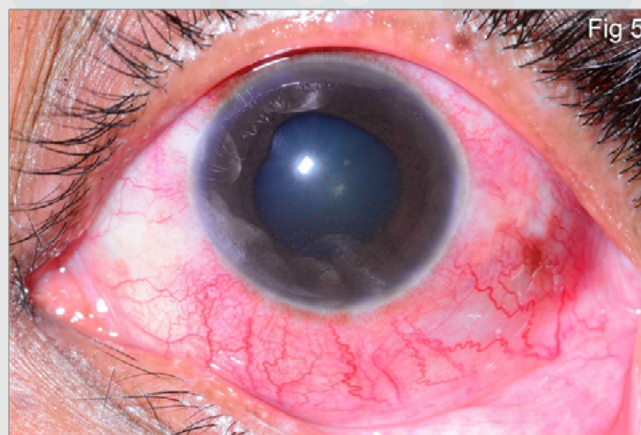


Figure 5

Figure-5: Sclerouveitis left eye showing scleritis with pigmented granulomatous keratic precipitates.

The lack of typical corneal findings in viral scleritis usually delays the diagnosis. Viral scleritis can be diagnosed by immunohistochemical studies of scleral biopsy and serological tests for HSV and VZV.²⁰ Viral scleritis responds to acyclovir or valacyclovir with oral corticosteroids in 2-8 weeks

Recurrent idiopathic anterior uveitis with elevated IOP could have a viral etiology. PCR of AC fluid and Goldman Witmer coefficient combination increases the proportion of cases identified as having viral etiology.

Table 1. summarises the typical and atypical manifestations of viral anterior uveitis.

Typical	Atypical
1. Unilateral	1. Bilateral
2. Pigmented ,granulomatous KPs, DM folds, elevated IOP	2. Only 1 or 2 of typical features
	3. Pigment dispersion on endothelium with inflammation
	4. Coin lesions
	5. Scleritis

Atypical viral posterior uveitis

Atypical non necrotizing herpetic retinitis [NNHR]:

Peripheral retinitis, diffuse occlusive vasculitis, peripheral neovascularization, retinal edema and vitreous hemorrhage are signs of retinal necrosis. These features are typical of herpetic acute retinal necrosis [ARN]. The vitritis is dense. In NNHR patient presents with blurred vision and ocular pain. Clinically the AC reaction, vasculitis and vitritis is mild. The progression of the retinitis patch is slow and does not destroy the involved retina.²¹ Prognosis is better than in necrotizing retinitis. Occlusive vasculitis is associated with worse visual acuity at follow up.²² Complications include multiple recurrences of anterior uveitis, CME, retinal detachment,retinal atrophy,band keratopathy and cataract. Herpetic viruses are the causative organisms of this condition and diagnosis can be confirmed by PCR for VZV and HSV and viral serology by ELISA. Treatment is with antivirals for 6-8 months along with corticosteroids.

Hemorrhagic variant of VZV retinitis:

This atypical presentation was described in an AIDS patient. The retinitis was peripheral and was seen as retinal whitening. There was associated peripapillary edema with hemorrhages and dense vitreous hemorrhage. ²³PCR of vitreous sample obtained during vitrectomy was positive for VZV and negative for CMV.

Atypical ARN:

Typical ARN according to the American uveitis society includes focal well demarcated areas of retinal necrosis, peripheral location of retinal necrosis, rapid circumferential progression, occlusive vasculitis and prominent inflammatory reaction in the vitreous. A score of less than four is designated as atypical ARN. If progression of the retinitis and the necrosis is very slow it is considered an atypical variation. This slower progression of the retinitis is related to the better immune response of the host. Involvement of the posterior pole and the macula at presentation is atypical of ARN.²⁴

Multifocal posterior necrotizing retinitis is an atypical presentation described by Margolis *et al.*, as a pattern of herpetic retinitis in immunocompetent individuals affecting the post pole.²⁵ The lesions were multifocal, deep and posterior to the vortex veins at presentation with some of the lesions involving the macula. There was no difference between typical ARN and this atypical presentation in the incidence of vitritis, AC reaction sheathing of retinal vessels or disc edema. The prognosis is bad and has a high rate of retinal detachment.

Wickremasinghe *et al.*, has described anterior herpetic uveitis with arteriolar sheathing in 1 or more quadrants of the retina with no retinitis patches. PCR of the vitreous sample was positive for VZV. Likewise Winseng *et al.*, has described herpetic viral uveitis with only vasculitis and papillitis without any necrotic retinitis lesions.²⁶ All patients showed positive report by PCR for viruses VZV and HSV from aqueous or vitreous samples or Goldman Witmer coefficient of 10 or more. Also described is occlusive vasculitis with NVD and NVE and no retinal necrosis. Bilateral frosted branch angiitis characterized by active diffuse sheathing of retinal vasculature mainly peripheral arterioles and venules with or without active retinitis is yet another manifestation of atypical viral uveitis associated with CMV infection.²⁷ (fig 6)

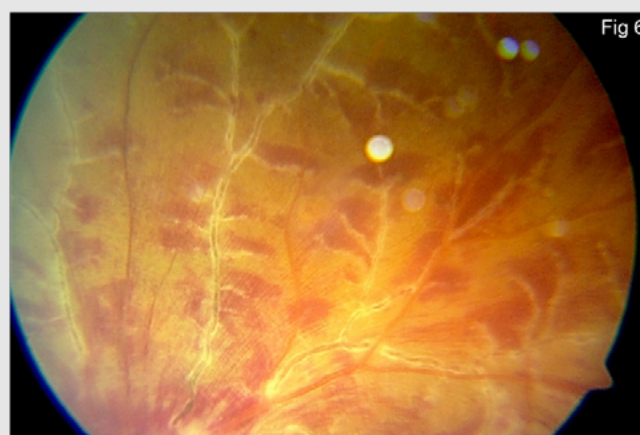


Figure 6

Figure-6: Fundus photograph of the left eye showing frosted branch angiitis in CMV retinitis.

Retinal biopsy and electron microscopy of the samples detected virions morphologically consistent with CMV. Combined occlusion of central retinal artery and vein shortly after herpes zoster ophthalmicus [HZO] has been reported. Similarly orbital apex syndrome with uveitis after an episode of HZO has been described as atypical and a rare manifestation.

The different clinical forms of viral retinitis are related to the number of viruses in the eye and the immune response of the host. In ARN though seen in immunocompetent individuals a decline in cellular immunity may be present. So focal retinitis, NNHR, mild ARN occur in patients who have better functioning cellular immunity than patients with full blown ARN.

HIV retinitis:

Seen in HIV positive patients and characteristically presents with multifocal retinal infiltrates in the mid periphery.²⁷ There is no associated vitritis, vasculitis or vitreous hemorrhage. AC reaction is also absent. Features of opportunistic infections like CMV retinitis and PORN are not seen. Rarely there may be peripheral retinal infiltrates and low grade vitritis. The condition can be diagnosed by positive HIV serology by ELISA for antibodies to p24 antigen.

CMV posterior uveitis in immunocompetent patients:

CMV retinitis can occur in immunocompetent individuals. Most patients have some degree of immune dysfunction such as uncontrolled or long standing diabetes, advanced age, corticosteroid or immunosuppressive intake. Literature has described varying manifestations of CMV retinitis in immunocompetent patients. Kaplan *et al.* has reported a case of hemorrhagic retinitis in a 64 year old man who was using Difluprednate eye drops after penetrating keratoplasty. PCR of the vitreous was positive for CMV DNA. Yoshinaga described CMV retinitis in two immunocompetent patients both above 60 years of age. Fundus showed yellow white retinal lesions with arteriolar sheathing. In other reports significant anterior cellular activity was present with granulomatous or non granulomatous KPs. The IOP was usually elevated. No retinitis lesions were seen but FFA and ICGA have demonstrated disc leak and phlebitis.²⁸ AC fluid was positive for CMV by PCR. Unlike in immunocompromised patients CMV retinitis in immunocompetent patients have significant anterior chamber inflammation and vitritis. CMV retinitis should be considered in the differentials in immunocompetent adults with comorbidities. Drugs used in the treatment are Ganciclovir, Valganciclovir, Cidofovir and Foscarnet. They completely inhibit CMV DNA polymerase.

Table 2 summarises the typical and atypical manifestations of viral posterior uveitis.

Typical	Atypical
1. ARN Rapid progression	1. Slow progression
2. Dense vitritis	2. Mild vitritis
3. Minimal hemorrhage	3. Dense vitreous hemorrhage
4. Peripheral lesions	4. Multifocal posterior pole lesions
	5. Vasculitis, papillitis without retinitis

Conclusion:

Viral uveitis cause a wide spectrum of clinical manifestations The index of suspicion for a viral etiology should be high in presence of unilateral ocular hypertension, iris atrophy, pigmented KPs and posterior segment findings of necrotizing or non necrotizing retinitis. Atypical manifestations of viral uveitis should be borne in mind. The non necrotizing variants of ARN are currently underdiagnosed. Quantitative PCR and GWC assay are preferred methods of confirming the etiology and atypical variants could benefit from earlier diagnosis and management. If it is associated with systemic viral infections PCR from the blood and serological antibodies can also contribute to the clinical diagnosis. Next generation sequencing can be useful to diagnose atypical viral uveitis in future.

References and suggested reading:

1. *Chan NS-W, Chee S-P. Demystifying viral anterior uveitis: A review. Clin Experiment Ophthalmol. 2019;47(3):320-33. (This article highlights differentiating clinical features of anterior uveitis caused by HSV,VZV,CMV,Rubella virus)
2. Pleyer U, Chee S-P. Current aspects on the management of viral uveitis in immunocompetent individuals. Clin Ophthalmol. 2015;9:1017–28.
3. Groen-Hakan F, Babu K, Tugal-Tutkun I, Pathanapithoon K, de Boer JH, Smith JR, *et al.* Challenges of Diagnosing Viral Anterior Uveitis. Ocul Immunol Inflamm. 2017;25(5):710-20.
4. Suzuki J, Goto H, Komase K, Abo H, Fujii K, Otsuki N, *et al.* Rubella virus as a possible etiological agent of Fuchs heterochromic iridocyclitis. Graefes Arch Clin Exp Ophthalmol. 2010;248(10):1487-91.
5. Chee S-P, Jap A. Presumed fuchs heterochromic iridocyclitis and Posner-Schlossman syndrome: comparison of cytomegalovirus-positive and negative eyes. Am J Ophthalmol. 2008;146(6):883-889.e1.

6. Atypical Bilateral Fuchs Uveitis: Diagnostic Challengesb Dana Faingold,a Carmen demetrio,b Ariel Schlaen,b Marcelo Zas,b Jorge Zarate,c Silvia Rosetti,d Andrea Paes de Lima,c Juan Oscar Croxatto,d Pablo Chiaradía,b and Miguel N. Burniera
7. Hedayatfar A, Chee S-P. Posner-Schlossman syndrome associated with cytomegalovirus infection: a case series from a non-endemic area. *Int Ophthalmol*. 2014;34(5):1123-9.
8. Sudharshan S, Ganesh SK, Biswas J. Current approach in the diagnosis and management of posterior uveitis. *Indian J Ophthalmol*. 2010;58(1):29-43.
9. Oliver GF, Carr JM, Smith JR. Emerging infectious uveitis: Chikungunya, dengue, Zika and Ebola: A review. *Clin Experiment Ophthalmol*. 2019;47(3):372-80.
10. Groen-Hakan F, Babu K, Tugal-Tutkun I, Pathanapithoon K, de Boer JH, Smith JR, *et al*. Challenges of Diagnosing Viral Anterior Uveitis. *Ocul Immunol Inflamm*. 2017;25(5):710-20.
11. Kongyai N, Sirirungsi W, Pathanapitoon K, Tananuvat N, Kunavisarut P, Leechanachai P, *et al*. Viral causes of unexplained anterior uveitis in Thailand. *Eye (Lond)*. 2012;26(4):529-34.
12. Tugal-Tutkun I, Urgancioglu M. Bilateral acute depigmentation of the iris. *Graefes Arch Clin Exp Ophthalmol*. 2006;244(6):742-6.
13. Woodward MA. Herpes simplex virus stromal keratitis and endotheliitis. *Americal Academy of Ophthalmology*; 2017 Feb 17. Available from: https://eyewiki.aao.org/Herpes_simplex_virus_stromal_keratitis_and_endotheliitis
14. Wang S-Y, Li B, Li D-H, Tian Y. Adenovirus-mediated corneal endothelitis: a case report. *Int J Ophthalmol*. 2019;12(10):1659-61.
15. Phu J, Trinh WH, Chau-Vo JS, Nivison-Smith L, Kalloniatis M. Atypical Features of Fuchs Uveitis Syndrome. *Optom Vis Sci*. 2015;92(11):e394-403.
16. Couto C, Hurtado E, Faingold D, Demetrio C, Schlaen A, Zas M, *et al*. Atypical Bilateral Fuchs Uveitis: Diagnostic Challenges. *Case Rep Ophthalmol*. 2015;6(3):284-8.
17. Ghebremedhin B. Human adenovirus: Viral pathogen with increasing importance. *Eur J Microbiol Immunol (Bp)*. 2014;4(1):26-33.
18. Koizumi N, Inatomi T, Suzuki T, Shiraishi A, Ohashi Y, Kandori M, *et al*. Clinical features and management of cytomegalovirus corneal endotheliitis: analysis of 106 cases from the Japan corneal endotheliitis study. *Br J Ophthalmol*. 2015;99(1):54-8.
19. Elia M, Huang JJ, Gaudio PA, Cytomegalovirus Anterior Uveitis in Immunocompetent Patients. *EyeNet*. 2016 May. Available from: <https://www.aao.org/eyenet/article/cytomegalovirus-anterior-uveitis-in-immunocompeten>
20. Ramenaden ER, Raiji VR. Clinical characteristics and visual outcomes in infectious scleritis: a review. *Clin Ophthalmol*. 2013;7:2113-22.

21. **Hazirolan D, Sungur G. Atypical Herpetic Viral Posterior Uveitis: Non-necrotising Retinitis and Focal Retinitis. *Journal of Infectiology*. 2019;2(3):8-12. Available from: <https://www.infectiologyjournal.com/articles/atypical-herpetic-viral-posterior-uveitis-nonnecrotising-retinitis-and-focal-retinitis.html> (this paper describes the clinical features of atypical non necrotising ARN and multifocal retinitis)
22. Viral posterior uveitis. *Surv Ophthalmol*. 2017; 62(4):404-445 (ISSN: 1879-3304) Lee JH; Agarwal A; Mahendradas P; Lee CS; Gupta V; Pavesio CE; Agrawal R
23. Lewis JM, Puklin JE. Varicella-zoster virus retinitis presenting as an acute vitreous hemorrhage. *Arch Ophthalmol*. 1998;116(1):104-5.
24. Vasudevan A, Rojas-Moreno C, Tarun T. Acute retinal necrosis secondary to Varicella Zoster Virus. *IDCases*. 2019;18:e00585.
25. *Margolis R, Brasil OFM, Lowder CY, Smith SD, Moshfeghi DM, Sears JE, *et al*. Multifocal posterior necrotizing retinitis. *Am J Ophthalmol*. 2007;143(6):1003-8. (the authors highlight a unique form of herpetic retinitis affecting the posterior pole)
26. **Wensing B, de Groot-Mijnes JDF, Rothova A. Necrotizing and nonnecrotizing variants of herpetic uveitis with posterior segment involvement. *Arch Ophthalmol*. 2011;129(4):403-8. (article describes the clinical features of 38 patients with herpetic posterior uveitis)
27. Spaide RF, Vitale AT, Toth IR, Oliver JM. Frosted branch angiitis associated with cytomegalovirus retinitis. *Am J Ophthalmol*. 1992;113(5):522-8.
28. Levinson RD, Vann R, Davis JL, Friedberg DN, Tufail A, Terry BT, *et al*. Chronic multifocal retinal infiltrates in patients infected with human immunodeficiency virus. *Am J Ophthalmol*. 1998;125(3):312-24.
29. Graefes *Arch Clin Exp Ophthalmol* 2014 Nov;252(11):1811-6 Posterior segment findings of ocular cytomegalovirus infection in immunocompetent patients Melissa H Y Wong 1, Gemmy C M Cheung, Soon-Phaik Chee



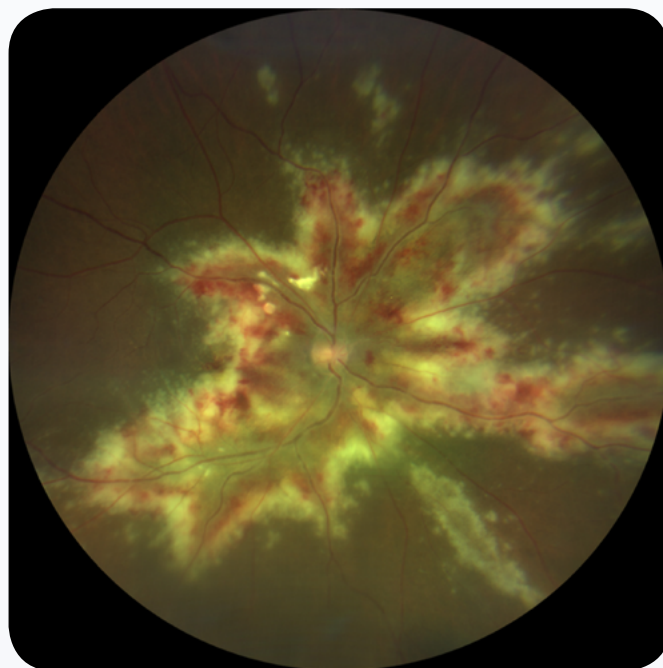


Photo Competition

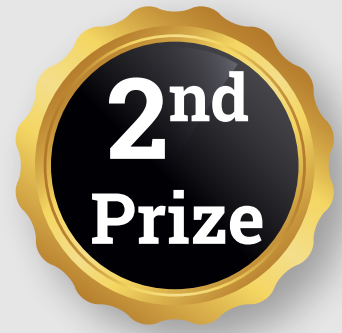**1st
Prize**

Name : Anamika Patel

Institution : L V Prasad Eye Institute

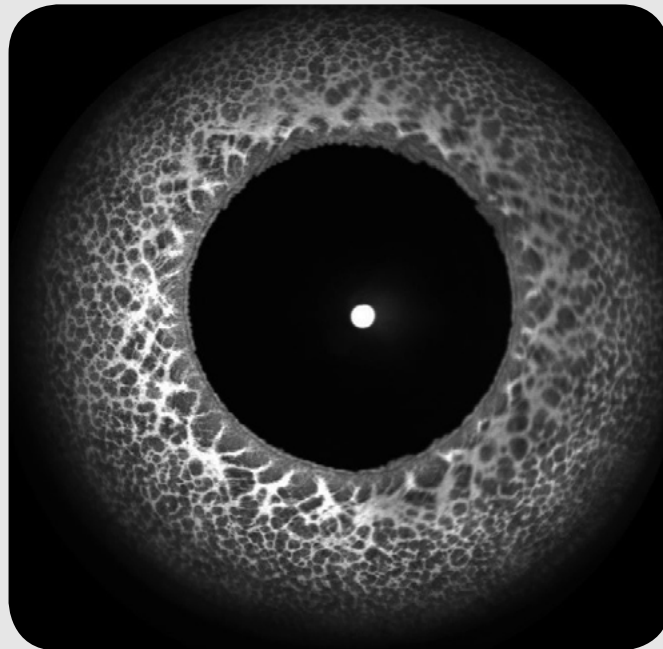


Legend: Right eye fundus photograph of a 36-year-old known HIV patient showing the presence of necrotizing retinitis in a star-like fashion spanning the arcade with the presence of hemorrhages lining the inner aspect of retinitis. She was diagnosed to have CMV retinitis and did well with oral and intravitreal gancyclovir treatment.



Name : Ankush Kawali

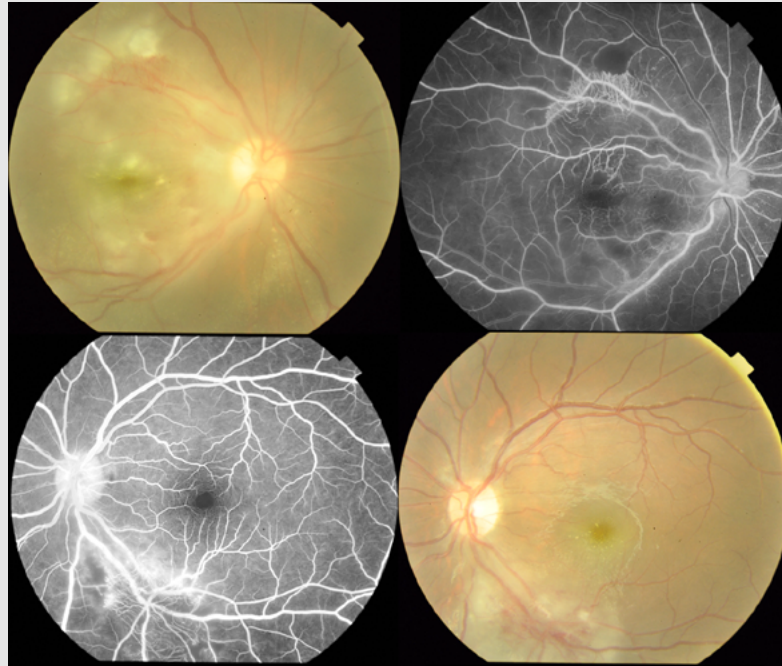
Institution : Narayana Nethralaya



Legend: Infra-red autofluorescence of the iris in a case of Fuchs' uveitis, enhancing the iris atrophic changes.

Name : Anamika Dwivedi

Institution : Shyam Shah Medical College, Rewa (M.P.)

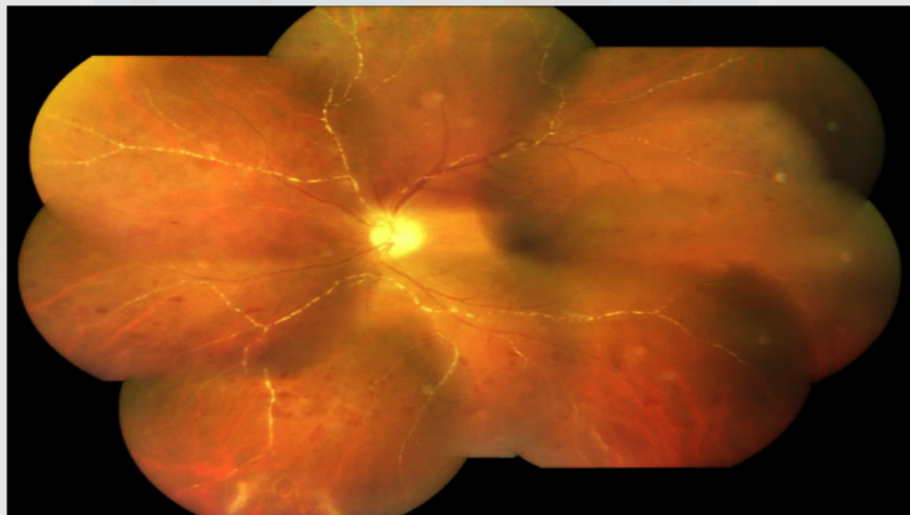


Legend : Unusual Retinal Neovascularization in Presumed Viral Retinitis



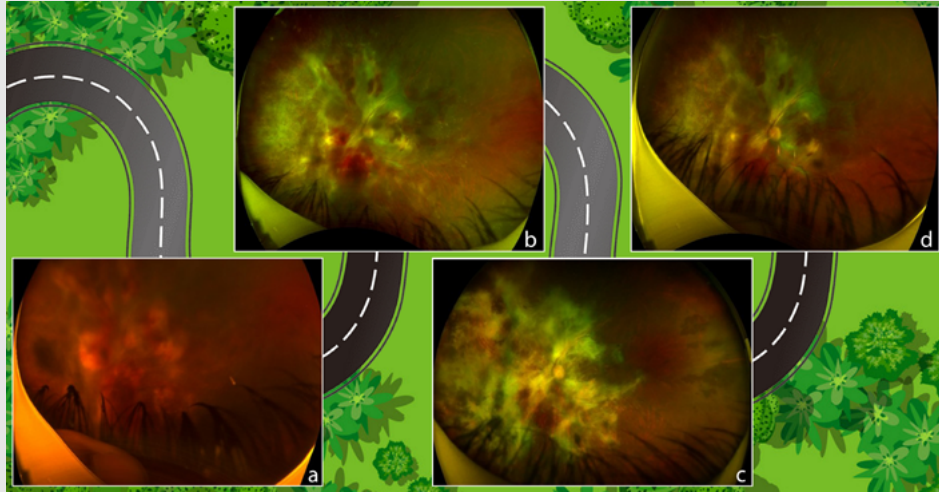
Name : Dhwani Shah

Institution : Prabha eye clinic and research centre



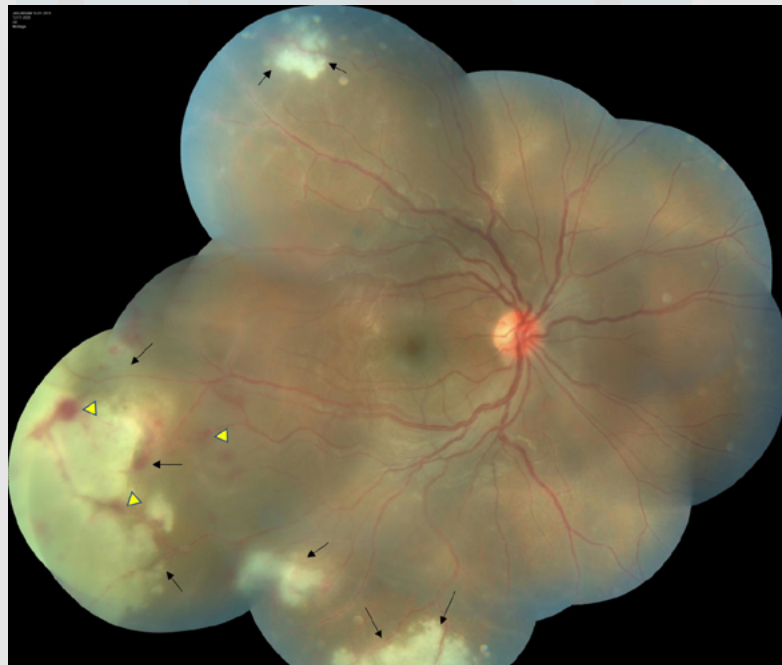
Legend : This is a fundus photo of a HIV positive man on HAART (CD4 – 60) with CMV retinitis. BCVA in left eye was 6/18. Fundus showed vitritis, sheathing, and a cordlike appearance of the arteries with veins unaffected in both eyes. Arterial involvement in CMV retinitis is in the form of kyrieleis arteriolitis or segmental arteritis. The increase in the arteritis during immune recovery strengthens the hypothesis of an immune response to an infectious agent and deposition of inflammatory debris in the vessel wall. Systemic HIV infection along with the CMV infection may be responsible for the occlusive arteries and the aggressive nature of neovascularization. Early recognition and aggressive treatment with intravenous ganciclovir and prophylactic laser photocoagulation reduces the visual morbidity in these cases.

Name : Srinivasan Sanjay
Institution : Narayana Nethralaya



Legend : “The “Viral” Road to Recovery”
A case of CMV retinitis treated with intravitreal ganciclovir and oral valganciclovir along with HAART.

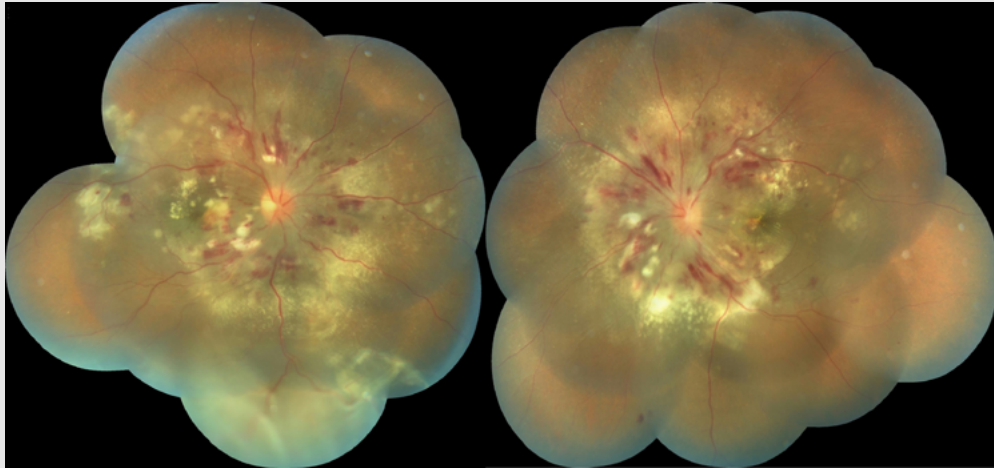
Name : Prashant Katre
Institution : Dr Shroff’s Charity Eye Hospital, New Delhi



Legend : Montage colour right eye fundus photograph of 11 year old male child showing mild vitritis, hyperaemic disc, whitish tongue shaped patches of confluent necrotizing retinitis in temporal, inferior and superotemporal periphery (black arrows), along with periarteritis and perivascular haemorrhage (yellow arrow heads). A clinical diagnosis of Acute Retinal Necrosis was made and confirmed on PCR of aqueous sample which was positive for HSV 1 and 2.

Name : Shalin Shah

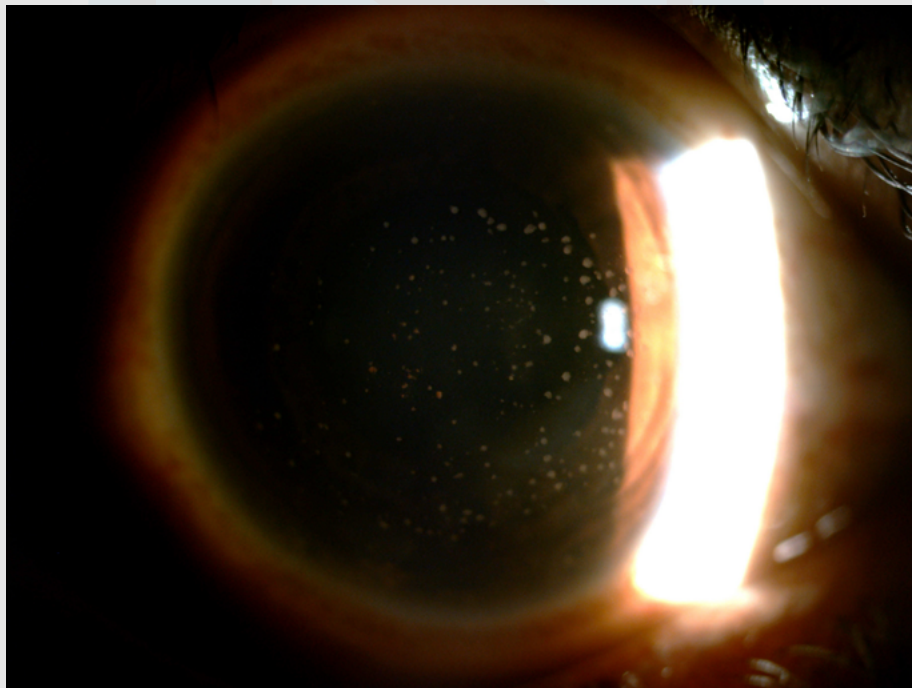
Institution : Dr Shroff's charity eye hospital, New Delhi



Legend : Both eye post viral fever retinitis with surrounding exudation and exudative retinal detachment in right eye

Name : Gazal Patnaik

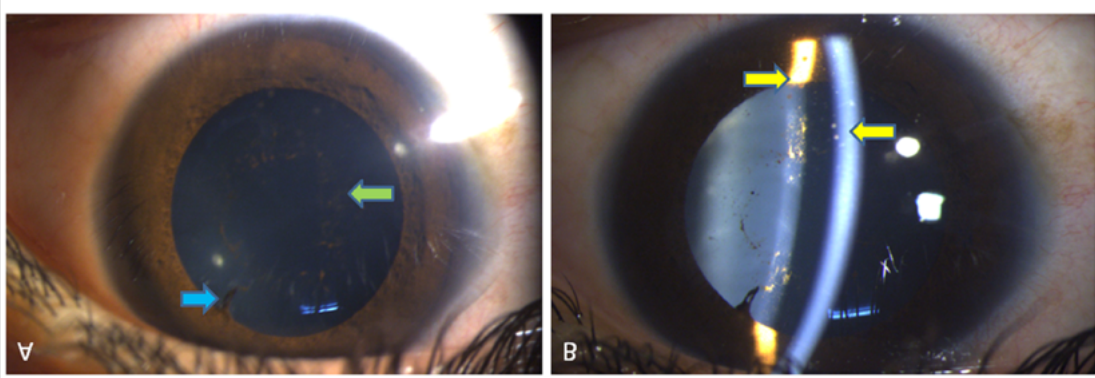
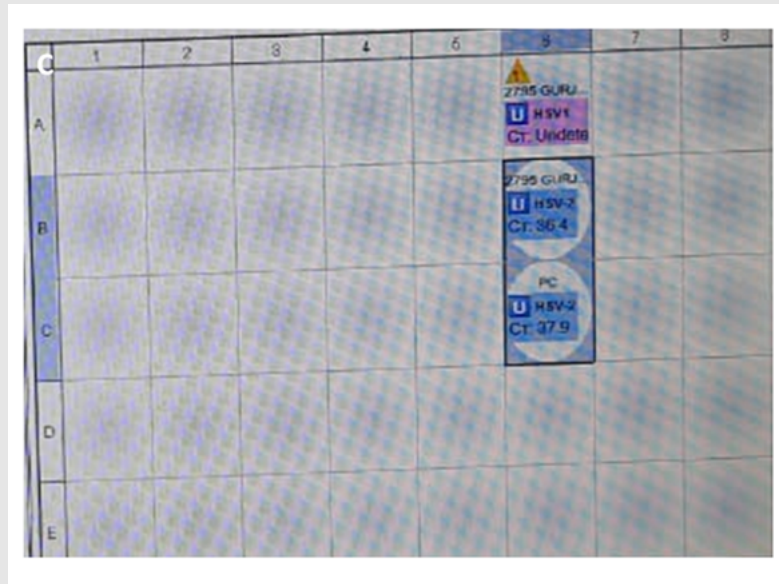
Institution : Medical Research Foundation, Sankara Nethralaya, 18- College Road, Nungambakkam



Legend : Slit lamp photograph of the right eye highlighting the typical coin - shaped keratic precipitates or endothelial deposits, diffusely distributed over the corneal endothelium in a case of polymerase chain reaction (PCR)-proven cytomegalovirus (CMV)-anterior uveitis.

Name : Nikita Gupta

Institution : PGIMER



Legend : A retro positive 30-year-old female presented with unilateral pain and redness in left eye for one month. Slit-lamp photo (figure A) showed diffuse conjunctival congestion with filiform posterior synechiae and pigments on anterior lens capsule. Focal illumination with slit beam showed pigmented keratic precipitates with cells in the anterior chamber. Anterior chamber tap revealed HSV-2 (Herpes simplex virus) viral genome by Taqman probe real-time PCR (figure C).





Survey by Uveitis Society (India) What change COVID-19 made in your real-time practice?

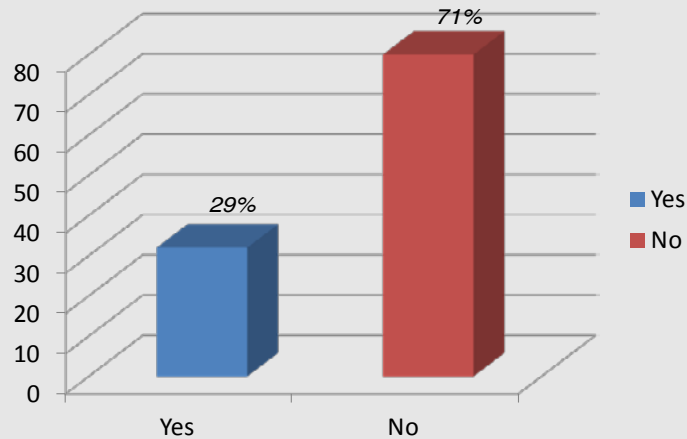


Dr. S Bala Murugan

Aravind Eye Care System, Pondicherry

Email: drbalamuruganms@gmail.com

1. Do you do / recommend to practice doing PCR for COVID-19 before starting immunosuppressives in COVID-asymptomatic patients in the current scenario?



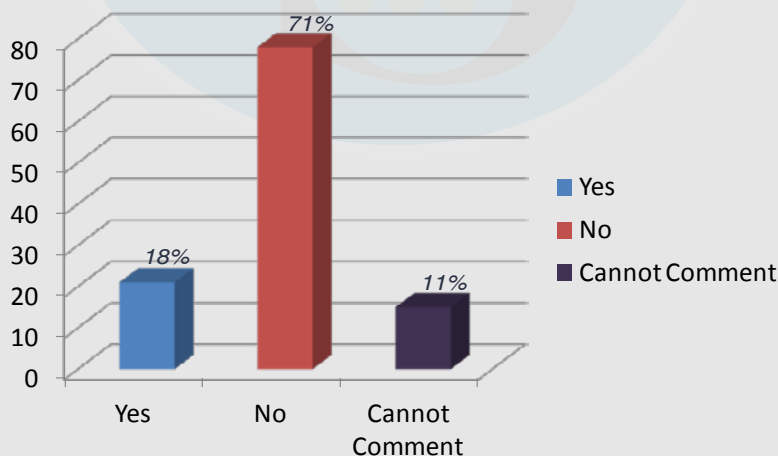
Other Responses

I guess you mean COVID+ asymptomatic pts. physician decides mainly before giving clearance.

With H/O

Other investigations like blood counts, ESR, CRP done

2. Do you strictly do HRCT- Thorax findings before starting any immunosuppressives or 1 mg/ kg oral steroids to look for CORADS Score in your practice now?



Other Responses

Referto rheumatologist who don't do that strictly

Do mantoux and X-Ray Chest

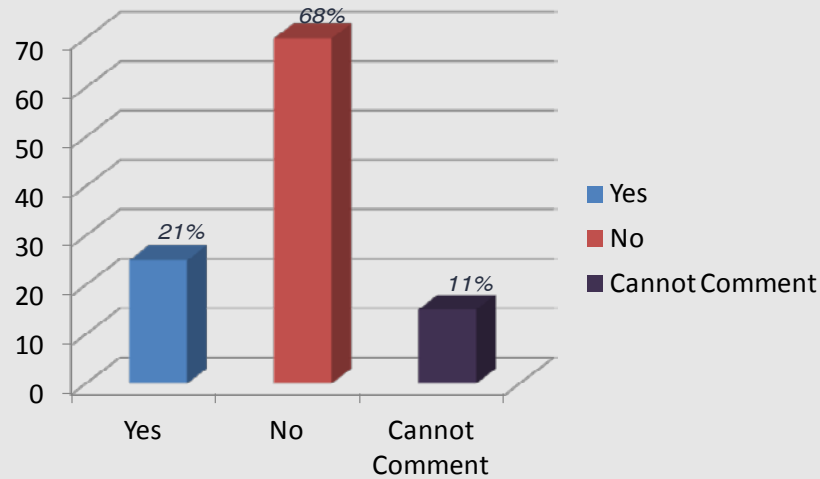
But would be useful and recommended. Chest Xray If CT not possible

I take rheumatologist's view before starting immunosuppressives.

Do CXR

HRCT - thorax is done in all uveitis patients needing systemic steroids routinely

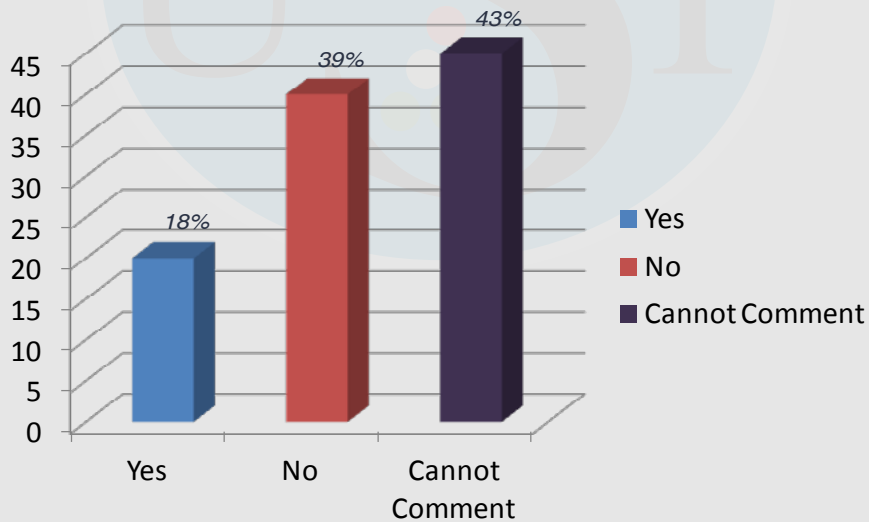
3. Do you do/ recommend to practice doing PCR for COVID-19 before starting parenteral steroids in patients not having COVID symptoms in the current scenario?



Other Responses

But will use CT Chest/ Xray before starting

4. Do you see OCT findings suggestive of COVID-19 in your practice or feel it is an artifact only?



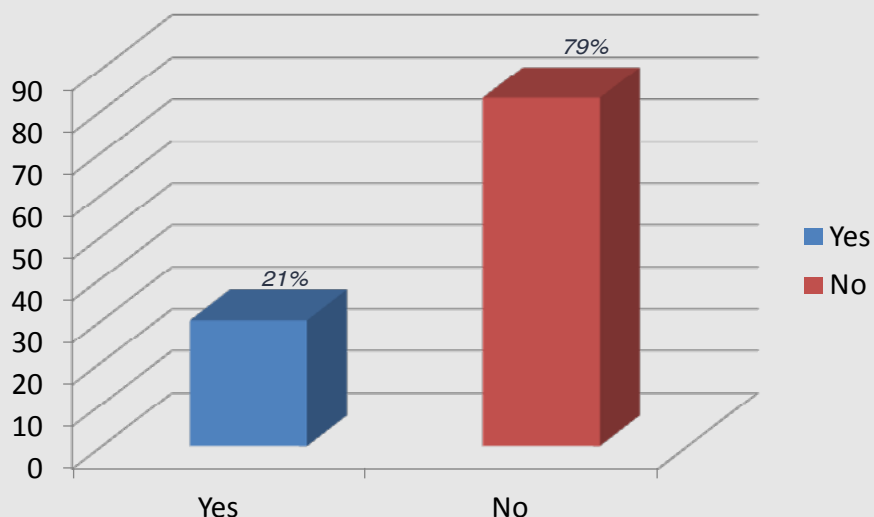
Other Responses

Not in uveitis patients

Seen and treated post COVID retinal vein occlusions in practice

No idea about oct findings in Covid-19

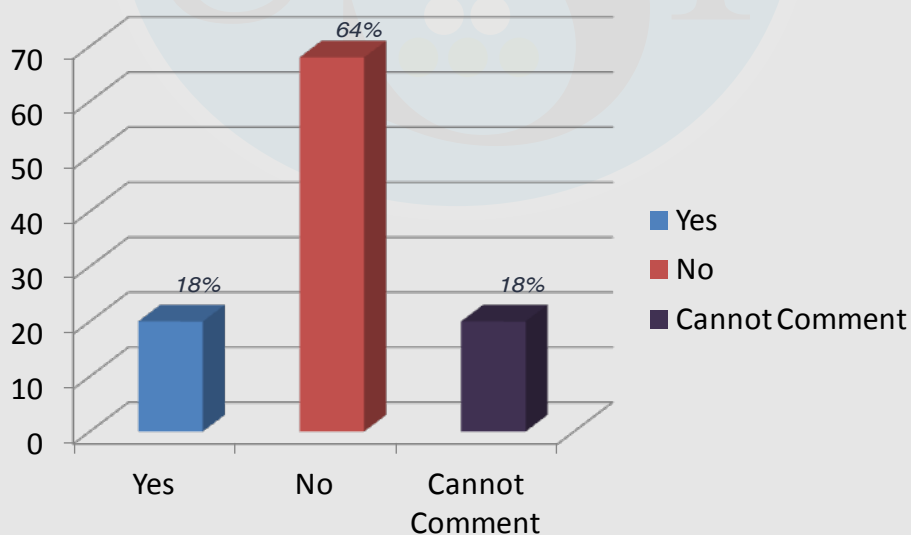
5. Do you do/ prefer to give more of local steroids [periocular/ intraocular steroids] when you feel like starting parenteral steroids like in a proven case of acute VKH. ?



Other Responses

I have not come across such a case in the present scenario

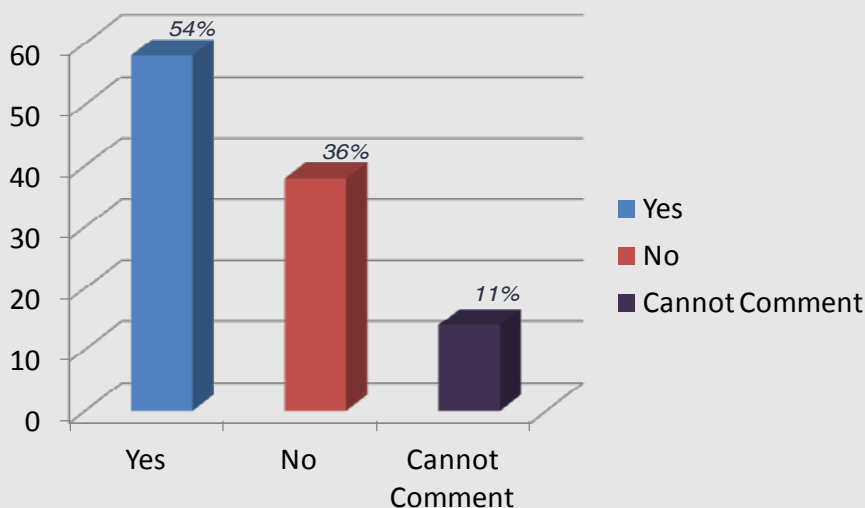
6. Do you check Oxygen saturation [Sp O2] of patients on immunosuppressives/ high dose steroids to assess silent happy hypoxia?



Other Responses

Desirable

7. Do you strictly practice N95 masking of patients who undergo Fundus fluorescein Angiogram/ Indigocyanine green Angiogram for prolonged contact time?



Other Responses

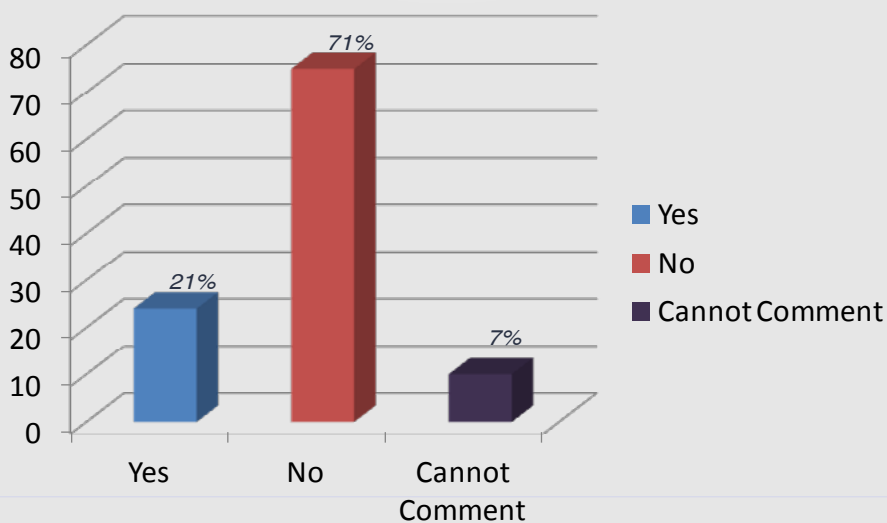
Do not have that facility

Always and strictly

We practice strict N95 masking for technicians performing FFA/ICGA

I do RTPCR before FFA

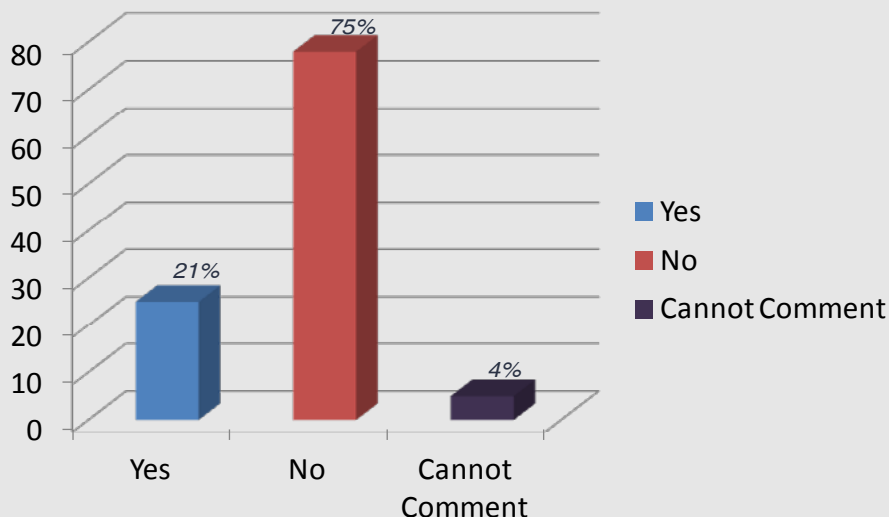
8. Do you use the markers to suggest COVID-19 like raised Neutrophil: Lymphocyte ratio, raised ferritin, raised D-Dimer, raised acute phase reactants before starting high dose steroids/ immunosuppressants?



Other Responses

But CBC ESR CRP is routinely done for all uveitis

9. Do you check COVID antibodies in otherwise healthy patients with uveitis not fitting into any known uveitic entity?

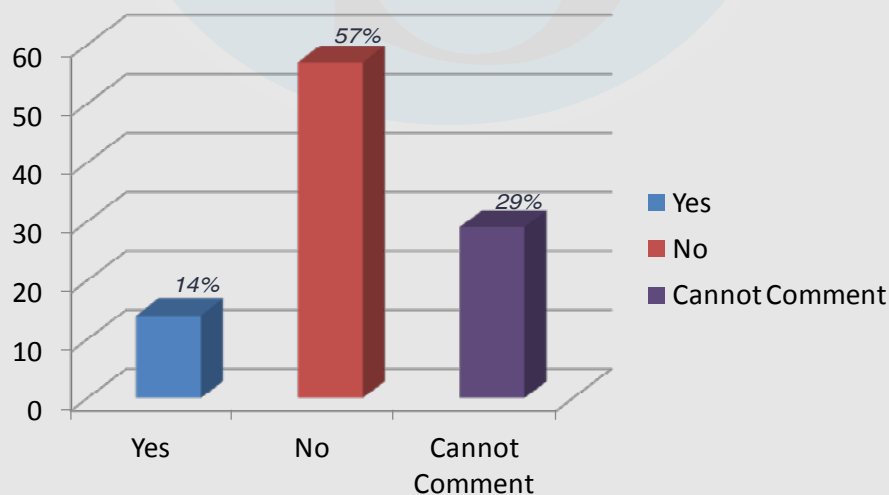


Other Responses

Very rarely in 2 patients only with vascular occlusions

None have come positive as yet

10. Do you frequently see relapse of pre-existing uveitis after COVID infection?

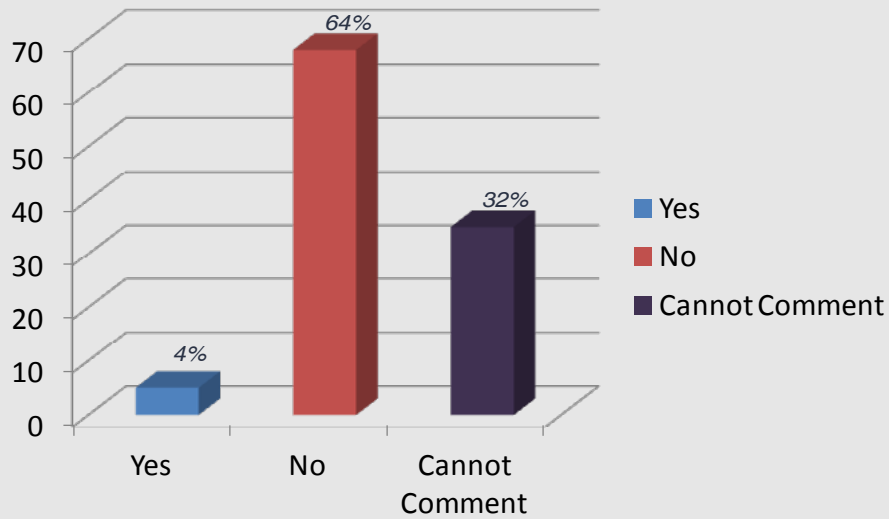


Other Responses

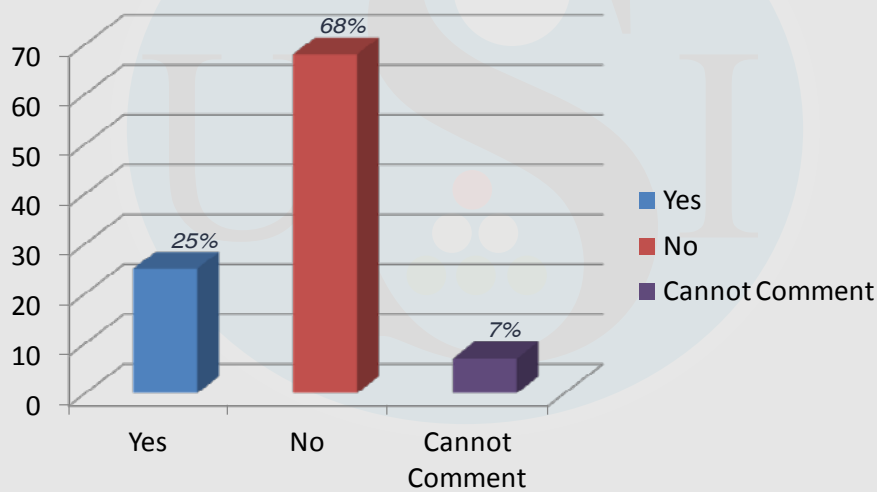
We had high number of HLA B 27 uveitis patients

Have seen post COVID recovered patients, none showed uveitis

11. Do you frequently see remission of pre-existing active uveitis after COVID infection?



12. Do you frequently see post COVID coagulopathy related ocular complications?



Other Responses

Undue increase in vascular occlusions

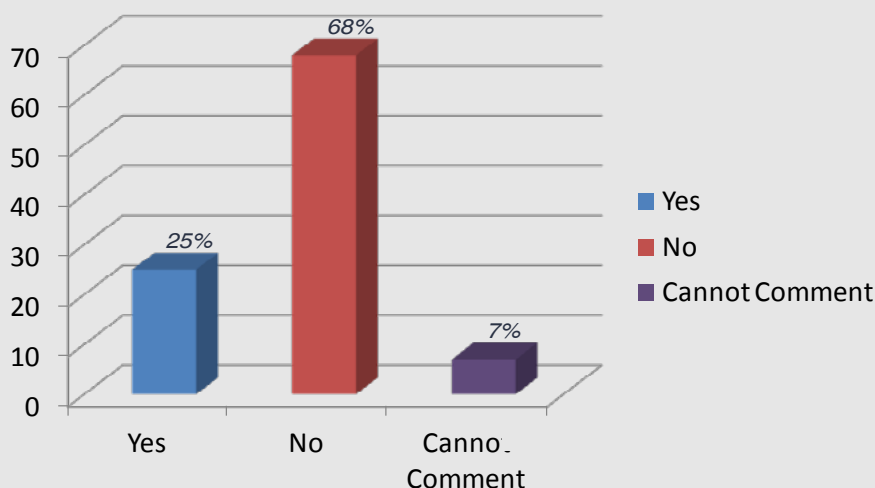
Yes looks like little more, but not analysed data, so may be a bias

Retinal vein occlusions

But occasionally yes

But not frequently

13. Do you frequently see post COVID inflammatory ocular complications?



Other Responses

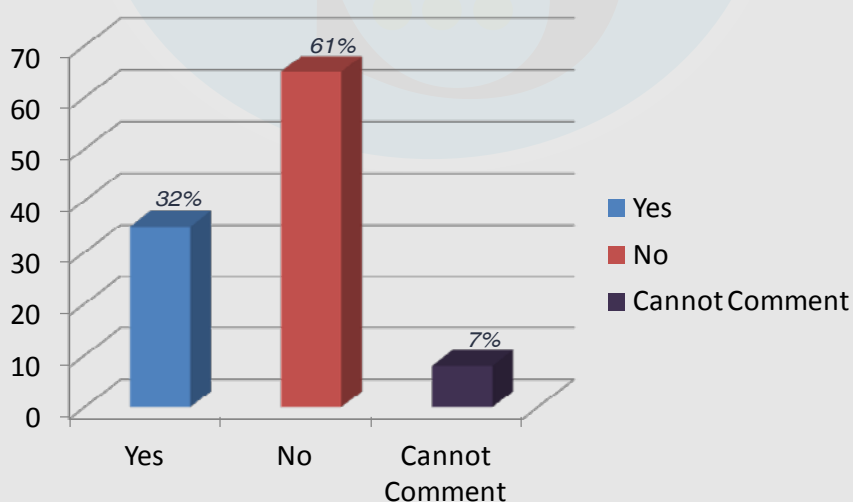
Iritis

Fungal endogenous endophthalmitis

Saw scleritis and multifocal choroiditis in 2 patients- whether related to covid is a speculation

But not frequently

14. Do you see post fever retinitis post COVID-19 in your practice now?



Other Responses

Seen 1 patient who presented like HZV retinitis

but rare

But seeing more posterior uveitis now

6 cases so far



QUIZ ANSWERS

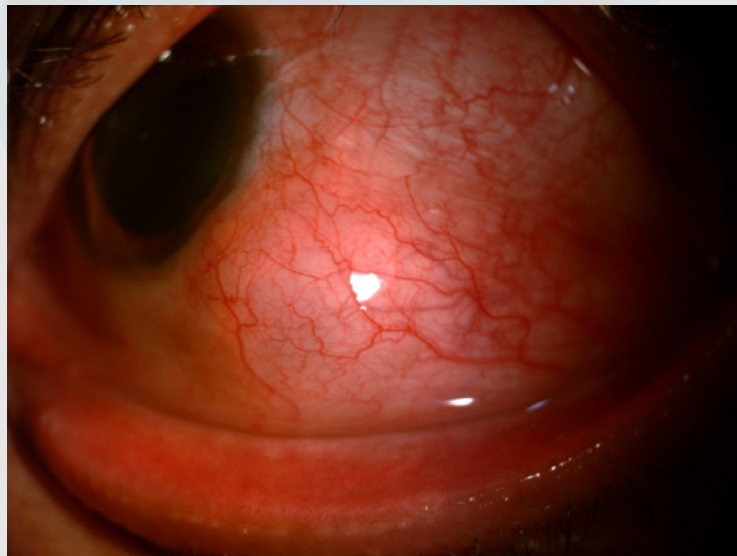
Case 1

Syphilitic serology was positive and resolution with intramuscular benzathine penicillin was conclusive of syphilitic nodular scleritis.

Scleritis is a rare finding in ocular syphilis, accounting for only 3% of cases and with anterior nodular scleritis as the most common manifestation.

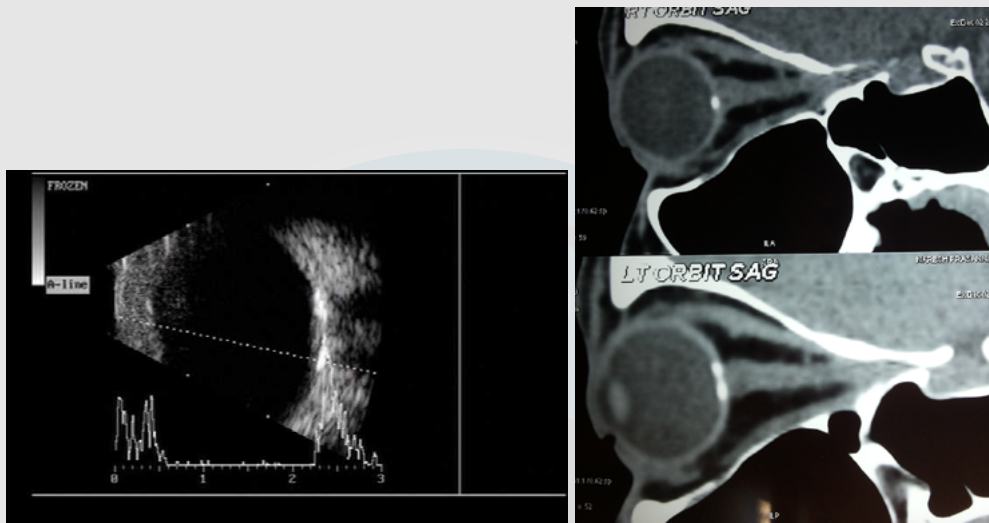
Syphilitic scleritis demonstrates a dramatic response to penicillin therapy with a rapid resolution of the nodules by 1 to 2 weeks of the first dose of antibiotic.

A high index of suspicion for this masquerade has to be kept in mind and a thorough history eliciting exposure risks is essential for rapid diagnosis and treatment.



Case 2

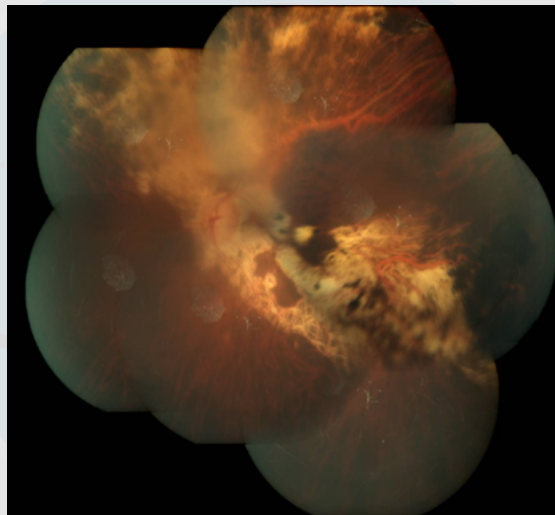
A pseudo-optic nerve sign in ocular ultrasonography is characteristic of choroidal osteoma, which is due to the presence of calcified components. The diagnosis of this benign tumour is mainly clinical, with a orange-yellow distinct lesion, usually juxtapapillary or macular in location, with a predilection for females. A hyperintense signal on T_1 -weighted and low intense signal on T_2 -weighlied images on MRI scan of brain and orbit is also supportive of the diagnosis. Special attention has to be given for any presence of choroidal neovascularisation, which has been reported in around 31-47% of cases.



Case 3

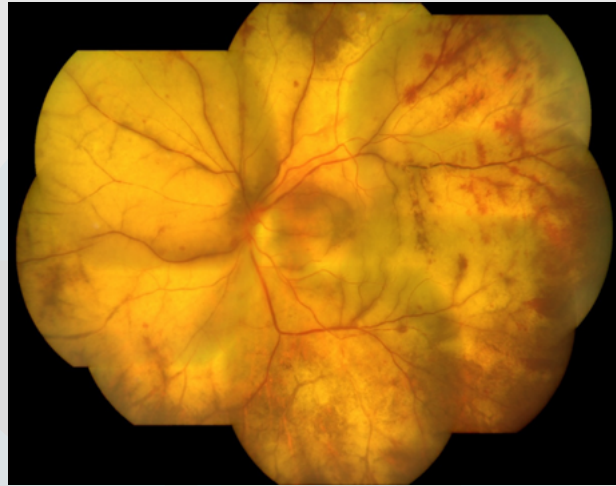A history of intravenous drug administration for lobar pneumonia a year ago was revealed. A negative serology, blood culture, no response to anti-toxoplasma agents led to a diagnostic vitrectomy which revealed growth of *Cladosporium cladosporioides*, identified by polymerase chain reaction sequencing..

Although endogenous endophthalmitis is most commonly encountered in immunosuppressed individuals, intravenous drug abusers, it can also rarely manifest in immunocompetent persons as well. *Candida* and *Aspergillus* are the most common causative fungal endophthalmitis. Though *Cladosporium* is known to cause keratitis more frequently with a risk of progression to exogenous endophthalmitis, endogenous route is also a possibility. *Cladosporium* could cause delayed infection with an atypical clinical picture. Treatment with systemic and intravitreal voriconazole showed a good response.



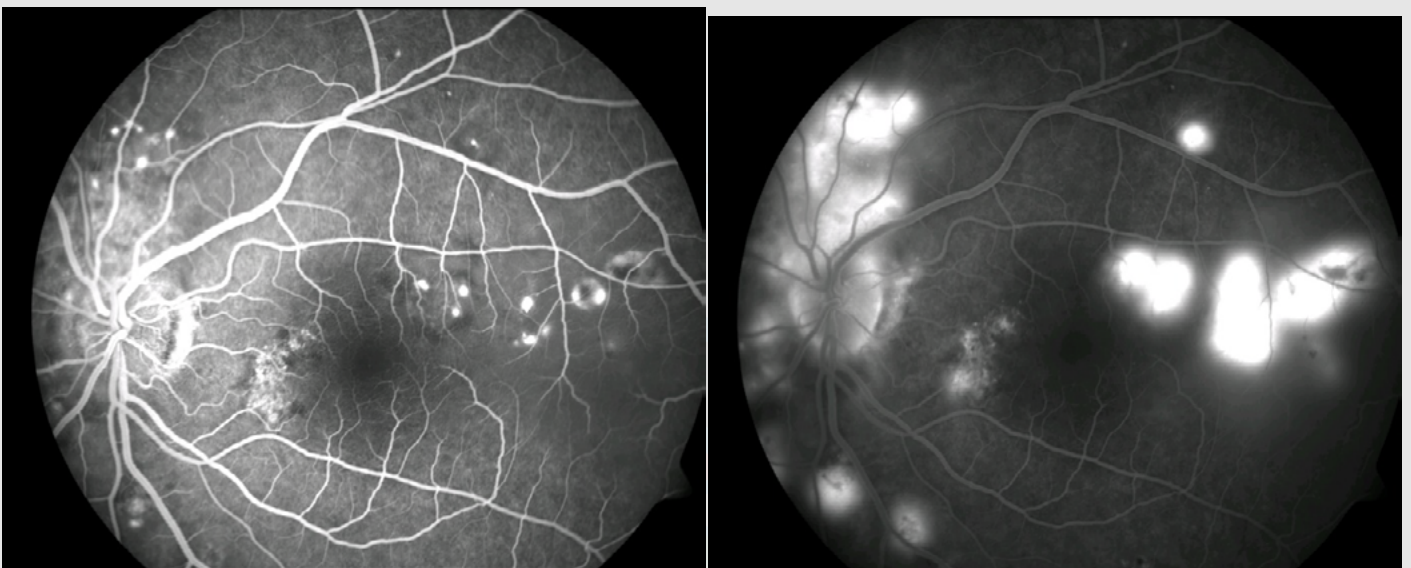
Case 4

PORN, a rapidly progressive necrotizing herpetic retinopathy, is the disease of the immuno compromised individuals. Multifocal lesions without granular borders in deep retinal layers causing the characteristic “crack mud” appearance, lesions in the peripheral retina with or without macular involvement with a centripetal distribution, rapid progression, absence of vascular inflammation and minimal or no intraocular inflammation, perivenular lucency helps clinch the diagnosis. Unlike acute retinal necrosis. (ARN), PORN does not respond well to systemic antivirals alone, an aggressive treatment with intravenous as well as intravitreal antivirals need to be employed along with anti-retroviral therapy. A timely, prophylactic laser barrage to any retinal break and the necrotic retina is found to be useful.



Case 5

CSCR is most commonly mistaken for the exudative retinal detachment seen in the acute phase of Vogt-Koyanagi-Harada (VKH) syndrome. Findings that facilitate the diagnosis of CSCR are absence of optic disc edema on fundus examination, no choroidal thickening on ocular ultrasonography, an absence of optic disc staining in late phases of fluorescein angiography with characteristic ink-blot or smoke stack pattern of leakage. The inner surface of retina may show a localized depression at the site of pigment epithelial detachment (PED). In CSCR with subretinal fibrin, an area of lucency may also be seen which denotes the site of leakage.



Case 6

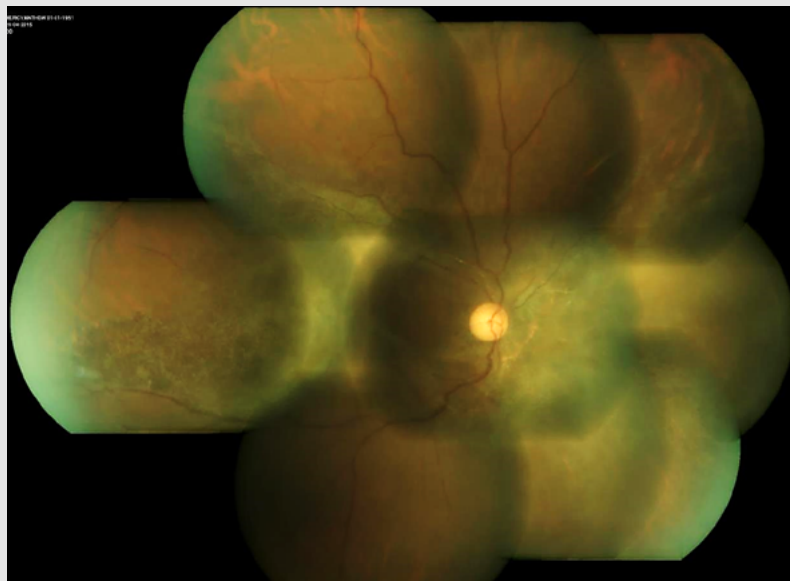
SSOCT is quite characteristic and shows multilobular serous retinal detachment and subretinal septas that divide the subretinal space into several compartments containing numerous hyper-reflective dots. These dots are thought to represent inflammatory products like fibrin. Final diagnosis is VKH.

Case 7

Diagnosis is diffuse unilateral subacute neuroretinitis (DUSN). The nematode migrates hematogenously to reside in the fundus. The nematode and its waste products are thought to induce damage through toxic, inflammatory, and autoimmune mechanisms. It is usually unilateral in affection. The retina, subretinal space, optic nerve, and choroid are most commonly affected. Fundus examination alone might not be sufficient to highlight the parasite tract, where fluorescein angiography demonstrates the exact involvement. The most common features seen in early and late DUSN are subretinal tracks, focal retinal pigment epithelium (RPE) changes, and small white subretinal spots (as shown in the figure). Due to the possibility of this disease having an immunological element, corticosteroids associated with both high-dose albendazole (400 mg/d) for 30 days is the recommended treatment.

Case 8

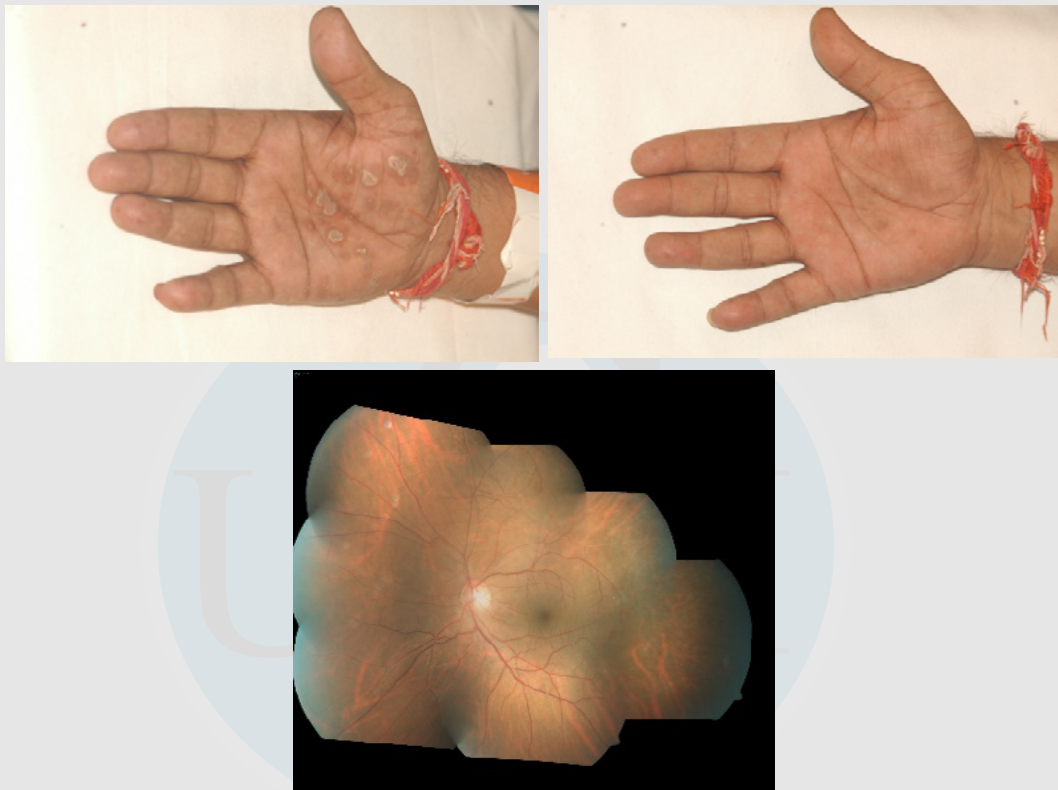
Diagnosis is diffuse retinitis due to toxoplasma. A history of multiple blood transfusions for pyrexia of unknown origin, 2 years back leading to identification of human immunodeficiency virus (HIV) positive status was present. Treatment with clindamycin, Bactrim DS, systemic corticosteroids alongwith HAART and intravitreal clindamycin led to a resolution of the retinal lesions. In patients with AIDS, the disease more often presents as diffuse necrotizing retinal lesions with a lack of intense vitreous inflammation mimicking viral retinitis. Other atypical presentations include neuro-retinitis, hemorrhagic vasculitis and serous retinal detachment. Hence, intravitreal therapy can be considered in such severe cases.



Case 9

Systemic examination revealed vesicular lesions in hands and the genital areas. (Figure a). He was found to be a MSM AIDS patient non-compliant to HAART. Following treatment with penicillin and corticosteroids, hand lesions (b) as well as retinal lesions (c) subsided. These superficial retinal precipitates are quite characteristic of syphilis and a co-existence of HIV positivity should be enquired.

Final diagnosis was syphilitic posterior uveitis.



Case 10

Fundus autofluorescence (FAF) imaging demonstrated gradually increasing hyperautofluorescence centrifugally from the fovea corresponding to the area of altered annular reflex, with the edge having maximum hyperautofluorescence leading to a diagnosis of AZOOR, supported by electroretinography and optical coherence tomography findings. Role of multimodal imaging in the diagnosis of AZOOR in an apparently normal looking fundus cannot be overlooked.



2020

Year of the Eye



On behalf of all the members of Uveitis Society we wish to congratulate

Prof. Emeritus Dr. Amod Gupta

for having been conferred upon the prestigious

**“Unsung hero award by
American Academy of Ophthalmology 2020”**

for his contribution in the field of Ophthalmology



Awards



Rhett Buckler Award ASRS Film Festival 2020



Dr. Navneet Mehrotra

DNB, FRF Vitreo Retina Consultant Retina Foundation
Ahmedabad



Note of thanks

With due perseverance and hard work of the editorial and scientific committee members, we have been able to publish this edition of the USI Newsletter for the readers.

I sincerely wish to convey my heartfelt special thanks to Dr. Vishali Gupta Dr. Kalpana Babu, Dr. Manisha Agarwal, Dr. Sudharshan S, Dr. J Biswas Dr. S R Rathinam, Dr. Padmamalini Mahendradas, Dr. Reema Bansal Dr. Parthopratin Dutta Majumder, Dr. Ankush Kawali, Dr. R Vedhanayaki Mrs. Veidhehi J and Design Team of Hallmark Events for sparing their precious time to co-edit the contents of this issue. Thanks to all the fraternity members who have contributed their manuscript.

The encouragement from all my friends and seniors is highly appreciated.

With high regards,

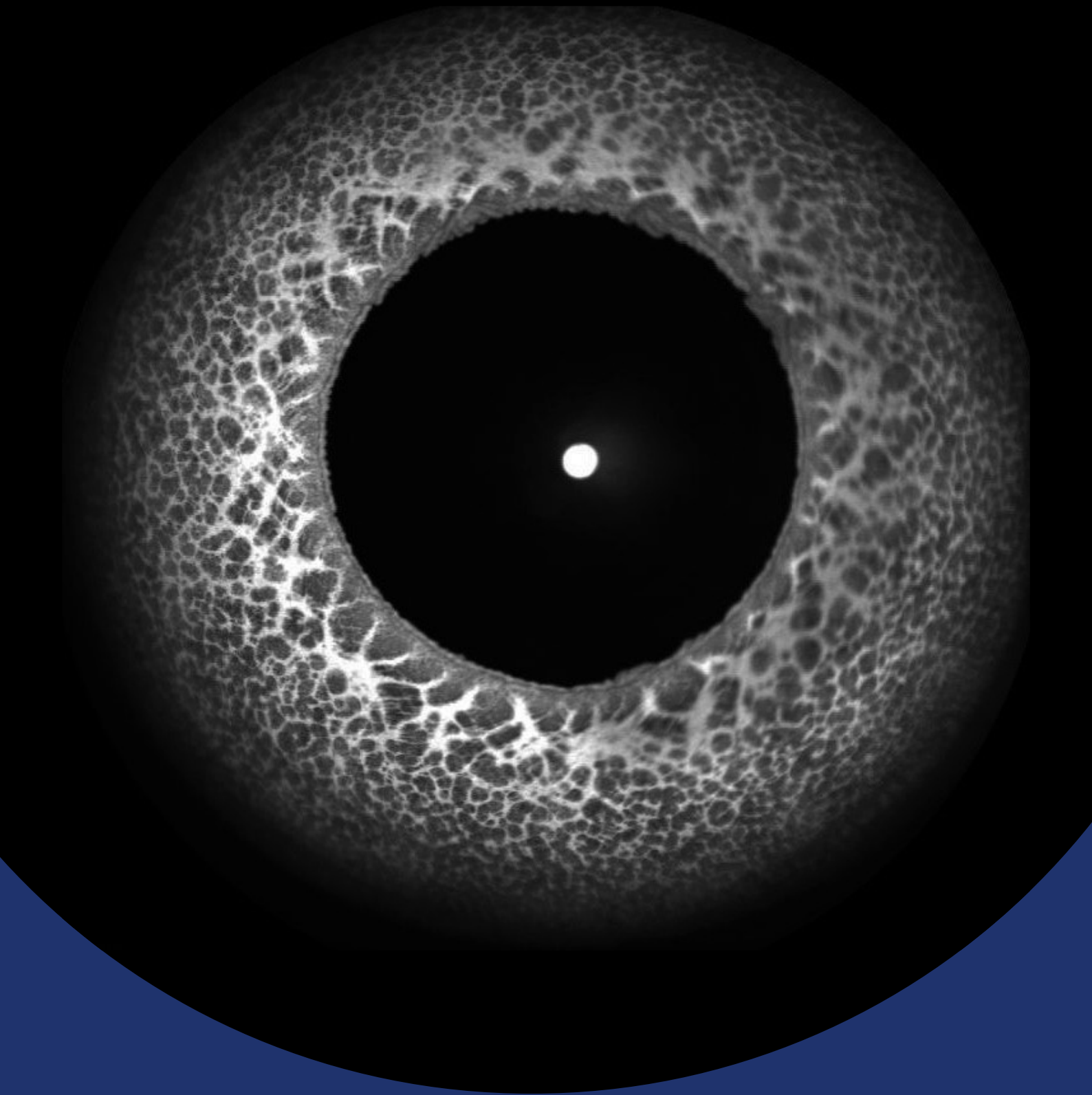
Dr. S Bala Murugan

Editor-in-chief

Mob: 9080518580

Email: drbalamuruganms@gmail.com

Disclaimer: *Facts and opinions in articles published in the Newsletter are solely the personal statements of respective authors. Authors are responsible for all contents in their article(s) including accuracy of the facts, statements, citing resources, and so on. Please excuse any possibility of human error by the authors, editors.*



Communication

Uveitis Society (India)

C/O Hallmark Events, Maruthi ' 688, 1st Floor, 6th Main
3rd Block, BEL layout, Vidyananyapura, Bangalore - 560097

Ph: 080 - 23646880 | Mob: 9591732274 | 9845671462

Email: uveitissociety@gmail.com

Designed by



www.indianuveitis.org