

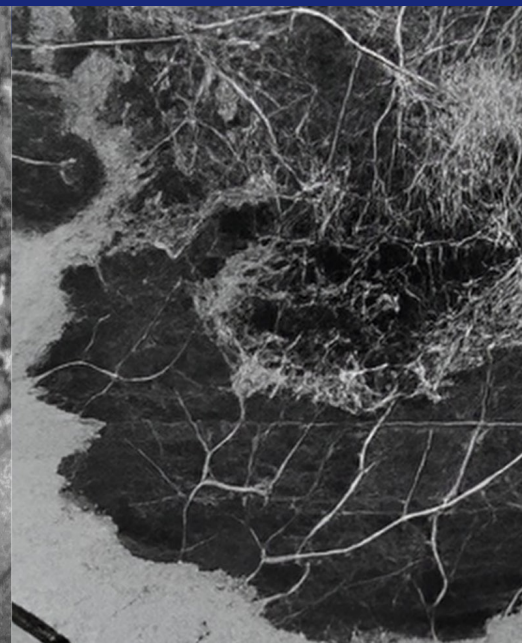
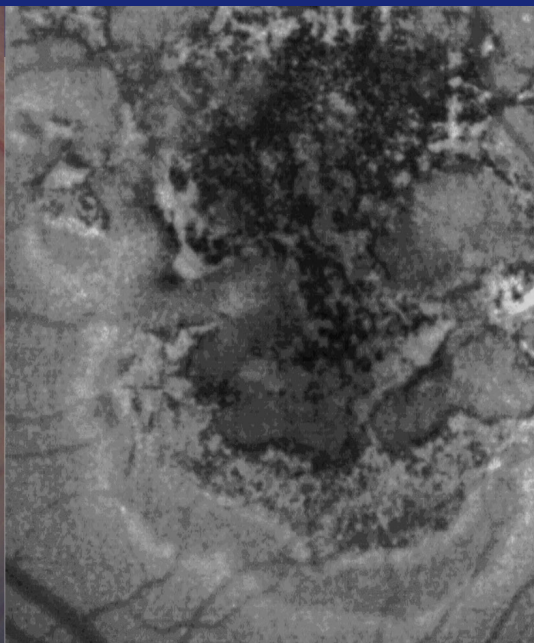
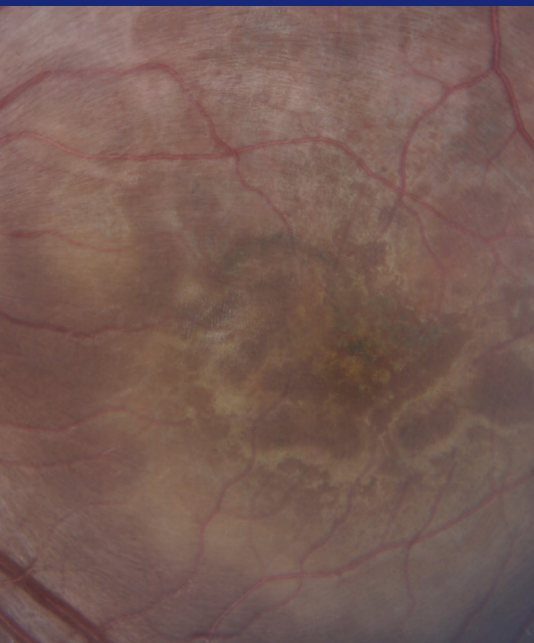


Uveitis Society (India)

NEWSLETTER

THE  
WHITE  
DOT  
SYNDROMES

EDITION-07 | VOLUME - 1 | June 2024





Partnering auto-immune disease management

# Folitrax<sup>®</sup>

Methotrexate Tablets & Injections

Immunosuppressants

**Ipca MMF**   
Mycophenolate mofetil 500 mg tablets

**Brings Remission, Transforms Lives**

**Ipca MMF-S**   
Mycophenolate Sodium 360 mg Tablets

**For GI sensitive patients**

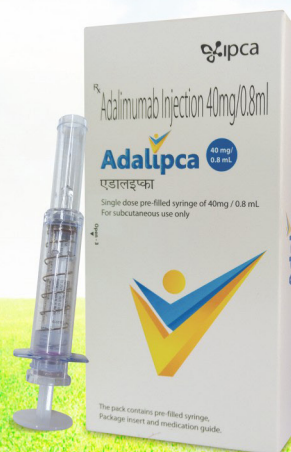**AZR**   
Azathioprine tablets

**For maintaining Remission**

In Uveitis

**Adalipca**   
Pre-filled syringe Adalimumab

**Reviving life**



Non-infectious intermediate Uveitis

Posterior Uveitis

Panuveitis

## President Uveitis Society (India)



**Dr. Kalpana Babu**, DO FMRF MRCOphth(Lon), MNAMS  
Head of the Department, Uveitis and Ocular Inflammation  
Prabha Eye Clinic and Research Centre & Vittala International Institute of  
Ophthalmology, Bengaluru  
*kalpanababumurthy@gmail.com*

Dear friends,

**I**n the silver jubilee year of the USI, it is with great pleasure we bring to you the 7th edition of the USI newsletter. This edition features white dot syndromes. These syndromes remain a mystery to us, and we are still in the process of unravelling the pathology with newer diagnostic modalities like imaging. Our new and dynamic editorial team led by Dr Abhilasha Baharani, have put a lot of effort in compiling interesting articles from renowned national and international experts in this newsletter.


We are extremely fortunate to have an article authored by Prof. Amod Gupta, on his journey leading to the pathbreaking research on tuberculosis associated serpiginous like choroiditis. I am sure the lessons learnt will be valuable for life.

Finally, I thank all the authors and the editorial team for their coordinated efforts in bringing this interesting issue on white dot syndromes.

Regards,

**Dr. Kalpana Babu**

## Secretary Uveitis Society (India)



**Dr. Sudharshan Sridharan, DO DNB**  
Senior Consultant, Department of Uveitis  
Sankara Nethralaya, Chennai  
[drdharshan@gmail.com](mailto:drdharshan@gmail.com)

Dear Friends

Greetings!

*T*his isn't just another edition of the USI newsletter, which is now available. This one will be in a brand-new, energising format under the new editorial team led by our own enthusiastic and hardworking Dr Abhilasha, the current editor. Her creative approach and inspirational push will make the current Newsletter on White dot syndromes one of your most prized collections. I'm sure you'll all love it, because I really did.

This is the first of many more Newsletters on different topics to follow. I promise that everyone will eagerly anticipate this team's upcoming newsletters.

Sincere gratitude to everyone who contributed to this edition, since their time and efforts have greatly enhanced its academic content.

On behalf of USI, appreciate the industry's support. Expect to continue to see more such support for academic endeavours in the future.

Regards,

**Dr. Sudharshan S**

## Office Bearers



**Dr. Kalpana Babu**  
President



**Dr. Padmamalini Mahendradas**  
Vice President



**Dr. Sudharshan S**  
Secretary



**Dr. Soumyava Basu**  
Joint Secretary



**Dr. Parthopratin Dutta Majumder**  
Treasurer

## Executive Committee Members



**Dr. Alay Banker**



**Dr. Amit Khosla**



**Dr. Aniruddha Agarwal**



**Dr. Mayur R Moreker**  
*Webinar Incharge*



**Dr. Mudit Tyagi**



**Dr. Samendra Kumar Karkhur**

## Scientific Committee



**Dr. Somasheila Murthy**  
Chairperson



**Dr. Reema Bansal**



**Dr. Navneet Mehrotra**



**Dr. Ankush Kawali**



**Dr. S Bala Murugan**

## Advisors



**Dr. Narsing A Rao**  
Patron-in-Chief



**Prof. Carl Herbort**



**Prof. Amod Gupta**



**Dr. Jyotirmay Biswas**



**Dr. S R Rathinam**



**Dr. Virender S Sangwan**



**Dr. Sudha K Ganesh**



**Dr. B Manohar Babu**



**Dr. Vishali Gupta**  
Immediate Past President

## Zonal Representatives - USI

**Dr. Minija C K**  
Zonal Head

**Dr. Vijay Pratap Singh Tomar**  
North Zone

**Dr. Dhaivat Shah**  
**Dr. Rashi Taori Sawal**  
Central Zone

**Dr. Rohit Ramesh Modi**  
**Dr. Samyak Mulkutkar**  
West Zone

**Dr. Himadri Choudhury**  
**Dr. Anindya Kishore Majumder**  
East Zone

**Dr. Reesha K R**  
**Dr. Abhilasha Baharani**  
South Zone

## Newsletter Advisors

**Dr. S. Bala Murugan**

**Dr. Ozlem Gurses Sahin**

**Dr. Radha Annamalai**

# Editor-in-Chief, Newsletter Uveitis Society (India)



**Dr. Abhilasha Baharani**, DNB, FRCS, FICO  
Senior Consultant, Neoretina Eyecare Institute, Hyderabad.  
[drabhilashabaharani@gmail.com](mailto:drabhilashabaharani@gmail.com)

“Education isn’t something you can finish”- Isaac Asimov

**T**he USI Newsletter has been an attempt to keep the learner inside all of us satiated. With this inspiration I bring out the first edition of the USI Newsletter as its Editor-in-Chief. I had embarked upon this journey with a lot of enthusiasm and to be honest, some self doubt. But the encouraging response I received from the stalwarts as well as all the members of this amazing Society kept me going.

The theme of the present issue is “White Dot Syndromes” (WDS), an umbrella term used to describe phenotypically similar intriguing diseases of the outer retina, retinal pigment epithelium (RPE) and choroid. Some of them, for instance, Serpiginous choroiditis (SC) were described more than 120 years ago while others like Acute zonal occult outer retinopathy (AZOOR) were first described as late as about 30 years ago and yet we classify all of them together and strive to learn their differences, especially in pathophysiology and exact site of inflammation. In the past decade and a half, with higher resolution imaging of the choroid, there has been a

paradigm shift in the understanding of these diseases, so much so that some of them like Acute posterior multifocal placoid pigment epitheliopathy (APMPPE) and Punctate inner choroidopathy (PIC) might even need a change of name! This issue of the Newsletter aims to take the readers on this amazing journey through the placoids and the outer retinopathies with the hope to demystify this motley group of disorders.

The issue opens with Padmashri Prof. Amod Gupta, who walks us through his inspiring journey about the discovery of TB-Serpiginous like Choroiditis (TB-SLC). This was my first direct interaction with Prof. Gupta and the one thing that’s most striking about him is his level of sincerity after achieving such greatness. I received his article a month before the “deadline”. For him excellence is a habit, something that will continue to inspire me. He’s still on the road less traveled. I also whole heartedly acknowledge his help at critical stages in the preparation of the Newsletter.

Next we dive into the sea of white dots. The readers will gain comprehensive knowledge on SC and SLC from the article by Dr. Padmamalini and co authors. The authors have painstakingly covered the topic in depth and detail and described all aspects of the condition. This article is not to be missed! The crisp and very specific article on APMPPE and relentless placoid (RPC) by Dr. Anita Agarwal and co authors, clearly differentiates the 2 conditions. It will surely be your practical guide in the clinic. Dr. Francesco Pichi detangles the enigma of multiple evanescent white dot syndrome (MEWDS). His article includes interesting literature on whether or not MEWDS is a primary choriocapillaritis. Dr. Anup attempts to cover the spectrum of punctate inner choroidopathy (PIC) and multifocal choroiditis (MFC). The zones of AZOOR deftly described by Dr. Rajiv Raman and co authors shed light on this diagnosis of exclusion. I'm grateful to all the authors for accepting my request and coming up with brilliant articles with a lot of learning for all. I would especially like to thank our international contributors Dr. Anita Agarwal and Dr. Francesco Pichi.

We know that a lot of our understanding about the WDS has come from recent advances in posterior segment imaging. A review of literature over the past decade by Dr. Vidya Mooss encapsulates the latest in the field. And finally, I give the last word to Ani, who simplifies it with his imaging algorithm for this group of diseases. I'm sorry Aniruddha, I won't credit you as an international faculty; you're an integral part of the USI! But I wholeheartedly thank you for your prompt response to all my requests during the preparation.

We have brain teasers by our young guns. Dr. Dhavit Shah has presented puzzles in his trademark style and Dr. Aditya, our award winning champion of the last USICON brings us the crossword.

The Newsletter would be incomplete without the top 3 cases and top 3 images. This concept has been introduced to encourage participation from all the valuable members that constitute our Society. It makes the Newsletter wholesome and I'm deeply thankful to all the contestants for their enthusiastic involvement. Words may fall short in thanking our senior judges for their time and efforts.

To celebrate the achievements of members, a section on awards and orations has been added. CMEs conducted under the aegis of USI highlight the passion for sharing knowledge amongst peers. A new section on Uveitis fellowship opportunities will serve as a useful guide for our young ophthalmologists.

I would like to express my sincere gratitude to the Advisory Committee, Dr. S Bala Murugan, Dr. Radha Annamalai and Dr. Ozlem Gurses Sahin. Last but surely not the least I wouldn't be here without the support of the President -Dr. Kalpana Babu Secretary - Dr. Sudharshan Sridharan Vice President- Dr. Padmamalini Mahendradas, Joint Secretary - Dr. Soumyava Basu and Treasurer-Dr.ParthopratinDuttaMajumdar.

I sincerely appreciate the industry sponsors, Ipca and Sun pharma, for supporting this academic endeavour.

There might have been hits and misses but I hope everyone will enjoy reading this issue on WDS as much as I enjoyed preparing it. A big thank you to all who made this possible.

Sincerely,  
**Abhilasha**

<b>The Road Less Traveled: Legend Speaks</b> <i>Padmashri Prof. Amod Gupta</i>	01
<b>Image Contest Winner: The Trizonal Tapestry of AZOOR</b> <i>Dr. Dhaivat Shah</i>	12
<b>Serpiginous and Serpiginous like Choroiditis: What We Must Know</b> <i>Dr. Sai Bhakti, Dr. Ankush Kawali, Dr. Padmamalini Mahendradas.</i>	13
<b>Case Contest Winner: Boundless Tale of White Dot Syndrome in a Child</b> <i>Dr. Lekha T</i>	31
<b>APMPPE and Relentless Placoid: What's in a Name</b> <i>Dr. Georgia Kamboj, Dr. Anita Agarwal</i>	37
<b>Image Contest Winner: Multimodal Imaging in Acute Zonal Occult Outer Retinopathy (AZOOR)</b> <i>Dr. Shweta Parakh</i>	43
<b>The Enigma of MEWDS</b> <i>Dr. Francesco Pichi</i>	44
<b>Case Contest Winner: A Case of Retinal Pigment Epitheliitis Complicated by a CNVM and is it Primarily a Disease of the Choriocapillaris?</b> <i>Dr. Shahana Mazumdar</i>	51
<b>The Spectrum of PIC and MFC</b> <i>Dr. Anup Kelgaonkar</i>	55
<b>Image Contest Winner: Navigating the Nexus: Exploring AZOOR and MEWDS in Tandem</b> <i>Dr. Radhika Sriram</i>	61
<b>The Three Zones of AZOOR</b> <i>Dr. Raaja Ganesh, Dr. Rajiv Raman</i>	62
<b>Case Contest Winner: Connecting the White Dots to Reveal What Lies Beneath!</b> <i>Dr. Nidhi Dubey</i>	68
<b>Out of the Box: Puzzle Corner</b> <i>Dr. Dhaivat Shah</i>	71
<b>The Decade Gone By: Recent Literature Review</b> <i>Dr. Vidya Mooss</i>	72
<b>Joining the Dots: Crossword</b> <i>Dr. Aditya Patil</i>	82
<b>The Last Word: Clinical Cues and Imaging Algorithm</b> <i>Dr. Aniruddha Agarwal</i>	83
<b>You Make Us Proud: Awards and Certifications</b>	88
<b>Get on Board: Uveitis Fellowship Opportunities</b>	90
<b>CMEs and Webinars under the Aegis of USI</b>	91
<b>Get your Answers Here: Puzzle and Crossword</b>	92

# The Road Less Traveled: Legend Speaks

## Story of Discovering Tubercular Serpiginous-like Choroiditis



### **Padmashri Prof. Amod Gupta, MS**

Emeritus Professor, Advanced Eye Centre, PGI, Chandigarh  
[dramodgupta@gmail.com](mailto:dramodgupta@gmail.com)

**M**y chief Prof I S Jain was obsessed with the documentation of various eye diseases in any way possible. On my selection as an Assistant Professor in 1981, he gifted a Zeiss fundus camera. This is one of the many legacies I inherited from him. Handling the fundus camera initially was very frustrating, color rolls were very expensive, and I failed to even obtain focused pictures of the retina. It took me a year to learn that I had to first focus the cross-hair sharply in the camera's eyepiece to obtain focused images (it compensates for the photographer's accommodation). The organic path of learning that I followed during my entire career spanning 50 years was very slow and fraught with uncertainties. However, I can say with a degree of great pride that our fundus fluorescein angiograms (FFA) done in the early eighties were the best in India. I was among the very rare persons in Indian Ophthalmology who showed follow-ups of patients documented on imaging. Of course, I had to learn on my own the interpretation of angiograms. There were no books to refer to and each day I had to

climb up six flights of stairs to our library to look for the papers on FFA, most of which incidentally had been described by Dr. JDM Gass in the late 1960s to the 1970s.

### **The camera does not lie**

Performing 20-30 FFAs a day was opening up a whole new world for me. I was passionate about documenting the retinal pathologies day in and day out. The fundus of the same patients were imaged on the subsequent visits as well. It was a revelation to me how the camera would tell if the patient was responding to the treatment or was getting worse. I would not be exaggerating if I say that the real credit for the discovery of Tubercular Serpiginous-like Choroiditis (TB-SLC) goes to my Zeiss Fundus camera. Even today, I hold the view that the fundus camera (and of course all other imaging tools) is the best teacher. Because the camera does not lie! Earlier in 1968, Dr. JDM Gass had described Acute Posterior Multifocal Placoid Pigment Epitheliopathy (APMPPE) in three young women.<sup>1</sup>

These were exciting times in Ophthalmology with fundus cameras and FFA becoming available across the world. In a true sense, FFA was the first disruptive technology that led to a surfeit of reports from across the world on a variety of inflammatory and non-inflammatory disorders of the posterior segment.

### **Documentation is the key**

Since the time I began using the fundus camera for all posterior segment pathologies, I was intrigued by patients, who were young girls in their twenties, some of them pregnant, presenting with unilateral or bilateral multifocal serous retinal detachments, which responded well to corticosteroids, but often resolved even if you did not treat them. In early frames of FFA were seen multifocal areas of delayed filling of the choroid, were followed by punctate hyperfluorescence during dye transit and ultimately led to very dramatic pooling of the fluorescein dye under the neurosensory retina. I erroneously called these patients 'limited Harada' due to an information vacuum. I was unaware of the various stages of Vogt Koyanagi Harada (VKH) disease. Now, I know that I had been seeing the early exudative stage of the acute presentation of VKH disease. I was unaware that the American Uveitis Society had already specified the diagnostic criteria for VKH disease in 1978. Interestingly we had also been documenting the cases of so-called APMPPE mostly in young men, which appeared as multifocal areas of creamy placoid lesions in the posterior pole that remained hypo-fluorescent during the dye transit but became hyperfluorescent in late frames. We regularly followed them with imaging.

### **Hits and Misses- Pioneering work by Dr. Anita Agarwal**

Dr. Anita Agarwal joined us in July of 1987 as a first-year resident. As I was fascinated by the diseases affecting the RPE and inner choroid and was trying to figure out the

phenotypes and possible etiologies, I asked her to do a thesis on the subject. The famed 'Stereoscopic Atlas of Macular Diseases' by Dr. Gass was not available in our library and the 3<sup>rd</sup> edition had just been released in the United States. She managed to get a 'Xerox copy' of the two volumes of this atlas available in the library of her alma mater, the Kasturba Medical College, Mangalore facilitating her to initiate the work. She spent five years with me working on the subject.

Anita studied 30 patients for her thesis (1987-1989), 12 (10 bilateral; 7M, 5F) of whom had pictures consistent with APMPPE lesions that had progressed during follow-up and mimicked Serpiginous Choroiditis (SC). The rest of the patients in her series had Vogt-Koyanagi-Harada (VKH) or Sympathetic Ophthalmia. The APMPPE patients were followed up for 6 months to 60 months (Median 9 months). Four patients had associated vitreous inflammation. No lab investigation was positive in any of the patients. The sera of the patients were tested for autoantibodies against bovine soluble retinal antigen which were significantly higher than the normal controls. Some of them were also found positive for the blast transformation of the B and T cells indicating a cell-mediated response as well. All patients were treated with high-dose corticosteroids. Seven patients showed progression of existing lesions while on corticosteroids and one patient who was followed for 5 years showed development of fresh lesions in the initially uninvolved eye.

In hindsight, I believe this data was enough to suggest that there was a combined infectious and autoimmune pathomechanism at play in APMPPE that showed progression. Most unfortunately though, we failed to submit this work for a possible publication.

Having cleared her USMLE, Anita went to the US in May 1992 to pursue her ophthalmology residency there and got an opportunity to do a fellowship with Dr. Gass. Later she became a faculty colleague with him and went on to write the 5<sup>th</sup> edition of this famous book, rightfully inheriting the legacy of the legendary Dr. JDM Gass.

### **Presenting unique observations on the touchstone of peer group**

I presented the VKH cases and the ones I thought were a series of APMPPE cases (documented by Anita ) in 1988 at the 46<sup>th</sup> Annual Conference of AIOS in Mumbai. I titled my paper, 'APMPPE to VKH-spectrum of a disease'. The session was chaired by Prof. Narsing Rao and my chief Prof. Jain. My work was subsequently also accepted as a free paper both at the ICO meeting in Singapore in 1990 and at the Annual Conference of the AAO in Anaheim in 1991. As I could not afford to travel to the USA, I had to convince the AAO to instead allow Dr. Vinod Lakhanpal to present the paper. He presented on my behalf the unique spectrum of limited Harada disease and APMPPE seen by us in Chandigarh.

### **The search continues- Our initial reports went unnoticed, but the dramatic images could not be ignored.**

As Dr. Anita was leaving, Dr. Vishali Gupta joined me in April 1992 first as a junior research fellow and later as a junior resident, and we had the opportunity to accumulate and collate our data further over the next 10 years. I shared data on Serpiginous Choroiditis in a uveitis symposium in Bangalore on 26<sup>th</sup> July 1998. Dr. Vishali Gupta presented the updated data as a free paper during the 57<sup>th</sup> Annual Conference of All India Ophthalmological Society at Cochin, in January 1999, and also the 59<sup>th</sup> Annual meeting of AIOS, Calcutta, in January 2001. Unfortunately, despite highly dramatic images of the progression of the so-called APMPPE lesions, our observations went unnoticed.

An international symposium in Chennai in February 2001 (held in conjunction with the first-ever meeting of the IUSG in India) provided me the opportunity to make a presentation that attracted the attention of Dr. Emmett Cunningham Jr. (USA) and Dr. Carl P Herbort (Lausanne) both of whom believed that not only we had the largest series, but it also exceeded the entire reported experience of Serpiginous Choroiditis from the whole world. They encouraged us to publish our data. Incidentally, during the IUSG meeting, I was elected as a member of this exclusive club based on my presentation on PCR+ tubercular retinal vasculitis.<sup>2</sup> I had been exploring Mycobacterium tuberculosis as a possible etiology of uveitis during the previous decade and our papers had been received in India with mixed responses; both skepticism and attention.

### **Clinical characteristics of Serpiginous Choroidopathy<sup>3</sup>:**

We published our retrospective series of 86 patients of whom 20 patients had initially presented as multifocal pigment epitheliopathy (MPE) lesions that over a period of follow-up had progressed to resemble Serpiginous Choroidopathy. Of the 126 patients seen by us from 1989 to 1997, we excluded 40 as inactive disease. The remaining 86 patients were predominantly males and young (less than 30 years of age). The largest group of 62 patients (15% bilateral) showed lesions of serpiginous choroidopathy, and 20 patients (60% bilateral) presented with MPE lesions that progressed to Serpiginous Choroidopathy (SC). Four patients had one eye each showing MPE lesions and the contralateral eye the SC lesions. Nearly half of them were noted to have vitritis. All patients were treated on oral corticosteroids. During follow-up from 2 to 8 years, more than 90% of the 107 affected eyes continued to worsen. We concluded, " Serpiginous Choroidopathy in our population was seen in young patients

and had three distinct presentations that seemed to affect the choriocapillaris primarily".<sup>3</sup> Our patients appeared to have a variation of Serpiginous Choroidopathy, typical of the Asian-Indian population, that had some important differences from that reported in Caucasians"<sup>3</sup>. In hindsight, it is apparent that we had seen patients in varying stages of disease evolution, and erroneously categorized them into three groups, of what we now know as Serpiginous-like Choroiditis (SLC).

### **Presumed Tubercular Serpiginous-like Choroiditis: Clinical Presentations and Management**<sup>4</sup>

From 1997 to 2000, we documented seven young patients (5M, 2W; 17-32 years) who had presented with MPE or SLC lesions with vitreous inflammation. Four showed progression while on oral corticosteroids, others had both healed and active lesions. The active lesions showed a centrifugal spread, the central core healing with fine pigmentation, and the progressive edge showed a gray-white opacification of the retina. On FFA, the healed areas showed transmission hyperfluorescence. The active edges of the lesions were hypofluorescent during the dye transit which showed hyperfluorescent staining in late frames. In all these patients, the Mantoux skin test was highly positive varying from 20 mm to 32 mm including one who had a necrotic reaction. This prompted us to investigate these patients more thoroughly for tuberculosis (TB). All seven had evidence of pulmonary TB on chest radiography, with infiltrative lesions in four and hilar lymphadenopathy in three. Lymph node biopsy was positive for TB in two of them. Polymerase chain reaction for MTB was positive from the aqueous tap in the other five patients. We treated all seven with anti-tubercular therapy and oral corticosteroids. All patients were followed ranging from 6 months to 6 years and showed resolution of the lesions. None of them showed any recurrence.

The paper was published in Ophthalmology in 2003<sup>4</sup>. History was created with the birth of a new disease entity- the Tubercular Serpiginous-like Choroiditis (TB-SLC). This was a time of huge excitement and over the subsequent 20 years, it spawned a large number of papers from both the TB-endemic and TB-non-endemic regions of the world. It remains one of the most cited papers in its category (Scopus cites 217).

### **Characterization of TB-SLC as a multifocal choroiditis**<sup>5</sup>

Dr. Reema Bansal carried the work forward. In 2012, we reported 105 patients (141 eyes), all positive for immunological tests for MTB infection, "Mean age was 33±9.3 years (range, 12–54 years; 75 male and 30 female patients). Serpiginous-like choroiditis was bilateral (at least 1 eye active) in 66 patients (62.9%). Of 171 affected eyes, 141 (82.45%) had active lesions at presentation. Of 141 eyes, 115 (81.56%) showed vitreous inflammation. Lesions were multifocal in 133 eyes (94.3%), were non-contiguous to the optic disc in 122 eyes (86.52%) and involved the macula in 125 eyes (88.65%)."<sup>5</sup> Following a course of anti-TB therapy and corticosteroids only 9 of the 93 patients showed a recurrence of choroiditis at a median interval of 21 months. At the same time, 9 of the 12 patients treated on corticosteroids alone showed recurrences over 26.5 months (median) of follow-up. This paper too was extensively cited (Scopus cites 127). The serpiginous choroiditis (rechristened as Classic serpiginous choroiditis to differentiate it from TB-SLC) is an organ-specific autoimmune bilateral disorder seen in middle-aged people without any signs of vitreous inflammation and begins in the juxta papillary area. The lesions heal with choroidal atrophy without much pigmentation. The TB-SLC is multifocal, and lesions heal with atrophy and variable pigmentation.<sup>6</sup> Noncontiguity with the optic disc has also been emphasized subsequently by other authors to differentiate infectious SLC from the classic SC.<sup>7</sup>

### **Further studies of tubercular serpiginous-like choroiditis**

In 2008, we obtained a short wavelength filter for our fundus camera to study the phenomenon of autofluorescence. We found that fundus autofluorescence was the most sensitive and effective tool to monitor the activity in the SLC lesions.<sup>8</sup> This has been endorsed by several subsequent studies.<sup>9</sup>

**Challenges remain:** We had always been concerned about some lesions flaring up with the initiation of anti-TB therapy, a phenomenon not seen when patients were treated with corticosteroids alone. Using the conventional 45° fundus images, to monitor the lesions, Vishali Gupta and Reema Bansal showed that 14% of the patients who had completed at least 18 months of follow-up showed paradoxical worsening.<sup>10</sup> Subsequently, using ultra-widefield imaging, nearly 40% of eyes were seen to show paradoxical worsening.<sup>11</sup> To date, it remains the major challenge in managing TB-SLC patients. To compound the challenge further, patients with TB-SLC may have negative immunological tests for tuberculosis but behave exactly like the TB immunological tests positive patients.<sup>12</sup> Biological therapy for patients with uveitis who present with SC phenotype even when the initial TB immunoreactivity tests are negative may have fatal outcomes due to disseminated tuberculosis in such patients.<sup>13</sup>

### **Demonstrating MTB genome in the vitreous fluid of SLC eyes**

Having established the clinical phenotypes of TB-SLC<sup>3,5</sup>, we were using only immunological or radiological tests to establish TB as an etiology of SLC. Subsequently, however, commercial PCR kits became available, and we got an opportunity to look for the presence of MTB in the vitreous fluid obtained during vitreous surgery in some

of the SLC patients. We successfully used 3 different molecular techniques including Gene Xpert MTB/RIF assay and Genotype MTBDRplus to detect the MTB genome in the vitreous fluid of eyes with MSC. For the first time, we detected rifampicin resistant MTB genome in a patient with TB-SLC who was successfully treated with multidrug-resistant anti-tuberculosis therapy given for 18 months.<sup>14</sup>

### **OCT angiography throws light on patho mechanism:**

Subsequently, as OCT angiography became available, my colleagues demonstrated a flow deficit in the choriocapillaris layer in eyes with SLC corresponding to the dark spots seen on ICG.<sup>15</sup> The flow deficits were seen to correlate with dark spots seen on ICG angiography.<sup>16</sup> The dark spots were found to decrease significantly as the lesions healed. A significant visual improvement was seen with a reduction in the area of flow deficit after treatment.<sup>17</sup> This flow deficit is likely due to reversible choroidal flow reduction seen in placoid chorioretinitis.<sup>18</sup> OCT angiography has now become a standard of care in evaluation of patients with SLC.<sup>19</sup>

### **SLC as a marker of TB in non-endemic regions**

We found that SLC was highly suggestive of tubercular etiology.<sup>20</sup> Nicholas Jones recommended that every patient with SLC should undergo testing for previous exposure to tuberculosis.<sup>21-23</sup>

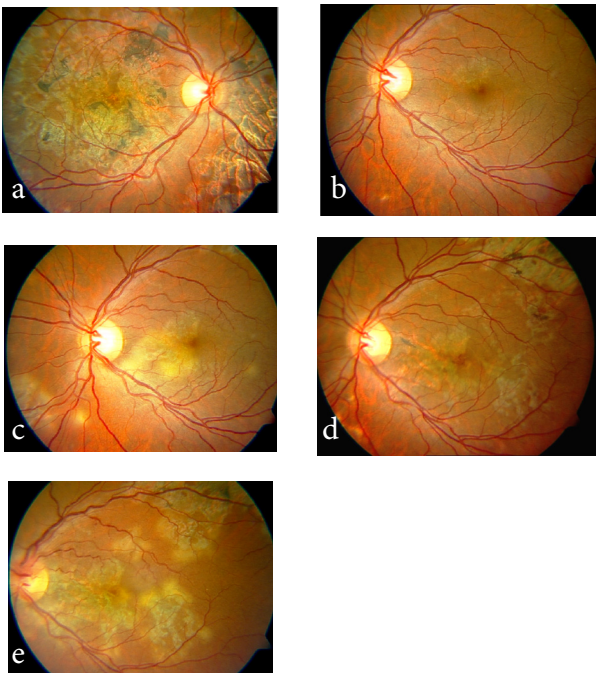
### **Complications of TB-SLC**

Eyes with TB-SLC may get complicated by a choroidal neovascular membrane. Moreover, these are difficult to differentiate from inflammatory reactivation. OCTA helps differentiate the two.<sup>24-26</sup>

## Postscript-1: Reinterpreting the APMPE paper by Dr. JDM Gass

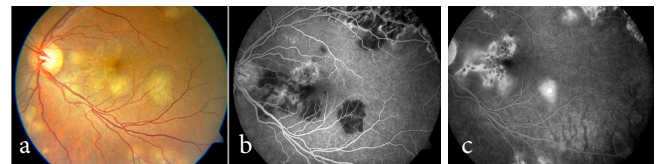
In 1968, Dr. Gass<sup>1</sup> described three young female patients, who showed bilateral multifocal flat placoid lesions that healed rapidly with permanent alteration of the RPE. There was a continued significant improvement in visual acuity even after the apparent healing of the lesions. On review of the cases presented by him significant facts that emerge are:

**Dr. Gass' Case #1 of APMPE.** The Tuberculin skin test was positive. INH trial was given but she was intolerant and stopped. "Some of the lesions in the macular area appeared to be clearing centrally where fine pigment mottling was apparent." "Clearing of each lesion began centrally and spread peripherally." "Only a few of the lesions showed slight enlargement." However, if we compare Figures 1 and 3 of Gass' paper, lesions are seen to have expanded on healing over a period of nearly 15 weeks. Likewise, comparing Figures 2 and 4 of Gass' paper some of the lesions have expanded over a period of 11 weeks. (Figures from Dr. Gass are not shown here. Readers will need to refer to the original Gass paper.<sup>1</sup>)



*Gupta's Figure 1: A 36-year-old man presented with extensive scarring of the right eye (a) and a healed choroiditis scar just above the fovea in the left eye (b). Within eight weeks of presentation, he had blurring of vision in the left eye and showed plaque-like multifocal lesions in the left eye (c). The lesions showed a central healing and centrifugal spread at the margins (d). At ten months following anti-TB treatment with oral corticosteroids, the lesions healed and did not recur (e). Reproduced with permission of the publishers from Gupta, A., Bansal, R., Sharma, A., Kapil, A. (2023). Retinal and Choroidal Infections and Inflammation. In: Ophthalmic Signs in Practice of Medicine. Springer, Singapore. [https://doi.org/10.1007/978-981-99-7923-3\\_10](https://doi.org/10.1007/978-981-99-7923-3_10).*

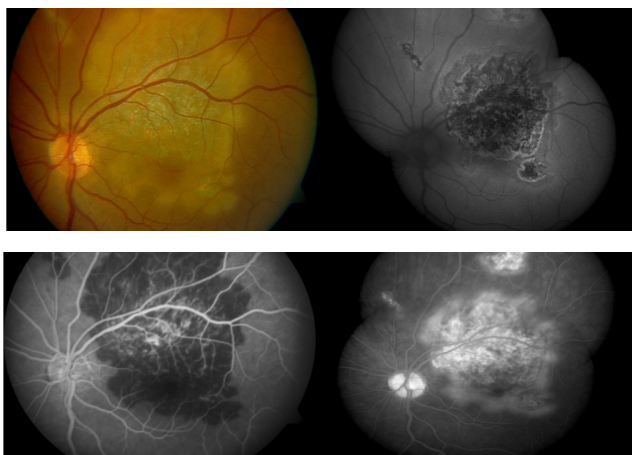
**Dr Gass' case # 2 of APMPE,** Dr. Gass says, "Her past history was unremarkable, and the only pertinent family history was that her father had pulmonary tuberculosis." In this case, Dr. Gass pointed out in Gass' Figure 5 that the lesions healed centrally and showed transmission hyperfluorescence on FFA. If we compare Gass' figures 5 and 7, the lesions are seen to have healed over 9 days with expansion of the lesions. (Dr. Gass figures are not shown here. Readers will need to refer to the original Gass paper.<sup>1</sup>)



*Gupta's Figure 2: Fundus fluorescein angiography (FFA) characteristics of TB-SLC. The left eye of the same patient as seen in Figure 1 shows active choroiditis lesions (a). The lesions were hypofluorescent on FFA in the dye transit. Note speckled transmission hyperfluorescence in healed lesions (b). The hypofluorescent areas become hyperfluorescent in late frames (c). Note the staining of the active edges of the lesions. Reproduced with permission of the publishers from Gupta, A., Bansal, R., Sharma, A., Kapil, A. (2023). Retinal and Choroidal Infections and Inflammation. In: Ophthalmic Signs in Practice of Medicine. Springer, Singapore. [https://doi.org/10.1007/978-981-99-7923-3\\_10](https://doi.org/10.1007/978-981-99-7923-3_10).*

**Case # 3** was not seen personally by Dr. Gass and the pictures of the healed pathology were provided by someone else. The lesions had already healed in geographic distribution with depigmentation and hyperpigmentation. No inference can

be drawn from these pictures about the healing pattern of the lesions. Interestingly, he noted that the patient's tuberculin test was positive, and she was treated with oral prednisolone and INH. Dr. Gass mused, "The significance of a positive tuberculin skin test in two patients and the family history of tuberculosis in the third patient is not known".



*Gupta's Figure 3: Left eye fundus photograph (a) and fundus autofluorescence (b) of a 45-year-old female with a large placoid lesion in the macula and multifocal active lesions of serpiginous-like choroiditis. The active margins of the lesion are hypofluorescent in early (c) and hyperfluorescent in late phases (d). The center of the lesion shows transmission hyperfluorescence, both in the early (c) and late phases (d). Reproduced with the permission of the publishers from Gupta, A., Bansal, R., Sharma, A., Kapil, A. (2023). Retinal and Choroidal Infections and Inflammation. In: Ophthalmic Signs in Practice of Medicine. Springer, Singapore. [https://doi.org/10.1007/978-981-99-7923-3\\_10](https://doi.org/10.1007/978-981-99-7923-3_10)*

The facts that emerge from the reinterpretation of the images from this paper are (a) the placoid lesions healed centrally, while the margins of the lesions were still active and (b) during its course, the lesion showed central transmission defects and staining of the active margins, (c) most of the lesions healed with the expansion of the scars over the limited follow-up time that these patients were seen, and (d) he wondered about the association with TB. In 2001, I asked Dr. Gass a question if he ever followed his own three patients of APMPE, and he said most unfortunately, he had not done so.

### It is a revelation!

The clinical features described by him in APMPE are also the features of TB-SLC, except that when you follow TB-SLC lesions they show progression, the confluence of multifocal lesions, and recurrences. The question that arises from a reinterpretation of images from his classic paper is - Was he describing TB-SLC lesions that he fortuitously named APMPE?

### Postscript-2: Reinventing the invented

I am grateful to Prof. Narsing Rao who brought to my notice in 2015 that Dr. Jonathan Hutchinson more than 100 years ago had not only described the clinical features but also saw an association with scrofulous (tuberculosis) lymphadenitis and coined the term 'serpiginous choroiditis'. Most unfortunately, Hutchinson published his observations in a journal, Archives of Surgery, which he edited, and the journal stopped publishing after his death. Jonathan Hutchinson was the most comprehensive English physician, Ophthalmologist, Dermatologist, and Pathologist. He has innumerable diseases named after him, the least of which is Hutchinson's teeth. While he looked for syphilis everywhere, he described two young women who suffered from "Serpiginous choroiditis in scrofulous subjects - Choroidal lupus".<sup>27</sup> This perhaps is the most forgotten disease, not named after him, which we were destined to reinvent.

The journey of discovering TB-SLC has been one of perseverance and discovery, highlighting the importance of keen observation documentation, and collaboration in advancing our understanding of ocular diseases.

## References:

1. Gass JD. Acute posterior multifocal placoid pigment epitheliopathy. *Arch Ophthalmol.* 1968 Aug;80(2):177-85. doi: 10.1001/archophth.1968.00980050179005. PMID: 5661882.
2. Gupta A, Gupta V, Arora S, Dogra MR, Bambery P. PCR-positive tubercular retinal vasculitis: clinical characteristics and management. *Retina.* 2001;21(5):435-44. doi: 10.1097/00006982-200110000-00004. PMID: 11642371.
3. Gupta V, Agarwal A, Gupta A, Bambery P, Narang S. Clinical characteristics of serpiginous choroidopathy in North India. *Am J Ophthalmol.* 2002 Jul;134(1):47-56. doi: 10.1016/s0002-9394(02)01501-5. PMID: 12095807.
4. Gupta V, Gupta A, Arora S, Bambery P, Dogra MR, Agarwal A. Presumed tubercular serpiginouslike choroiditis: clinical presentations and management. *Ophthalmology.* 2003 Sep;110(9):1744-9. doi: 10.1016/S0161-6420(03)00619-5. PMID: 13129872.
5. Bansal R, Gupta A, Gupta V, Dogra MR, Sharma A, Bambery P. Tubercular serpiginous-like choroiditis presenting as multifocal serpiginoid choroiditis. *Ophthalmology.* 2012 Nov;119(11):2334-42. doi: 10.1016/j.ophtha.2012.05.034. Epub 2012 Aug 11. PMID: 22892153.
6. Nazari Khanamiri H, Rao NA. Serpiginous choroiditis and infectious multifocal serpiginoid choroiditis. *Surv Ophthalmol.* 2013 May-Jun;58(3):203-32. doi: 10.1016/j.survophthal.2012.08.008. Epub 2013 Mar 27. PMID: 23541041; PMCID: PMC3631461.
7. Carreño E, Portero A, Herreras JM, Calonge M, Foster CS. Distinctive clinical features of idiopathic versus infectious serpiginous choroidopathy. *Ocul Immunol Inflamm.* 2012 Dec;20(6):448-52. doi: 10.3109/09273948.2012.723236. Epub 2012 Nov 19. PMID: 23163717.
8. Gupta A, Bansal R, Gupta V, Sharma A. Fundus autofluorescence in serpiginouslike choroiditis. *Retina.* 2012 Apr;32(4):814-25. doi: 10.1097/IAE.0b013e3182278c41. PMID: 22080913.
9. Carreño E, Portero A, Herreras JM, López MI. Assesment of fundus autofluorescence in serpiginous and serpiginous-like choroidopathy. *Eye (Lond).* 2012 Sep;26(9):1232-6. doi: 10.1038/eye.2012.121. Epub 2012 Jun 29. PMID: 22744387; PMCID: PMC3443827.
10. Gupta V, Bansal R, Gupta A. Continuous progression of tubercular serpiginous-like choroiditis after initiating antituberculosis treatment. *Am J Ophthalmol.* 2011 Nov;152(5):857-63.e2. doi: 10.1016/j.ajo.2011.05.004. Epub 2011 Jul 26. PMID: 21794847.
11. Aggarwal K, Agarwal A, Deokar A, Singh R, Bansal R, Sharma A, Sharma K, Dogra MR, Gupta V. Ultra-Wide Field Imaging in Paradoxical Worsening of Tubercular Multifocal Serpiginoid Choroiditis after the Initiation of Anti-Tubercular Therapy. *Ocul Immunol Inflamm.* 2019;27(3):365-370. doi: 10.1080/09273948.2017.1373829. Epub 2017 Oct 11. PMID: 29020501.
12. Ireni S, Mooss VS, Kelgaonkar A, Babu K, Basu S. Tubercular Serpiginous-Like Choroiditis in Patients with Negative TB-Immunoreactivity Tests. *Ocul Immunol Inflamm.* 2023 Sep 28:1-7. doi: 10.1080/09273948.2023.2258399. Epub ahead of print. PMID: 37769244.
13. Cordero-Coma M, Benito MF, Hernández AM, Antolín SC, Ruiz JM. Serpiginous choroiditis. *Ophthalmology.* 2008 Sep;115(9):1633, 1633.e1-2. doi: 10.1016/j.ophtha.2008.05.009. PMID: 18762076.
14. Bansal R, Sharma K, Gupta A, Sharma A, Singh MP, Gupta V, Muljutkar S, Dogra M, Dogra MR, Kamal S, Sharma SP, Fiorella PD. Detection of Mycobacterium tuberculosis genome in vitreous fluid of eyes with multifocal serpiginoid choroiditis. *Ophthalmology.* 2015 Apr;122(4):840-50. doi: 10.1016/j.ophtha.2014.11.021. Epub 2015 Jan 9. PMID: 25578256.
15. Mandadi SKR, Agarwal A, Aggarwal K, Moharana B, Singh R, Sharma A, Bansal R, Dogra MR, Gupta V; for OCTA Study Group. NOVEL FINDINGS ON OPTICAL COHERENCE TOMOGRAPHY ANGIOGRAPHY IN PATIENTS WITH TUBERCULAR SERPIGINOUS-LIKE CHOROIDITIS. *Retina.* 2017 Sep;37(9):1647-1659. doi: 10.1097/IAE.0000000000001412. PMID: 27930457
16. Agarwal A, Corvi F, Kumar Menia N, Aggarwal K, Erckens RJ, Berendschot TTJM, Webers CAB, Invernizzi A, Gupta V, Sadda S. Choriocapillaris Flow Deficit in Tubercular Serpiginous-Like Choroiditis with and without Paradoxical Worsening. *Ocul Immunol Inflamm.* 2022 Nov 3:1-7. doi: 10.1080/09273948.2022.2140296. Epub ahead of print. PMID: 36328764.
17. Tummala GC, Chu Z, Weinstein JE, Wang RK, Pepple KL. Swept source OCTA reveals a link between choriocapillaris blood flow and vision loss in a case of tubercular serpiginous-like choroiditis. *Am J Ophthalmol Case Rep.* 2021 Jan 25;21:101018. doi: 10.1016/j.ajoc.2021.101018. PMID: 33553805; PMCID: PMC7851177.
18. Klufas MA, Phasukkijwatana N, Iafe NA, Prasad PS, Agarwal A, Gupta V, Ansari W, Pichi F, Srivastava S, Freund KB, Sadda SR, Sarraf D. Optical Coherence Tomography Angiography Reveals Choriocapillaris Flow Reduction in Placoid Chorioretinitis. *Ophthalmol Retina.* 2017 Jan-Feb;1(1):77-91. doi: 10.1016/j.oret.2016.08.008. Epub 2016 Oct 17. PMID: 31047399.

19. Borrelli E, Sarraf D, Freund KB, Sadda SR. OCT angiography and evaluation of the choroid and choroidal vascular disorders. *Prog Retin Eye Res.* 2018 Nov;67:30-55. doi: 10.1016/j.preteyeres.2018.07.002. Epub 2018 Jul 27. PMID: 30059755.
20. Gupta A, Bansal R, Gupta V, Sharma A, Bambery P. Ocular signs predictive of tubercular uveitis. *Am J Ophthalmol.* 2010 Apr;149(4):562-70. doi: 10.1016/j.ajo.2009.11.020. Epub 2010 Feb 10.
21. Gan WL, Jones NP. Serpiginous-like choroiditis as a marker for tuberculosis in a non-endemic area. *Br J Ophthalmol.* 2013 May;97(5):644-7. doi: 10.1136/bjophthalmol-2012-302918. Epub 2013 Feb 28. PMID: 23449344; MID: 20149341.
22. Krassas N, Wells J, Bell C, Woodhead M, Jones N. Presumed tuberculosis-associated uveitis: rising incidence and widening criteria for diagnosis in a non-endemic area. *Eye (Lond).* 2018 Jan;32(1):87-92. doi: 10.1038/eye.2017.152. Epub 2017 Aug 4. PMID: 28776591; PMCID: PMC5770703.
23. La Distia Nora R, van Velthoven ME, Ten Dam-van Loon NH, Misotten T, Bakker M, van Hagen MP, Rothova A. Clinical manifestations of patients with intraocular inflammation and positive QuantiFERON-TB gold in-tube test in a country nonendemic for tuberculosis. *Am J Ophthalmol.* 2014 Apr;157(4):754-61. doi: 10.1016/j.ajo.2013.11.013. Epub 2013 Nov 18. PMID: 24262781.
24. Bansal R, Bansal P, Gupta A, Gupta V, Dogra MR, Singh R, Katoch D. Diagnostic Challenges in Inflammatory Choroidal Neovascular Membranes. *Ocul Immunol Inflamm.* 2017 Aug;25(4):554-562. doi: 10.3109/09273948.2016.1160128. Epub 2016 Apr 15. PMID: 27082010.
25. Agarwal A, Invernizzi A, Singh RB, Foulsham W, Aggarwal K, Handa S, Agrawal R, Pavesio C, Gupta V. An update on inflammatory choroidal neovascularization: epidemiology, multimodal imaging, and management. *J Ophthalmic Inflamm Infect.* 2018 Sep 12;8(1):13. doi: 10.1186/s12348-018-0155-6. PMID: 30209691; PMCID: PMC6135736.
26. Aggarwal K, Agarwal A, Sharma A, Sharma K, Gupta V; OCTA Study Group. DETECTION OF TYPE 1 CHOROIDAL NEOVASCULAR MEMBRANES USING OPTICAL COHERENCE TOMOGRAPHY ANGIOGRAPHY IN TUBERCULAR POSTERIOR UVEITIS. *Retina.* 2019 Aug;39(8):1595-1606. doi: 10.1097/IAE.0000000000002176. PMID: 29689028.
27. Hutchinson J. Serpiginous choroiditis in scrofulous subjects-Choroidal lupus. *Arch Surg (Lond)*1900;11:126-35.

**Acknowledgments 1:** Apart from Anita Agarwal, Vishali Gupta, and Reema Bansal mentioned above, several other people contributed significantly to this work becoming a reality including Prof Pradeep Bambery and Prof Aman Sharma both professors of Internal Medicine, Prof Shobha Sehgal, Prof Sunil Arora both from the Department of Immunopathology, Prof Kusum Sharma, Professor of Microbiology and Arun Kapil Ophthalmic photographer.

**Acknowledgment 2:** The story was reviewed by Dr. Anita Agarwal, currently with the West Coast Retina Medical Group, San Francisco, CA.

**Padmashree Professor Amod Gupta** is an Emeritus Professor at the Post Graduate Institute of Medical Education and Research, Chandigarh (India). He headed the Department of Ophthalmology at the PGI from 1989 to 2015. He raised the Advanced Eye Centre at the PGI, Chandigarh in 2006.

He has published 415 original research papers in peer-reviewed journals which are extensively cited in the contemporary literature. He was the founder President of the Uveitis Society of India and President of the Vitreo Retinal Society of India. In 2003, he described a new entity 'Tubercular Serpiginous-like choroiditis' that is now recognized all over the world.



Being installed by Prof. N A Rao in Feb 2004 as the Founder President of the Uveitis Society of India. Reproduced from Bansal R, Sen A. Prof. Amod Gupta - The leader and the legacy. Indian J Ophthalmol. 2023 May;71(5):1671-1674. doi: 10.4103/IJO.IJO\_937\_23. PMID: 37203015; PMCID: PMC10391380 under the Creative Commons Attribution-Non-Commercial-Share Alike 4.0 License.

With Prof I S Jain and other faculty members on the day of the inauguration of the Advanced Eye Centre, 18 March 2006

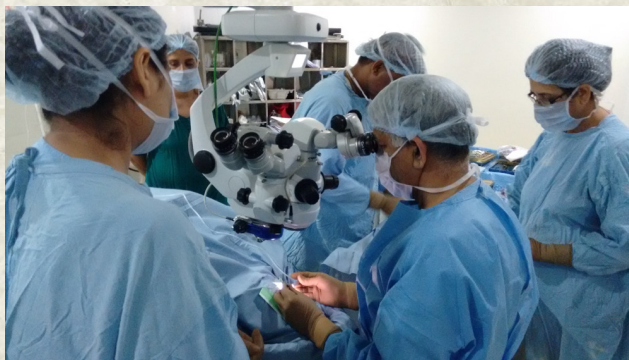

With the then President of India, Shree APJ Abdul Kalam on March 8, 2007, during his visit to the AEC.



Being conferred the Padma Shri, 4<sup>th</sup> highest civilian award of India on April 26, 2014, by the then President of India Shree Pranab Mukherjee. Reproduced from Gupta A. My tryst with academia – Reflections from an era gone by. Indian J Ophthalmol 2023;71:1675-80 under the Creative Commons Attribution-Non-Commercial-Share Alike 4.0 License.

Being Conferred the Vigyan Ratan of the Panjab University in March 2015 by the President of India, Shri Pranab Mukherjee. Reproduced from Gupta A. My tryst with academia – Reflections from an era gone by. Indian J Ophthalmol 2023;71:1675-80 under the Creative Commons Attribution-Non-Commercial-Share Alike 4.0 License,



Last surgery of Prof Amod Gupta 19th August 2015 reproduced from Bansal R, Sen A. Prof. Amod Gupta - The leader and the legacy. Indian J Ophthalmol. 2023 May;71(5):1671-1674. doi: 10.4103/IJO.IJO\_937\_23. PMID: 37203015; PMCID: PMC10391380 under the Creative Commons Attribution-Non-Commercial-Share Alike 4.0 License

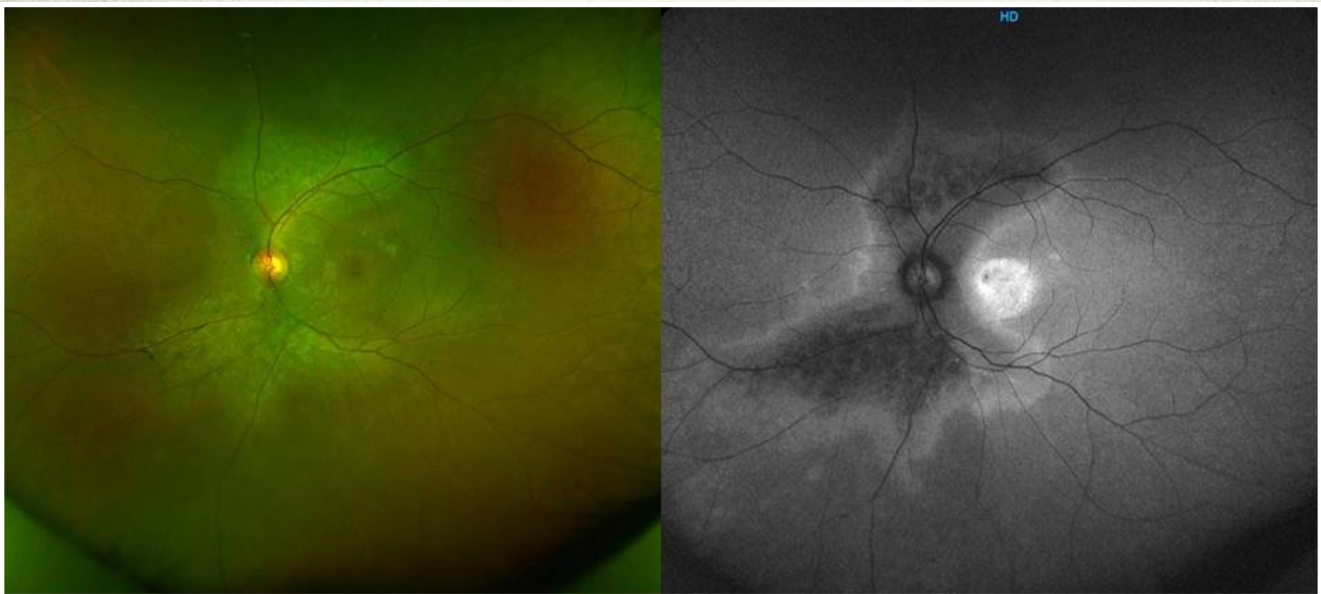


## Image Contest Winner

### The Trizonal Tapestry of AZOOR



**Dr. Dhaivat Shah**, MS, DNB, FMRF  
Joint Medical Director, Choithram Netralaya, Indore.  
[dhaivatkshah@gmail.com](mailto:dhaivatkshah@gmail.com)



*In this image captured by OPTOS, autofluorescence imaging reveals a distinctive trizonal pattern, a hallmark finding in Acute Zonal Occult Outer Retinopathy (AZOOR). The pattern is characterized by a hypoautofluorescent lesion inside, surrounded by a hyperautofluorescent granular line, with normal autofluorescence outside this area.*

# Serpiginous and Serpiginous like Choroiditis: What We Must Know



**Dr. Sai Bhakti Mishra**, DNB, FICO  
Consultant



**Dr. Ankush Kawali**, DNB, FICO  
Consultant



**Dr. Padmamalini Mahendradas**, DO DNB  
Head of the Department, Uveitis and Ocular Immunology  
Narayana Nethralaya, Bengaluru  
[m.padmamalini@gmail.com](mailto:m.padmamalini@gmail.com)

## Introduction

**S**erpiginous choroiditis (SC) is a descriptive term for a chronic, bilateral and recurrent inflammation of the choroid that spreads in a geographic pattern causing choriocapillaris atrophy and loss of overlying retinal pigment epithelium (RPE) leading to the secondary degeneration and loss of photoreceptor cells lying in adhesion to the atrophied RPE. [1] In 1900, Sir Jonathan Hutchinson, an English surgeon, dermatologist, and ophthalmologist, was the first to describe SC in his article “Serpiginous Choroiditis in Scrofulous Subjects: Choroidal Lupus” as a characteristic choroidal inflammation that caused creeping progression with

active borders that, when healed, had the appearance of “the borders of a continent in a map”. [2] In 1970, Gass coined the term ‘serpiginous choroiditis’ to describe this entity where recurrences usually began in the peripapillary area and spread centrifugally over a period of months or years in a serpiginous or jigsaw puzzle-like distribution. [3] From then this condition has been described by various other names in literature: peripapillary choroiditis, helicoid peripapillary chorioretinal degeneration, helicoid peripapillary choroidal sclerosis, geographic helicoid peripapillary choroidopathy, geographic

helicoid choroidopathy, serpiginous choroidopathy. Initially this disease was described in patients with tuberculosis and syphilis, but the disease was subsequently considered to be an idiopathic choroiditis with an underlying autoimmune process that causes a specific trigger for a localized ocular immune response. [4,5] Sporadic association of SC has been reported with a few known systemic diseases, such as Crohn's disease, non-Hodgkin's lymphoma, polyarteritis nodosa, sarcoidosis, systemic lupus erythematosus, and Celiac disease [6-12]. With no definitive cause identified, an autoimmune mechanism has been postulated to cause SC. Recently, a morphologically similar disease commonly referred to as multifocal serpiginoid choroiditis (MSC) and serpiginous-like choroiditis (SLC) has been described.

With advancements in molecular diagnostics including the polymerase chain reaction (PCR) and interferon gamma release assay, microorganisms have been suggested as inciting agents, either through active proliferation or a process of molecular mimicry that induces an immune response against the microbes which may also target the uveal and retinal tissues. [13-21] Despite our increased understanding of the presentation, natural course, and prognosis of SC, the pathogenesis of this characteristic form of choroiditis remains a mystery. Among the infectious etiologies causing choroiditis mimicking SC, tuberculosis (TB) is the commonest [22,23]. Others include syphilis [24], viral infections [25,26], toxoplasmosis [27], fungal infection [28] and others [29]. Recently, SC has also been reported following SARS- CoV-2 infection [30]. The term 'serpiginous-like choroiditis' (SLC) was first used in 2003 to describe tubercular connection with this form, and 'multifocal serpiginoid choroiditis' (MSC) followed in 2012. [31,32] to differentiate

this variant from the classic SC. Though the diagnosis of SC and SLC is essentially clinical, the two have several phenotypic differences.

### **Demography and epidemiology**

Majority of the data is from institute-based studies which are tertiary eye care setups and did not differentiate between SC and SLC. SC is a relatively rare condition, with a prevalence ranging from 0.2% to 5% of all uveitis patients. [33-38] Prevalence rates in Southeast Asian countries were noted to be higher than in other parts of the world [33,34, 38-42] with a possible role of infectious etiology being implicated to explain the relative higher incidence of SC in these regions. The reported prevalence of SC in India varies from 1.2% to 5.4% [37,40,43,44] However, relatively lower prevalence of SC has been reported from the other countries in the Indian subcontinent [38,45,46] while, a relative higher prevalence of SC has been reported from countries like Germany and United states. [35,47,48] Tubercular SLC (TB SLC) is considered to be affecting people living in TB endemic areas, nonetheless, a growing number of them are now being identified in non-endemic places as well. [43,46,49-51] Among the three phenotypes of tubercular choroiditis, TB SLC is the commonest, followed by focal or multifocal choroiditis and tuberculoma. [52] Men are more frequently affected than females, and are typically in young to middle-age group. [53]

### **Etiopathogenesis**

Infectious, autoimmune, and/or degenerative processes have all been proposed as potential causes of SC, however this has always been speculated. [54-56] In addition to people with clinical or laboratory evidence of ocular or systemic infections, recurrent choroiditis with creeping serpentine progression can also occur in

healthy persons without visual symptoms. [2,3,57] There is no unifying, overarching systemic or ocular etiology for SC, although anecdotal evidence of a link with systemic illnesses has been observed, patients with SC usually have good overall health. Given the fundus alterations observed in SC and the predilection for middle-aged persons to be involved, a degenerative process is suggested as the underlying cause; [56,58] nevertheless, degenerations are typically linked to tissue loss and a build-up of acellular material, which is not corroborated by clinical, imaging, or histologic investigations of SC. [3,59] The absence of family aggregation, late onset, and asymmetric development in both eyes work against a hereditary dystrophic process. [52,56] One of the main characteristics of SC is choriocapillaris blockage, according to angiographic investigations. [57,60] A higher activity and increased levels of Von Willebrand factor may have a role that vascular endothelial cell damage played in the development of the choriocapillaris has been implicated. [51,61]

### **A. Autoimmune**

When compared to the general population, patients with SC had greater frequencies of HLA-B7, HLA-A2, HLA-B8, and HLA-Dw3, which could indicate an underlying, genetically predisposed autoimmune process. [57,62-64] For SC patients, there is no evidence of a consistent correlation between these HLA frequencies and any systemic autoimmune diseases. Patients with SC have been reported to have circulating lymphocyte auto-reactivity to retinal S antigen. [65] The fact that SC inflammation responds favourably to immunosuppressive medications suggests that immunological processes play a significant role in pathogenesis. However, it is yet unknown what causes this localised inflammatory response. Consideration of SC

as a "idiopathic" intraocular inflammation with a potential organ-specific autoimmune process is warranted, even though the exact cause of the choroidal and RPE inflammation beginning or persistence is yet unknown.

### **B. Infectious**

Since Hutchinson first reported the connection between SC and syphilis and tuberculosis, microbiological diseases have been considered as potential initiating factors. [2,66] Many efforts have since been made to identify infectious pathogens in SC. The infectious aetiologies that have been proposed for SC can be classified as bacterial, viral, protozoal and fungal. [27,56]

1. *Bacteria*—Although serpiginous or multifocal serpiginoid lesions have been reported in a few patients with syphilis, [24,67,68] presumed or definite MTB is the most often considered underlying bacterial infection. Mycobacterium tuberculosis (MTB) has been identified as a direct or indirect infectious trigger in TB SLC by demonstrating MTB presence in the vitreous, aqueous, retinal pigment epithelium (RPE), or choroid. [32,69] The most typical, albeit presumed, etiological relationship of MTB with SLC is the existence of latent MTB infection or a systemic, extraocular focus of MTB infection. [32,47,69,70]

There is a dearth of knowledge regarding the immunological system underlying tuberculous infection in humans. The manifestation of both cellular and humoral responses to many retinal antigens is pointing to the relevance of autoimmunity and autoinflammation in infectious or undifferentiated uveitis. [71-74] Forrester et al. explained how immunological pathways relate to MTB-induced ocular inflammation. [71] During the early stages of lung infection, the MTB specifically

targets dendritic cells and macrophages. As it escapes and takes up residence in the other myeloid cells, the MTB either kills them or is destroyed by them. The MTB-infected cells recirculate from the granulomas and reach extrapulmonary locations, such as the kidney, muscle, meninges, lymph nodes, and uvea. It lives in these tissues and could reactivate at any point in the future. When MTB proliferates and results in local infection, the tissue undergoes caseation necrosis. In immunocompetent people, it triggers a strong host immunological reaction that results in immune-mediated inflammation and damage. A secondary autoimmune reaction results from the dying cells' release of MTB antigen, which prompts autoreactive T cells and innate immune cells to react. [74]

Autoreactive T lymphocytes were found in the eyes of patients suffering from tubercular uveitis (TBU) by Tagirasa et al. [74] Retinal vasculitis, MSC (or SLC), localised choroiditis, and intermediate uveitis were among the clinical manifestations of TBU in their series. They examined the intraocular T cell response in vitreous fluid and discovered that effector and central memory T cells were heavily involved in the pro-inflammatory response. They discovered that CD4+ cells are the predominant phenotype in all eyes with TBU, indicating the biological source of these cytokines. It is possible that the vitreous T cell response was focused on combating an active MTB infection because they also found polyfunctional cytokine responses to ESAT-6 peptides released by MTB. The comparable blood samples of TBU patients did not exhibit this cytokine response to ESAT-6, suggesting that the MTB-specific response is localised and limited to the eye. The breakdown of BRB, which is brought on by inflammation triggered by MTB, permits peripheral autoreactive cells to enter the eye.

Peripheral autoreactive cells in the eye are stimulated to multiply by homologous self-antigens, which are much more prevalent than MTB antigens in the eye. The reason for a protracted or recurring intraocular inflammation is most likely the autoreactive T cells' relative resistance to antigen-induced cell death. This work offered unambiguous proof of a direct (intraocular T cell response to the mycobacterial antigen ESAT-6) as well as an indirect (intraocular T cell production of cytokines in response to retinal crude extract, or RCE), response in TBU-affected eyes, including TB SLC.

A few studies have also indicated an elevation in proinflammatory cytokines in the vitreous/aqueous humour (intraocular fluid) of TBU patients. [75-78] Among the invading T cells, CD3+, CD4+, and CD8+ T cells made up the majority. It was discovered that these T cells had just become activated, and that they had secreted proinflammatory cytokines, such as IFN- and IL-17A, into the vitreous. The patients' vitreous blood had larger levels of these cytokines than their peripheral blood, indicating a localised rather than systemic source for the antigenic trigger. Serum cytokine levels in MSC were examined at baseline and during a longitudinal follow-up in patients treated with anti-tubercular treatment (ATT) and oral corticosteroids; this study included cases of paradoxical worsening (PW). [78] Patients with PW showed increased serum levels of IL-10 at baseline, significantly elevated levels of IFN- at one week, and significantly elevated levels of TNF- at three weeks, relative to patients with complete healing of lesions. The levels of TGF- $\beta$  were similar in the two groups. This suggested that a greater bacillary burden during PW caused a rise in pro-inflammatory cytokines in the serum. [78]

2. *Viruses*— Possible causative agents of SC include herpes viruses. [79,80,81] VZV was proposed as the etiologic agent by Gass in his description of a patient with Herpes zoster ophthalmicus who had fundus alterations of SC. [3] Curiously, a recent PCR investigation from a TB endemic region revealed VZV and HSV DNA in the aqueous humour of patients with recurrent macular variant of SC, with or without concomitant peripapillary lesions, and with a normal chest X-ray and negative TST. [79] The virus-associated cases differ from idiopathic SC in that they present with vitritis and anterior chamber cellular response along with multifocal lesions that mostly affect the macula. One Finnish study showed anti-hepatitis A antibodies, however this was explained by the high incidence of these antibodies in the general population. [81].

3. *Protozoa*— A few researchers believe that *Toxoplasma gondii* may be the etiologic agent of SC. [27,62,63] Old, dormant SC lesions may resemble the chorioretinal scars left behind by toxoplasma retinochoroiditis. [3,63] In contrast to SC, toxoplasma retinochoroiditis generally causes retinal lesions with concomitant vitritis, even though active lesions in both disorders typically originate from the edges of older scars. The results of anti-toxoplasma antibody testing in certain SC studies were negative. [57,82]

4. *Fungi*— It is doubtful that intraocular fungal infections and SC are interchangeable because of their fulminant nature. However, a recent PCR analysis has suggested that SC might be caused by *Candida* sp. [28] *Candida* antigens, DNA, and high serum titers of antibodies against *Candida* species were found in four out of five SC patients. [28] Other investigations have not verified this.

## Histopathologic features

There is currently little understanding of the pathophysiology of SC, possibly due in part to the paucity of histopathologic investigations that provide evidence of SC. Although histology has not revealed any active lesions, substantial mononuclear inflammatory cell infiltration of the choroid with localised lymphocyte aggregation has been found in clinically inactive lesions in long-standing SC. [5] Variable degrees of RPE hyperplasia and Bruch membrane abnormalities, including atrophic choriocapillaris, RPE, and photoreceptors, around fibrotic choroidal lesions. [3,61] Unremarkable choroidal vessels can be found in unaffected areas, and a small number of retinal vessels have mild lymphocytic infiltration.

Using three distinct molecular methods—multitargeted PCR for MTB assay, Gene Xpert MTB/RIF assay, and a line probe assay—Bansal et al. were able to identify the MTB genome in the vitreous fluid of eyes with TBSLC [83]. Histological slices of the globe showed granulomatous inflammation of the uveal tissue and retina in an enucleated eye with panuveitis of unknown aetiology [84]. When eyes with panuveitis or tubercular choroiditis (TBSLC) were examined, the RPE revealed necrosis and contained sequestered acid-fast bacilli, indicating that the RPE was the preferred location for MTB localization. These phagocytosed bacilli, which are sequestered in the RPE and survive by evading phagolysosome fusion, are represented by the macrophages in pulmonary tuberculosis. TBSLC most likely recurs as a result of their reactivation in the RPE.

Clinicopathologic characteristics of tuberculous SLC in a male 28-year-old patient were reported by Kawali et al. When the patient started ATT and developed paradoxical worsening with progressive macular choroiditis, a vitreous and chorioretinal biopsy was performed [85].

Following a biopsy, the inner choroid was found to have caseous necrosis and granulomatous inflammation, along with RPE degradation and photoreceptor disturbance.

Serpiginous choroiditis	Serpiginous-like choroiditis
<i>Etiology-</i>	
Non-infectious/autoimmune	Infectious
Retinal S antigen	Bacteria: Tuberculosis, syphilis
idiopathic organ specific inflammation	Viruses: HSV, VZV
HLA association	Protozoa: Toxoplasma
systemic disease association	Fungi: Candida spp.
<i>Morphological subtypes-</i>	
a. Serpiginous choroiditis extending from juxtapapillary choroid	a. Dendritic SLC
b. Macular serpiginous choroiditis	b. Placoid SLC

**Table 1.** Differences between serpiginous choroiditis (SC) and serpiginous like choroiditis (SLC)

### Clinical features

A creeping pattern of choroiditis, extending from the juxtapapillary area, with greyish yellow discoloration, minimal to no inflammatory cell infiltration in the vitreous, and recurrences of the lesions at the margins of the healed scars, is the most common manifestation of SC, though it can take many different forms. [4,86,87] SC lesions typically have subtle symptoms when they first appear. [57] Initial complaints from patients may include floaters, metamorphopsia, blurred vision, difficulties reading, paracentral scotomas, or other visual field problems. [57,91,92,94] Visual acuity might be anywhere from 20/20 to counting fingers at one to three feet. Slitlamp examination may reveal a quiet eye from external and anterior segment evaluation. Low-grade anterior chamber and vitreous reaction, if any may be present. [60] The intraocular pressure does not typically change. [94] At the level of the RPE and deep retina, the new lesions are identified by well-defined patches of grayish-white or grayish-yellow discoloration. Usually, the borders of healed lesions give rise to such active lesions. These show an outward pattern of choroidal atrophy linked to alterations in RPE that starts at the peripapillary region. Outside the boundaries of active or healed lesions, the retina and RPE seem normal. Comparable atrophic lesions in the

juxtapapillary choroid may be observed upon examination of the partner eye.

The grayish-white lesions give way to mottled RPE over the course of weeks to months, either in conjunction with or without pigment epithelial hyperplasia and fibrosis. The symptoms of activity could persist for up to nine months if untreated. [57] The diagnosis is strongly supported by the simultaneous occurrence of healed and active lesions. [60,93] Geographic atrophic patches with pseudopodial extensions and well defined, sharp borders, either with or without pigment epithelial hyperplasia at the margins, characterise the healed, inactive chorioretinal lesions. [57] In untreated eyes, the natural course varies, but often involves several choroidal inflammatory recurrences and advancement over months to years, with the possibility of involving the fovea at some point [57] It is anticipated that at least one recurrence will occur in five years for about 50% of SC patients. [95] The choroiditis resolves over 20 years or more in the absence of anti-inflammatory therapy, leaving significant chorioretinal scarring. The average duration between presentation in one eye and onset in the contralateral eye is about 5 years. [60]

Classic SC (CSC) can be further separated into the following categories based on the features and morphology of lesions: The most prevalent kind of CSC that has been documented in literature is peripapillary CSC. Peripapillary CSC instances account for almost 80% of all reported cases. [4,88] Peripapillary CSC lesion is often unifocal, centred around the optic disc and progressing centrifugally in a serpentine pattern to involve the macula. Due to its early macula involvement and increased likelihood of developing choroidal neovascular membrane (CNVM), macular CSC is a relatively uncommon yet feared cause of visual loss. [89] Up to 88% of SC patients who are not receiving treatment can progress to involve the macula and can spread to the equator. [95] Certain patients may be subcategorized as macular SC if they only have macular involvement at presentation.

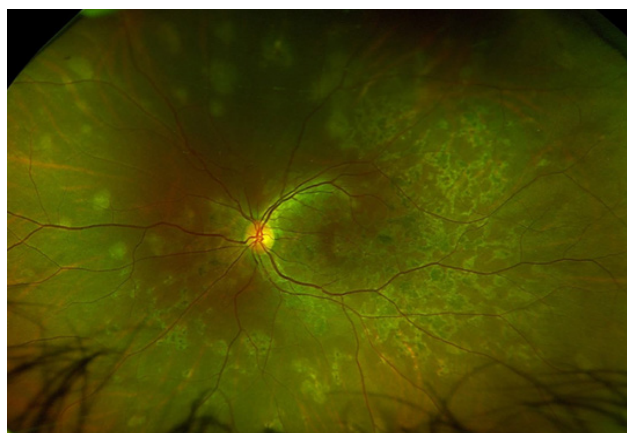
#### *Macular serpiginous choroiditis*

Roughly one-third of patients had lesions that start at or only go to the macula. Macular SC, [89,94,96] is the name given to this type of choroiditis, which manifests as floaters, flashing lights, scotomas, and blurred vision. [96,89] The juxtapapillary choroid may not be affected, and emerging lesions typically lack the distinctive geographic atrophic scars, [89] making diagnosis difficult. However, the angiographic characteristics of classic SC and macular SC are the same. [89,94] In-depth testing to rule out infectious etiology, such as an aqueous or vitreous tap to identify MTB or the herpes virus by PCR, may be necessary for the macular variety of SC. Macular SC lesions have a worse prognosis in terms of vision. [89] The development of choroidal neovascular membrane (CNVM) is more common. In one series, three out of seven patients with macular SC went on to develop CNVM. [89] Since these individuals typically experience symptoms early in the disease, they frequently receive rapid therapy, which over

time leads to less widespread involvement of the choroid and posterior retina. [91]

#### ***Serpiginous-like choroiditis***

Multifocal choroidal lesions of different sizes and shapes, which frequently combine to generate diffuse choroiditis that resembles SC in patients with suspected tuberculosis, are the distinguishing feature of SLC, a separate form of SC. [22] It has also been used to refer to these clinical entities as "multifocal serpiginoid choroiditis" [32,88,90] As opposed to patients with SC, patients with SLC are typically from areas where tuberculosis is endemic; they are also more likely to present unilaterally, at a younger age, with multifocal lesions, located in the periphery of the retina, frequently sparing the juxtapapillary region, have a greater inflammatory reaction in the vitreous, and continue to progress even after receiving effective corticosteroid therapy. [22,31,70,90]



*Figure 1 . Dendritic form of serpiginous like choroiditis. Vividly multifocal small grayish yellow lesions that coalesce to form larger lesions.*

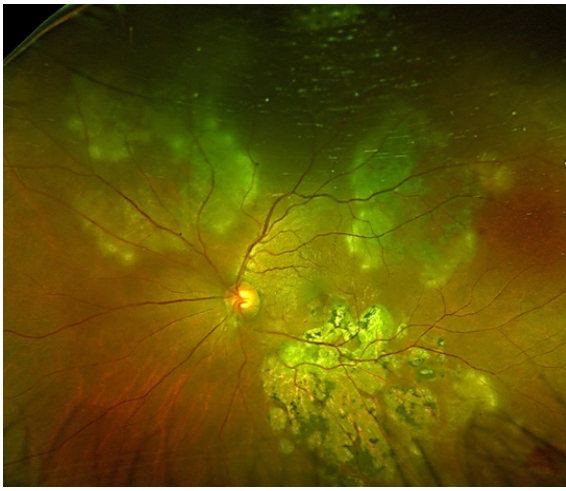

Figure 2. Placoid form of serpiginous like choroiditis . Placoid areas of gray-yellow discoloration of the retina at the site of active lesions. There is gradual clearing of the lesion from the center, while the peripheral edges of the lesion often maintain grayish-white active appearance. Reactivation happens at the edges of old scars.

	Diagnostic modality	Findings in SC/SLC
1	Fundus photography (FP)	<ul style="list-style-type: none"> <li>• Important for baseline documentation</li> <li>• Helps monitor treatment response</li> <li>• Resolution, progression, recurrence best appreciated</li> <li>• Widefield imaging preferred to assess progressive margins or paradoxical worsening [97,98]</li> </ul>
2	Fundus fluorescein angiography (FFA)	<p>Active lesions : Hypofluorescence to hyperfluorescence</p> <ul style="list-style-type: none"> <li>• Early phase - show hypofluorescence with fuzzy, uneven borders due to hypoperfusion of the choriocapillaris and obstruction of fluorescence due to edematous, inflammatory RPE and retina.</li> <li>• Mid-phase - shows a progressive hyperfluorescence at the lesion border due to dye leakage from the choriocapillaris at the edge of the inflamed lesions.</li> <li>• Late phase - Larger choroidal arteries start to leak dye profusely over time, causing the lesions to become hyperfluorescent.</li> </ul> <p>Healed lesions : Patchy herfluorescence</p> <ul style="list-style-type: none"> <li>• Early phase – shows hypofluorescent patches with distinct borders, which are caused by the substantial loss of the choriocapillaris.</li> <li>• Mid- phase – shows increased hyperfluorescence at the borders of healed lesions</li> <li>Late phase – shows widespread staining of these lesions as fluorescein diffuses into the scarred area from the surrounding normal choriocapillaris.</li> </ul>
3	Indocyanine green angiography (ICGA)	<p>Active lesions – hypofluorescence from early to late phase</p> <ul style="list-style-type: none"> <li>• Caused due to anomalies in choroidal perfusion and blocked fluorescence by the inflamed RPE and outer retina</li> <li>• Choroidal involvement seen in ICG is more than indicated by clinical examination or FFA</li> </ul> <p>Healed lesions - early and late hypofluorescence with well-defined boundaries</p> <ul style="list-style-type: none"> <li>• Hypofluorescent patches may be non-uniform due to altered choroid and RPE pigmentation and varying retention of the larger choroidal veins</li> <li>• They reflect permanent loss of choriocapillaris and concomitant choroidal atrophy</li> </ul> <p>Differentiate choroiditis from CNVM</p> <ul style="list-style-type: none"> <li>• Choroiditis typically exhibits early hypofluorescence while CNVM shows hyperfluorescence</li> </ul> <p>ICGA is superior to fundus examination and FFA in identifying subclinical active lesions [99,100]</p>

4	Fundus autofluorescence (FAF)	<ul style="list-style-type: none"> <li>• Based on the property of autofluorescence of lipofuscin</li> <li>• Rapid and non-invasive method</li> <li>• Treatment response is more superiorly evaluated than FA, ICGA</li> <li>• TBMSC /SLC -4 stages have been described [101,102]</li> </ul> <p>Stage I – diffuse, poorly defined halo of hyperautofluorescence  Stage II – centre hyperautofluorescence becomes noticeable  Stage III – stippled appearance as peripheral hypoautofluorescence increases and central hyperautofluorescence reduces  Stage IV – widespread hypoautofluorescence that intensifies with time as scarring develops</p>
5	Optical coherence tomography (OCT)	<ul style="list-style-type: none"> <li>• typical lesions show hyperreflectivity in the outer retina that later leads to loss of the RPE and the inner and outer segment junctions.[103]</li> <li>• focal elevation of the RPE-Bruch's membrane complex and neurosensory retina on EDI-OCT [104]</li> <li>• choroidal thickness, total choroid area, volume of the vascular and stromal choroid is significantly increased in active lesions and decreases significantly as the lesions heal [105]</li> </ul>
6	Optical coherence tomography angiography (OCTA)	<ul style="list-style-type: none"> <li>• A relatively new noninvasive investigative method that produces high-resolution, depth-resolved pictures of the choroidal and retinal vasculature</li> <li>• While retinal vascularity is intact, OCTA exhibits reduced vascularity on the choriocapillaris [106].</li> <li>• The hypofluorescent patches observed in the choriocapillaris layer of OCT-A match to hypofluorescent, hypoperfused areas on ICG. [107]</li> <li>• OCTA improves the ability to distinguish between choriocapillaris atrophy and hypoperfusion within the lesion. [108]</li> </ul> <p>Reduced retinal vessel length density (VLD) and perfusion density (PD), decreased choroidal vascularity index (CVI), and increased choriocapillaris flow deficit (CCFD) can be seen in active SLC. [109]</p>
7	Perimetry / Microperimetry	<ul style="list-style-type: none"> <li>• Amsler grid testing and Goldmann perimetry have been used to document dense scotomas associated with central and peripheral lesions. [95,110,111]</li> <li>• The preservation of the inner retinal layers, including the nerve fibre layer, in the context of extensive outer retinal destruction confirmed by perimetry.</li> <li>• The central vision remains unaltered even when there are serpiginous atrophic scars present in the papillomacular bundle because there is no involvement of the fovea. [112]</li> <li>• Conventional perimetry is not accurate if the patient has extrafoveal or unstable fixation and foveal function is impaired. [111]</li> <li>• Dense scotomas associated with active lesions and atrophic areas are carefully mapped using microperimetry, with point-to-point assessment of retinal sensitivity</li> <li>• Relative scotomas, seen in roughly one-third of patients, are caused by subclinical lesions. [111]</li> </ul>

8	Electrophysiology	<ul style="list-style-type: none"> <li>• retinal electrophysiology evaluates mass responses evoked from the entire retina</li> <li>• a near-normal whole field electroretinogram is observed in localised, non-extensive serpiginous lesions</li> <li>• a subnormal electroretinogram may be seen in long-term, untreated cases due to substantial retinal degeneration and involvement. [57,60,93,95]</li> </ul>
---	-------------------	---

**Table 2. Diagnostic imaging and investigation features of SLC lesions**

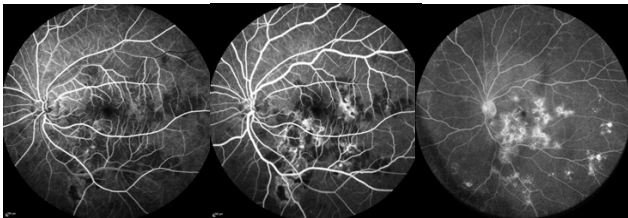


Figure 3a      Figure 3b      Figure 3c

**Figure 3. FFA features of active lesions of SLC.**  
 Early phase angiogram: hypofluorescent patch with poorly defined borders (3a) Mid-phase angiogram: gradual increase in fluorescence at the borders; hyperfluorescence (3b) Late phase angiogram: borders show hyperfluorescence; hyperfluorescence may spread centrally to form a uniform or spotty appearance in the entire lesion (3c)

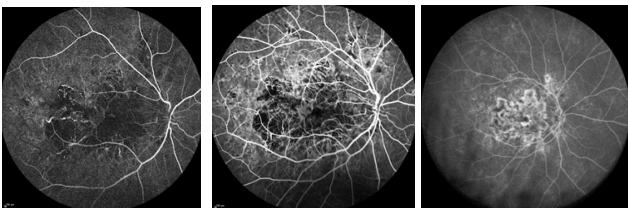


Figure 4a      Figure 4b      Figure 4c

**Figure 4. FFA features of healed lesions of SLC.**  
 Early phase angiogram: hypofluorescent patch (4a) Mid-phase angiogram: hypofluorescent patches with staining at borders (4b) Late phase angiogram: hypofluorescent patch with sharp staining of the margins (4c) In areas of excessive chorioretinal atrophy, the exposed scleral bed may be seen.

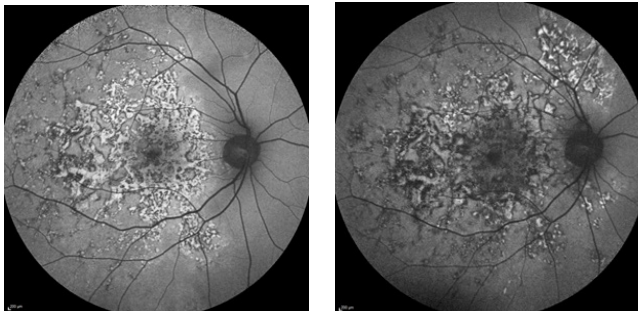


Figure 5a      Figure 5b

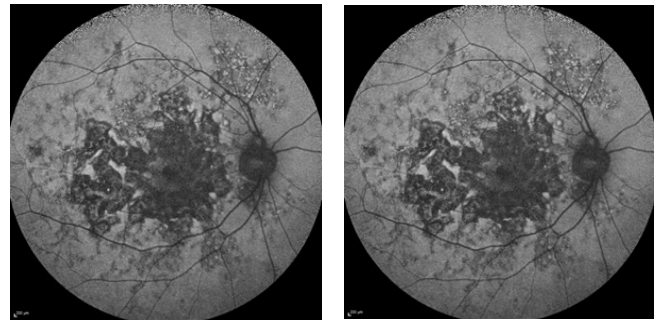


Figure 5c      Figure 5d

**Figure 5. FAF features of SLC**  
 Acute active lesions hyper- and hypoautofluorescence patches with sharp margins (5a). As healing progresses, lesions develop a more speckled appearance as hyperautofluorescence patches with hypoautofluorescent margin (5b). With healing, the lesions appear more hypofluorescent (5c) until they are completely healed and appear as a uniform hypoautofluorescent patch with sharp margins (5d).

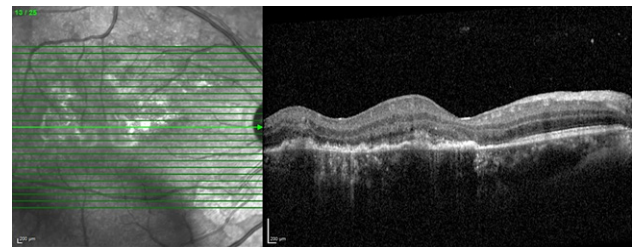


Figure 6a

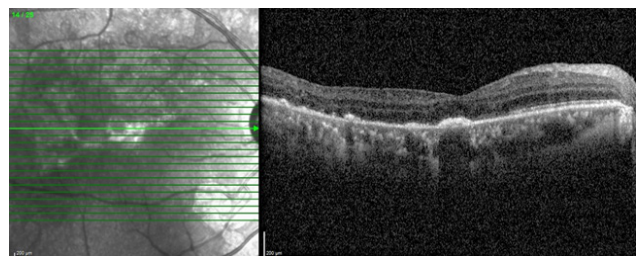


Figure 6b

**Figure 6. OCT features of SLC.**  
 Active lesion: 6a. Slightly increased retinal thickness (retinal edema), focal areas of choroidal thickening, outer retina and choroid hyperreflectivity

Healed lesion: 6b. Thin retina (outer retinal atrophy), loss of outer retina architecture (IS/OS and ELM loss), outer retina and choroid hyperreflectivity

## Complications

The primary vision-threatening issue in SC is involvement of the fovea. The most common and dreaded complication related to SC is CNVM and has an incidence ranging from 10% to 25%. [113] CNVM can occur in both healed and ongoing choroiditis, usually arising along the margin of the lesions. The etiopathogenesis of CNVM in SC has been linked to ischemia to the choroid, outer retina, and Bruch's membrane caused by choriocapillaritis. Patients with choroiditis are more susceptible to CNVM misdiagnosed, and occult CNVM in particular demands a high threshold of suspicion. [114] It is easier to distinguish classic CNVM from SC lesions, as SC lesions exhibit early hypofluorescence in FFA, while classic CNVM, which is typically characterised by early hyperfluorescence. However, because of its milder or less intense hyperfluorescence, occult CNVM in SC are difficult to diagnose. Another long-term, sight-threatening consequence associated with SC patients is subretinal fibrosis. [22,60] Retinal vasculitis, vascular occlusions, vitreous hemorrhage and subsequent neovascularization, serous retinal detachment, and cystoid macular edema are other less frequent consequences. [23] Tight management of inflammation could reduce the likelihood of these issues or even cause the neovascularization to spontaneously regress. [57,87,115,116]

## Treatment

### Treatment of serpiginous choroiditis

#### Corticosteroids

Since macular involvement is typically a determining factor in the reduction of visual acuity in SC patients, prompt and efficient therapy is essential to protect macular function. In patients with lesions threatening the macula, high-dose intravenous pulse steroids can be helpful. Another key factor in the therapy of patients with SC is the

recurrent inflammation. Although it has been demonstrated that higher dosages of corticosteroids quickly reduce inflammation, they typically don't stop recurrence. [117] Inflammation frequently recurs during corticosteroid tapering or after stopping the medication, necessitating use of systemic immunosuppressive therapy.

#### Immunosuppressive agents

Immunosuppressive medications, however, typically take longer to reach the appropriate therapeutic dose of the medication and cannot be used to treat acute exacerbations. The effectiveness of corticosteroids when taken alone or in combination with immunosuppressive medications is a topic of debate. A longer duration of disease inactivity and a lower risk of possible side effects from high-dose systemic steroids can be achieved with immunosuppressive medications such as methotrexate, azathioprine, cyclosporine, chlorambucil, or cyclophosphamide. A triple-agent immunosuppressive regimen consisting of cyclosporine, azathioprine, and prednisolone was found to be effective in the management of SC. [118-121]

#### Biologics

Adalimumab and infliximab are two biologicals that have been explored in the therapy of CSC. [122-124] Several authors have suggested that in cases of CSC that are resistant to various forms of treatment, biological therapy should be used, although, these patients also require antitubercular medication. [123,124] When planning anti-TNF alpha or other biological therapy modalities for patients with CSC, great caution should be exercised. Biological therapy is recommended as a last resort for the management of CSC in a nations with tuberculosis endemic regions.

## Local treatment

In patients with active CSC already receiving maximally tolerated systemic immunosuppressive therapy, intravitreal corticosteroid injection, such as fluconazole and dexamethasone implants, has been found to be a promising alternative therapeutic option as a rescue therapy because it induces rapid remission without the systemic side effects associated with systemic immunosuppression. [15,17,125] Prior to scheduling an intravitreal injection for the management of SC, caution should be exercised to rule out SLC. However, people with SLC have received intravitreal immunosuppressive medication, such as methotrexate. [126] Intravitreal anti-VEGF agents (Ranibizumab) can be used to treat choroidal neovascularization. [127]

## Treatment of serpiginous-like choroiditis/multifocal serpiginoid choroiditis

When there are distinctive clinical lesions and a suggestive history (such as contact with TB patients or origin from an endemic region), treatment for serpiginous like choroiditis (SLC) is typically presumptive diagnosis, with a positive tuberculin skin test and radiological evidence of pulmonary involvement and rarely a definitive diagnosis such as the isolation of *M. tuberculosis* genome in the patient's aqueous or vitreous sample. Anti-tubercular therapy (ATT) has been shown to manage active inflammation and prevent future recurrences in patients with SLC, despite the lack of definitive guidelines or recommendations. [47] Four-drug adjuvant therapy (ATT) is typically advised. The regimen consists of isoniazid (5 mg/kg), rifampicin (450–600 mg), ethambutol (15 mg/kg), and pyrazinamide (25–30 mg/kg) for the first three–four months, then isoniazid and rifampicin for a further nine months. In patients with MSC or SLC, multidrug resistant tuberculosis

necessitates a high index of suspicion, particularly when unusual signs or a poor response to treatment are present. [83]

*Paradoxical worsening:* Paradoxical worsening is defined by either the emergence of new lesions in a patient who initially gets better with ATT and oral steroids, or by the persistence of previous tuberculous lesions. 14% of the patients with SLC who had ATT were reported to show continued progression of the choroiditis lesion, according to a study. [128] Without concurrent oral steroid medication, a significant inflammatory immunologic reaction in the anterior chamber or vitreous may occur, which is known as a Jarisch-Herxheimer reaction. [60,129]. It's unclear exactly how antitubercular medication causes this deterioration. However, a number of mechanisms have been proposed, including higher bacillary load, increased baseline peripheral monocyte counts, and the presence of naturally occurring toxic cell-wall substances such as lipoarabinomannan and other endotoxins that, when treated with antitubercular drugs, cause an exaggerated inflammatory response upon the death of the mycobacterium. [130,131] It is well known that the RPE and macrophages have similar functions, such as phagocytosing microorganisms, expressing complement and toll-like receptors, and producing a range of inflammatory compounds when the RPE is activated. [132] Patients who are initiated on both ATT and systemic steroid concurrently may likewise have paradoxical deterioration. This is due in part to the extreme inflammation and insufficient suppression. Rifampicin may also have the effect of increasing steroid metabolism. [133] Such patients can be managed with upping the steroid dosage or introducing immunosuppressive medication. Certain clinical and imaging factors have been identified greater risk of poor therapeutic

response and paradoxical worsening include - higher grades of lesion opacity at baseline, [134] dual lesions margins, [135] and double layer sign on OCT. [136] Clinicians need to be aware of this phenomenon, and patients with SLC who are on ATT should receive careful fundus examinations and regular follow-up.

For the management of SLC, ATT treatment alone is insufficient. High-dose corticosteroid therapy, which can be administered locally or systemically, is warranted due to tissue damage that occurs after a significant inflammatory reaction in SLC and the potential for paradoxical worsening with ATT. Typically, gradual dosages of oral corticosteroids (1–1.5 mg/kg/day) are employed. Intravitreal corticosteroid injection can avoid the danger of latent TB activation in addition to avoiding possible systemic side effects. Furthermore, intravitreal corticosteroid can be a helpful adjuvant with ATT in situations when the existence of an active extrapulmonary or pulmonary tuberculosis necessitates the implementation of systemic immunosuppression with considerable caution. [137,138] There have been several reports from authors about the therapy of paradoxical worsening and the role of local immunosuppression. When it comes to managing the progressive lesions in tubercular multifocal serpiginoid choroiditis/SLC, dexamethasone intravitreal implants may be a good alternative for immunosuppressive medication or systemic steroids. [135,139] Two patients with suspected tuberculous SLC, whose lesions were growing and endangering the macula while receiving antitubercular medication, were shown to benefit from a single intravitreal injection of 400 mg/0.1 mL of methotrexate, according to Julian et al.'s report [126]. It was observed that these patients' lesions resolved without

any notable adverse effects. The authors postulated that the progression of SLC lesions may be attributable to either a paradoxical immune response to bacterial lysis or active illness, and that the local immunosuppressive impact of intravitreal methotrexate was responsible for them. [126]

## References

1. Jumper, JM.; McDonald, R.; Johnson, RN., et al. *Serpiginous choroiditis*. In: Ryan, SJ., editor. *Retina*. 4. Vol. 2 chapter 105. St Louis: Elsevier Mosby; 2006. p. 1811-20.
2. Hutchinson J. *Serpiginous choroiditis in scrofulous subjects: choroidal lupus*. *Arch Surg (Lond)* 1900;11:126-35.
3. Gass, JDM. *Stereoscopic Atlas of Macular Diseases: A Fundusoscopic and Angiographic Presentation*. St Louis: CV Mosby Co; 1970. p. 66
4. Lim WK, Buggage RR, Nussenblatt RB. *Serpiginous choroiditis*. *Surv Ophthalmol*. 2005; 50(3): 231–44.
5. Wu JS, Lewis H, Fine SL, et al. *Clinicopathologic findings in a patient with serpiginous choroiditis and treated choroidal neovascularization*. *Retina*. 1989; 9(4):292–301.
6. Ugarte M, Wearne IM. *Serpiginous choroidopathy: an unusual association with Crohn's disease*. *Clin Exp Ophthalmol*. 2002 Dec;30(6):437-9.
7. Rattray KM, Cole MD, Smith SR. *Systemic non-Hodgkin's lymphoma presenting as a serpiginous choroidopathy: report of a case and review of the literature*. *Eye (Lond)*. 2000 Oct;14 Pt 5:706-10.
8. Pinto Ferreira F, Faria A, Ganhão F. *Periarteritis nodosa with initial ocular involvement*. *J Fr Ophthalmol*. 1995;18(12):788-93.
9. Fiore PM, Friedman AH. *Unusual chorioretinal degeneration associated with sarcoidosis*. *Am J Ophthalmol*. 1988 Oct 15;106(4):490-1.
10. Edelsten C, Stanford MR, Graham EM. *Serpiginous choroiditis: an unusual presentation of ocular sarcoidosis*. *Br J Ophthalmol*. 1994 Jan;78(1):70-1.
11. Fuentes-Paez G, Celis-Sanchez J, Torres J, Martínez-Osorio H, Herreras JM. *Serpiginous choroiditis in a patient with systemic lupus erythematosus*. *Lupus*. 2005;14(11):928-9.
12. Mulder CJ, Pena AS, Jansen J, Oosterhuis JA. *Celiac disease and geographic (serpiginous) choroidopathy with occurrence of thrombocytopenic purpura*. *Arch Intern Med*. 1983 Apr;143(4):842.

13. Ang M, Htoon HM, Chee SP. Diagnosis of tuberculous uveitis: clinical application of an interferon-gamma release assay. *Ophthalmology*. 2009; 116(7):1391–6.
14. Kadhiravan T, Deepanjali S. Role of corticosteroids in the treatment of tuberculosis: an evidence-based update. *Indian J Chest Dis Allied Sci*. 2010; 52(3):147–8.
15. Adigüzel U, Sari A, Ozmen C, Oz O. Intravitreal triamcinolone acetonide treatment for serpiginous choroiditis. *Ocul Immunol Inflamm*. 2006; 14(6):375–8.
16. Sahin OG. Long-term cyclophosphamide treatment in a case with serpiginous choroiditis. *Case Report Ophthalmol*. 2010; 1(2):71–6.
17. Seth RK, Gaudio PA. Treatment of serpiginous choroiditis with intravitreal fluocinolone acetonide implant. *Ocul Immunol Inflamm*. 2008; 16(3):103–5.
18. Sobaci G, Bayraktar Z, Bayer A. Interferon alpha-2a treatment for serpiginous choroiditis. *Ocul Immunol Inflamm*. 2005; 13(1):59–66.
19. Song MH, Roh YJ. Intravitreal ranibizumab for choroidal neovascularisation in serpiginous choroiditis. *Eye (Lond)*. 2009; 23(9):1873–5.
20. Vianna RN, Ozdal PC, Deschênes J, Burnier MN Jr. Combination of azathioprine and corticosteroids in the treatment of serpiginous choroiditis. *Can J Ophthalmol*. 2006; 41(2):183–9.
21. Wadhwa N, Garg SP, Mehrotra A. Prospective evaluation of intravitreal triamcinolone acetonide in serpiginous choroiditis. *Ophthalmologica*. 2010; 224(3):183–7.
22. Gupta V, Agarwal A, Gupta A et al (2002) Clinical characteristics of serpiginous choroidopathy in North India. *Am J Ophthalmol* 134:47–56
23. Gupta V, Gupta A, Rao NA (2007) Intraocular tuberculosis- an update. *Surv Ophthalmol* 52(6):561–587
24. Thomas S, Wiselka M, Dhar J, Bibby K (2006) Syphilis presenting as acute multifocal retinochoroiditis. *J R Soc Med* 99:371–372
25. Rodman J, Pizzimenti J (2011) Serpiginous choroiditis in a herpes-positive patient. *Optom Vis Sci* 88:776–780
26. Priya K, Madhavan HN, Reiser BJ et al (2002) Association of herpes-viruses in the aqueous humor of patients with serpiginous choroiditis: a polymerase chain reaction-based study. *Ocul Immunol Inflamm* 10:253–261
27. Mahendradas P, Kamath G, Mahalakshmi B et al (2007) Serpiginous choroiditis-like picture due to ocular toxoplasmosis. *Ocul Immunol Inflamm* 15:127–130
28. Pisa D, Ramos M, Garcia P et al (2008) Fungal infection in patients with serpiginous choroiditis or acute zonal occult outer retinopathy. *J Clin Microbiol* 41:130–135
29. Portero A, Careno E, Real LA, Villaron S, Herreras JM (2012) Infectious non-tuberculous serpiginous choroiditis. *Arch Ophthalmol* 130:1207–1208
30. Providência J, Fonseca C, Henriques F, Proença R. Serpiginous choroiditis presenting after SARS-CoV-2 infection: A new immunological trigger? *Eur J Ophthalmol*. 2022 Jan;32(1):NP97-NP101.
31. Gupta V, Gupta A, Arora S, Bambery P, Dogra MR, Agarwal A, et al. Presumed tubercular serpiginous-like choroiditis: Clinical presentations and management. *Ophthalmology* 2003;110:1744-9.
32. Bansal R, Gupta A, Gupta V, Dogra MR, Sharma A, Bambery P, et al. Tubercular serpiginous-like choroiditis presenting as multifocal serpiginoid choroiditis. *Ophthalmology* 2012;119:2334-42.
33. Jones NP. The Manchester uveitis clinic: The first 3000 patients – epidemiology and casemix. *Ocul Immunol Inflamm* 2015;23:118-26.
34. Fanlo P, Heras H, Pérez D, Tiberio G, Espinosa G, Adan A, et al. Profile of patients with uveitis referred to a multidisciplinary unit in Northern Spain. *Arch Soc Esp Oftalmol* 2017;92:202-9.
35. Jakob E, Reuland MS, Mackensen F, Harsch N, Fleckenstein M, Lorenz HM, et al. Uveitis subtypes in a German interdisciplinary uveitis center – Analysis of 1916 patients. *J Rheumatol* 2009;36:127-36.
36. Ohguro N, Sonoda KH, Takeuchi M, Matsumura M, Mochizuki M. The 2009 prospective multi-center epidemiologic survey of uveitis in Japan. *Jpn J Ophthalmol* 2012;56:432-5.
37. Rathinam SR, Namperumalsamy P. Global variation and pattern changes in epidemiology of uveitis. *Indian J Ophthalmol* 2007;55:173-83.
38. Rahman Z, Ahsan Z, Rahman NA, Dutta Majumder P. Pattern of uveitis in a referral hospital in Bangladesh. *Ocul Immunol Inflamm* 2018;26:893-6.
39. Llorenç V, Mesquida M, Sainz de la Maza M, Keller J, Molins B, Espinosa G, et al. Epidemiology of uveitis in a Western urban multiethnic population. The challenge of globalization. *Acta Ophthalmol* 2015;93:561-7.
40. Biswas J, Narain S, Das D, Ganesh SK. Pattern of uveitis in a referral uveitis clinic in India. *Int Ophthalmol* 1996;20:223-8.
41. Pathanapitoon K, Kunavisarut P, Ausayakhun S, Sirirungsri W, Rothova A. Uveitis in a tertiary ophthalmology centre in Thailand. *Br J Ophthalmol* 2008;92:474-8.

42. Sittivarakul W, Bhurayanontachai P, Ratanasukon M. Pattern of uveitis in a university-based referral center in Southern Thailand. *Ocul Immunol Inflamm* 2013;21:53-60.
43. Das D, Bhattacharjee H, Bhattacharyya PK, Jain L, Panicker MJ, Das K, et al. Pattern of uveitis in North East India: A tertiary eye care center study. *Indian J Ophthalmol* 2009;57:144-6.
44. Singh R, Gupta V, Gupta A. Pattern of uveitis in a referral eye clinic in North India. *Indian J Ophthalmol* 2004;52:121-5.
45. Manandhar A. Patterns of uveitis and scleritis in Nepal: A Tertiary referral center study. *Ocul Immunol Inflamm* 2017;25:S54-S62.
46. Siak J, Kumaradas M, Chee SP. The pattern of uveitis in Sri Lanka. *Ocul Immunol Inflamm* 2017;25:S63-S68.
47. Bansal R, Gupta A, Gupta V, et al (2008) Role of anti-tubercular therapy in uveitis with latent/manifest tuberculosis. *Am J Ophthalmol* 146:772-779
48. Oruc S, Kaplan AD, Galen M, Kaplan HJ. Uveitis referral pattern in a Midwest university eye center. *Ocul Immunol Inflamm* 2003;11:287-98.
49. Baarsma GS, Deutman AF. Serpiginous (geographic) choroiditis. *Doc Ophthalmol Adv Ophthalmol* 1976;40:269-85.
50. Hayreh SS, Baines JA. Occlusion of the posterior ciliary artery. II. Chorio-retinal lesions. *Br J Ophthalmol* 1972;56:736-53.
51. King DG, Grizzard WS, Sever RJ, Espinoza L. Serpiginous choroidopathy associated with elevated factor VIII-von Willebrand factor antigen. *Retina* 1990;10:97-101.
52. Wu JS, Lewis H, Fine SL, Grover DA, Green WR. Clinicopathologic findings in a patient with serpiginous choroiditis and treated choroidal neovascularization. *Retina* 1989;9:292-301.
53. Bansal R, Gupta V. Tubercular serpiginous choroiditis. *J Ophthalmic Inflamm Infect*. 2022 Nov 9;12(1):37.
54. Akpek EK, Ilhan-Sarac O. New treatments for serpiginous choroiditis. *Curr Opin Ophthalmol*. 2003; 14(3):128-31.
55. Hyvarinen L, Maumenee AE, George T, Weinstein GW. Fluorescein angiography of the choriocapillaris. *Am J Ophthalmol*. 1969; 67(5):647-66.
56. Maumenee AE. Clinical entities in "uveitis". An approach to the study of intraocular inflammation. *Am J Ophthalmol*. 1970; 69(1):1-27.
57. Laatikainen L, Erkkilä H. A follow-up study on serpiginous choroiditis. *Acta Ophthalmol (Copenh)*. 1981; 59(5):707-18.
58. Franceschetti A. A curious affection of the fundus oculi: helicoid peripapillar chorioretinal degeneration. Its relation to pigmentary paravenous chorioretinal degeneration. *Doc Ophthalmol*. 1962; 16:81-110.
59. Laatikainen L, Erkkilä H. Serpiginous choroiditis. *Br J Ophthalmol*. 1974; 58(9):777-83.
60. Chisholm IH, Gass JD, Hutton WL. The late stage of serpiginous (geographic) choroiditis. *Am J Ophthalmol*. 1976; 82(3):343-51.
61. Bouchenaki N, Cimino L, Auer C, et al. Assessment and classification of choroidal vasculitis in posterior uveitis using indocyanine green angiography. *Klin Monbl Augenheilkd*. 2002; 219(4): 243-9.
62. Baglivo E, Boudjema S, Pieh C, et al. Vascular occlusion in serpiginous choroidopathy. *Br J Ophthalmol*. 2005; 89(3):387-8.
63. Erkkilä H, Laatikainen L, Jokinen E. Immunological studies on serpiginous choroiditis. *Graefes Arch Clin Exp Ophthalmol*. 1982; 219(3):131-4.
64. Mulder CJ, Pena AS, Jansen J, Oosterhuis JA. Celiac disease and geographic (serpiginous) choroidopathy with occurrence of thrombocytopenic purpura. *Arch Intern Med*. 1983; 143(4): 842.
65. Broekhuysen RM, van Herck M, Pinckers AJ, et al. Immune responsiveness to retinal S-antigen and opsin in serpiginous choroiditis and other retinal diseases. *Doc Ophthalmol*. 1988; 69(1):83-93.
66. Wenick AS, Odel JG. Serpiginous choroiditis in any other name. *Arch Ophthalmol*. 2005; 123:1616-8.
67. Gass JD, Braunstein RA, Chenoweth RG. Acute syphilitic posterior placoid chorioretinitis. *Ophthalmology*. 1990 Oct; 97(10):1288-97. [PubMed: 2243679]
68. Hooper PL, Kaplan HJ. Triple agent immunosuppression in serpiginous choroiditis. *Ophthalmology*. 1991; 98(6):944-51. discussion 951-2.
69. Mackensen F, Becker MD, Wiehler U, Max R, Dalpke A, Zimmermann S, et al. QuantiFERON-TB-gold – A new test strengthening long-suspected tuberculous involvement in serpiginous-like choroiditis. *Am J Ophthalmol* 2008;146:761-6.
70. Gupta A, Bansal R, Gupta V, Sharma A, Bamberg P. Ocular signs predictive of tubercular uveitis. *Am J Ophthalmol* 2010;149:562-70.

71. Forrester JV, Kuffova L, Dick AD (2018) Autoimmunity, autoinflammation and infection in uveitis. *Am J Ophthalmol* 189:77–85
72. Tripathi P, Saxena S, Yadav VS, Naik S, Singh VK (2004) Human S-antigen: peptide determinant recognition in uveitis patients. *Exp Mol Pathol* 76:122–128
73. de Smet MD, Bitar G, Mainigi S, Nussenblatt RB (2001) Human S-anti- gen determinant recognition in uveitis. *Invest Ophthalmol Vis Sci* 42:3233–3238
74. Tagirasa R, Parmar S, Barik MR, Devadas S, Basu S (2017) Autoreactive T cells in immunopathogenesis of TB-associated uveitis. *Invest Ophthalmol Vis Sci* 58:5682–5691
75. Abu El-Asrar AM, Struyf S, Kangave D et al (2012) Cytokine and CXCL chemokine expression patterns in aqueous humor of patients with presumed tuberculous uveitis. *Cytokine* 59:377–381
76. Ang M, Cheung G, Vania M et al (2012) Aqueous cytokine and chemokine analysis in uveitis associated with tuberculosis. *Mol Vis* 18:565–573
77. Sharma RK, Gupta A, Kamal S et al (2016) Role of regulatory T cells in tubercular uveitis. *Ocul Immunol Inflamm* 26:27–36
78. Agarwal A, Deokar A, Sharma R, Singh N, Aggarwal K, Sharma SP, Singh R, Sharma A, Sharma K, Agrawal R, Bansal R, Gupta V (2019) Longitudinal analysis of serum cytokine profile among patients with tubercular multifocal serpiginoid choroiditis: a pilot study. *Eye* 33:129–135
79. Priya K, Madhavan HN, Reiser BJ, et al. Association of herpesviruses in the aqueous humor of patients with serpiginous choroiditis: a polymerase chain reaction-based study. *Ocul Immunol Inflamm*. 2002; 10(4):247–61.
80. Rodman J, Pizzimenti J. Serpiginous choroiditis in a herpes-positive patient. *Optom Vis Sci*. 2011; 88(6):776–80.
81. Erkkilä H, Laatikainen L, Jokinen E. Immunological studies on serpiginous choroiditis. *Graefes Arch Clin Exp Ophthalmol*. 1982; 219(3):131–4.
82. Sahin OG. Long-term cyclophosphamide treatment in a case with serpiginous choroiditis. *Case Report Ophthalmol*. 2010; 1(2):71–6. Rao NA, Saraswathy S, Smith RE (2006) Tuberculous uveitis: distribution of mycobacterium tuberculosis in the retinal pigment epithelium. *Arch Ophthalmol* 124:1777–1779
83. Bansal R, Sharma K, Gupta A, Sharma A, Singh MP, Gupta V, Mulkutkar S, Dogra M, Dogra MR, Kamal S, Sharma SP, Fiorella PD (2015) Detection of mycobacterium tuberculosis genome in vitreous fluid of eyes with multifocal serpiginoid choroiditis. *Ophthalmology*. 122(4):840–850
84. Kawali A, Emerson GG, Naik NK, Sharma K, Mahendradas P, Rao NA et al (2018) Clinicopathologic features of tuberculous serpiginous-like choroiditis. *JAMA Ophthalmol* 136:219–221
85. Carr RE, Noble KG. Disorders of the fundus 8. Geographic (serpiginous) choroidopathy. *Ophthalmology*. 1980; 87(10):1065–8.
86. Gass, JDM. Stereoscopic Atlas of Macular Diseases: A Funduscopy and Angiographic Presentation. St Louis: CV Mosby Co; 1997. p. 158-165.
87. Nazari Khanamiri H, Rao NA. Serpiginous choroiditis and infectious multifocal serpiginoid choroiditis. *Surv Ophthalmol* 2013;58:203-32.
88. Mansour AM, Jampol LM, Packo KH, Hrisomalos NF. Macular serpiginous choroiditis. *Retina* 1988;8:125-31.
89. Vasconcelos-Santos DV, Rao PK, Davies JB, Sohn EH, Rao NA. Clinical features of tuberculous serpiginouslike choroiditis in contrast to classic serpiginous choroiditis. *Arch Ophthalmol* 2010;128:853-8.
90. Abrez H, Biswas J, Sudharshan S. Clinical profile, treatment, and visual outcome of serpiginous choroiditis. *Ocul Immunol Inflamm*. 2007; 15(4):325–35.
91. Abu el-Asrar AM. Serpiginous (geographical) choroiditis. *Int Ophthalmol Clin*. 1995; 35(2):87–91.
92. Hamilton AM, Bird AC. Geographical choroidopathy. *Br J Ophthalmol*. 1974; 58(9):784–97.
93. Hardy RA, Schatz H. Macular geographic helicoid choroidopathy. *Arch Ophthalmol*. 1987; 105(9): 1237–42.
94. Weiss H, Annesley WH, Shields JA, et al. The clinical course of serpiginous choroidopathy. *Am J Ophthalmol*. 1979; 87:133–42.
95. Sahu DK, Rawoof A, Sujatha B. Macular serpiginous choroiditis. *Indian J Ophthalmol*. 2002; 50(3):189–96.
96. Aggarwal K, Agarwal A, Deokar A, Singh R, Bansal R, Sharma A, Sharma K, Dogra MR, Gupta V (2019) Ultra-wide field imaging in paradoxical worsening of tubercular multifocal Serpiginoid choroiditis after the initiation of anti-tubercular therapy. *Ocul Immunol Inflamm* 27(3):365–370
97. Aggarwal K, Mulkutkar S, Mahajan S, Singh R, Sharma A, Bansal R, Gupta V, Gupta A (2016 Dec) Role of ultra-wide field imaging in the Management of Tubercular Posterior Uveitis. *Ocul Immunol Inflamm* 24(6):631–636

98. Giovannini A, Mariotti C, Ripa E et al (1996) Indocyanine green angiographic findings in serpiginous choroidopathy. *Br J Ophthalmol* 80:436–440
99. Giovannini A, Ripa E, Scassellati-Sforzolini B et al (1996) Indocyanine green angiography in serpiginous choroidopathy. *Eur J Ophthalmol* 6:299–306
100. Gupta A, Bansal R, Gupta V, Sharma A (2012) Fundus autofluorescence in serpiginous-like choroiditis. *Retina* 32:814–825
101. Bansal R, Kulkarni P, Gupta A et al (2011) High-resolution spectral domain optical coherence tomography and fundus autofluorescence correlation in tubercular serpiginous-like choroiditis. *J Ophthalmic Inflamm Infect* 1:157–163
102. van Velthoven ME, Ongkosuwito JV, Verbraak FD, Schlingemann RO, de Smet MD. Combined en-face optical coherence tomography and confocal ophthalmoscopy findings in active multifocal and serpiginous chorioretinitis. *Am J Ophthalmol* 2006;141:972-5.
103. Rifkin LM, Munk MR, Baddar D, Goldstein DA. A new OCT finding in tuberculous serpiginous-like choroidopathy. *Ocul Immunol Inflamm* 2015;23:53-8.
104. Agarwal A, Agrawal R, Khandelwal N, Invernizzi A, Aggarwal K, Sharma A, et al. Choroidal structural changes in tubercular multifocal serpiginoid choroiditis. *Ocul Immunol Inflamm* 2018;26:838-44.
105. Ahn SJ, Park SH, Lee BR. Multimodal imaging including optical coherence tomography angiography in serpiginous choroiditis. *Ocul Immunol Inflamm* 2017;25:287-91.
106. El Ameen A, Herbort CP Jr. Serpiginous choroiditis imaged by optical coherence tomography angiography. *Retin Cases Brief Rep* 2018;12:279-85.
107. Mandadi SK, Agarwal A, Aggarwal K, Moharana B, Singh R, Sharma A, et al. Novel findings on optical coherence tomography angiography in patients with tubercular serpiginous-like choroiditis. *Retina* 2017;37:1647-59.
108. Magesan K, Sachidanandam R, Verma A, Biswas J. Retino-choroidal evaluation of the macular region in eyes with tubercular serpiginous-like choroiditis using swept-source optical coherence tomography angiography. *Int Ophthalmol*. 2022 Sep;42(9):2651-2664.
109. Baarsma GS, Deutman AF. Serpiginous (geographic) choroiditis. *Doc Ophthalmol*. 1976; 40(2): 269–85. [PubMed: 1269358]
110. Pilotto E, Vujosevic S, Grgic VA, et al. Retinal function in patients with serpiginous choroiditis: a microperimetry study. *Graefes Arch Clin Exp Ophthalmol*. 2010; 248(9):1331–7.
111. Arantes TE, Matos K, Garcia CR, et al. Fundus autofluorescence and spectral domain optical coherence tomography in recurrent serpiginous choroiditis: case report. *Ocul Immunol Inflamm*. 2011; 19(1):39–41.
112. Kuo IC, Cunningham ET Jr. Ocular neovascularization in patients with uveitis. *Int Ophthalmol Clin* 2000;40:111-26.
113. Bansal R, Bansal P, Gupta A, Gupta V, Dogra MR, Singh R, et al. Diagnostic challenges in inflammatory choroidal neovascular membranes. *Ocul Immunol Inflamm* 2017;25:554-62.
114. Laatikainen L, Erkkilä H. Subretinal and disc neovascularisation in serpiginous choroiditis. *Br J Ophthalmol*. 1982; 66(5):326–31.
115. Wojno T, Meredith TA. Unusual findings in serpiginous choroiditis. *Am J Ophthalmol*. 1982; 94(5):650–5.
116. Christmas NJ, Oh KT, Oh DM, Folk JC. Long-term follow-up of patients with serpiginous choroiditis. *Retina* 2002;22:550-6.
117. Hooper PL, Kaplan HJ. Triple agent immunosuppression in serpiginous choroiditis. *Ophthalmology* 1991;98:944-51.
118. Vonmoos F, Messerli J, Moser HR, Prünke C, Flammer J, Haefliger IO, et al. Immunosuppressive therapy in serpiginous choroiditis – Case report and brief review of the literature. *Klin Monbl Augenheilkd* 2001;218:394-7.
119. Munteanu G, Munteanu M, Zologl. Serpiginous choroiditis – Clinical study. *Oftalmologia* 2001;52:72-80.
120. Venkatesh P, Tayade A, Gogia V, Gupta S, Shah BM, Vohra R. Short-term intensive immunosuppression: A randomized, three-arm study of intravenous pulse methylprednisolone and cyclophosphamide in macular serpiginous choroiditis. *Ocul Immunol Inflamm* 2018;26:469-76.
121. Llorenç V, Molins B, Rey A, Mesquida M, Adán A. Adalimumab in serpiginous choroiditis. *Ocul Immunol Inflamm* 2013;21:237-40.
122. Seve P, Mennesson E, Grange JD, Broussolle C, Kodjikian L. Infliximab in serpiginous choroiditis. *Acta Ophthalmol* 2010;88:e342-3.

123. Chinchurreta Capote A, Requena Jiménez JM, Lorenzo Soto M, Romero Gómez C, García de Lucas MD. Effectiveness of adalimumab for refractory serpiginous choroiditis. *Ocul Immunol Inflamm* 2014;22:405-8.
124. Pathengay A. Intravitreal triamcinolone acetonide in serpiginous choroidopathy. *Indian J Ophthalmol* 2005;53:77-9.
125. Julian K, Langner-Wegscheider BJ, Haas A, De Smet MD. Intravitreal methotrexate in the management of presumed tuberculous serpiginous-like choroiditis. *Retina* 2013;33:1943-8.
126. Saatci AO, Ayhan Z, Engin Durmaz C, Takes O. Simultaneous single dexamethasone implant and ranibizumab injection in a case with active serpiginous choroiditis and choroidal neovascular membrane. *Case Rep Ophthalmol* 2015;6:408-14.
127. Gupta V, Bansal R, Gupta A. Continuous progression of tubercular serpiginous-like choroiditis after initiating antituberculosis treatment. *Am J Ophthalmol* 2011;152:857-63.
128. Cheung CM, Chee SP. Jarisch-herxheimer reaction: Paradoxical worsening of tuberculosis chorioretinitis following initiation of antituberculous therapy. *Eye (Lond)* 2009;23:1472-3.
129. Hawkey CR, Yap T, Perira J, et al. Characterization and management of paradoxical upgrading reactions in HIV uninfected patients with lymph node tuberculosis. *Clin Infect Dis* 2005;40(9):1368 –1371
130. Holzheimer RG. Antibiotic induced endotoxin release and clinical sepsis: a review. *J Chemother* 2001;1(1):159 –172
131. Kumar MV, Nagineni CN, Chin MS, Hooks JJ, Detrick B. Innate immunity in the retina: Toll-like receptor (TLR) signaling in human retinal pigment epithelial cells. *J Neuroimmunol*. 2004 Aug;153(1-2):7-15.
132. McAllister WA, Thompson PJ, Al-Habet SM, Rogers HJ. Rifampicin reduces effectiveness and bioavailability of prednisolone. *Br Med J (Clin Res Ed)*. 1983 Mar 19;286(6369):923-5.
133. Agarwal A, Marchese A, Rabiolo A, Agrawal R, Bansal R, Gupta V. Clinical and Imaging Factors Associated With the Outcomes of Tubercular Serpiginous-like Choroiditis. *Am J Ophthalmol*. 2020 Dec;220:160-169.
134. Mishra SB, Saoji K, Pathengay A. Dual lesion margins on fundus autofluorescence associated with paradoxical worsening following treatment for tubercular serpiginous-like choroiditis. *Indian J Ophthalmol*. 2020 Mar;68(3):536-538.
135. Konana VK, Bhagya M, Babu K. Double-Layer Sign: A New OCT Finding in Active Tubercular Serpiginous-like Choroiditis to Monitor Activity. *Ophthalmol Retina*. 2020 Mar;4(3):336-342.
136. Jain L, Panda KG, Basu S. Clinical outcomes of adjunctive sustained-release intravitreal dexamethasone implants in tuberculosis-associated multifocal serpigenoid choroiditis. *Ocul Immunol Inflamm* 2018;26:877-83.
137. Agarwal A, Handa S, Aggarwal K, Sharma M, Singh R, Sharma A, et al. The role of dexamethasone implant in the management of tubercular uveitis. *Ocul Immunol Inflamm* 2018;26:884-92.
138. Fonollosa A, Valsero S, Artaraz J, Ruiz-Arruzal. Dexamethasone intravitreal implants in the management of tubercular multifocal serpiginoid choroiditis. *J Ophthalmic Inflamm Infect*. 2016 Dec;6(1):31.



## Case Contest Winner

### Boundless Tale of White Dot Syndrome in a Child



**Dr. Lekha T**, DNB, FRCS  
Consultant, Giridhar Eye Institute, Kochi  
[lekhat31@gmail.com](mailto:lekhat31@gmail.com)

#### Introduction

White dot syndrome (WDS) is a group of posterior uveitis disorders manifesting as whitish-yellow lesions affecting the outer retinal layers, retinal pigment epithelium (RPE) and/or choroid. Some of the common WDS includes acute posterior multifocal placoid pigment epitheliopathy (APMPPE), serpiginous choroiditis, acute zonal occult outer retinopathy (AZOOR), multiple evanescent white dot syndrome (MEWDS), punctate inner choroidopathy (PIC) etc. Given their overlapping clinical and imaging features, WDS and their mimickers represent a diagnostic challenge for clinicians. Multimodal imaging (MMI) utilizing optical coherence tomography (OCT), fluorescein angiography (FA), indocyanine green angiography (ICGA), and fundus autofluorescence (FAF) are important in precise anatomic localization and better characterization of the lesions. The exact etiology of many of these disorders remains unknown, but mostly considered as inflammatory and noninfectious, although an underlying infectious cause should always be ruled out

We describe the 7 years follow up data of a young boy who initially presented with unilateral defective vision following an attack of viral fever. Fundus findings and MMI were suggestive of MEWDS with some lesions resembling multifocal choroiditis (MFC). He responded well to oral steroids with good visual recovery, but recurred few weeks later requiring another course of steroids. He had 2 more recurrences with typical MEWDS findings which resolved without any systemic therapy. There have been few case reports of MEWDS as primary diagnosis but later demonstrating typical findings of other disease entities like MFC and AZOOR which further complicate our understanding of MEWDS (1). In our case the initial presentation was atypical with features partly like MFC and later on presented with the typical pattern of MEWDS. MMI, especially FAF and OCT greatly helped in the diagnosis and monitoring of our patient. FAF showed hyper autofluorescence (AF) that is believed to be due to inflammation causing increased phagocytosis of the photoreceptor outer

segments and increased production of lipofuscin. WDS affects the outer segment of the photoreceptors causing loss of the ellipsoid zone (EZ) which recovers in most cases and was demonstrated in our case too.

### Case report

In August 2017, a 14 years old boy presented to our OPD with sudden onset of painless loss of vision in the right eye (RE), 3 weeks after an attack of viral fever. There was no history of any systemic illness. Examination showed best corrected visual acuity (BCVA) of 6/24 in RE and 6/9 in the left eye (LE). Color vision, pupillary evaluation and anterior segment examination were unremarkable. Dilated fundus examination revealed discrete, faint yellowish-white deep lesions in the peripapillary region extending along the superior and inferior arcade in RE. Few discrete prominent lesions were noted nasally. There was no granularity at the fovea and optic disc was hyperemic (Figure 1a). LE examination was normal. FAF (Figure 1b) showed a diffuse hyper AF area concentrated at the peripapillary region and along the superior and inferior temporal arcades. OCT (Figure 1c) demonstrated subtle disruption of the EZ corresponding to the white lesions seen clinically, suggesting a diagnosis of MEWDS. He was treated with oral steroids which resulted in complete resolution of the lesions as shown in Figure 2. Vision in the RE improved to 6/9

Within a month of stopping steroid, he presented with sudden drop in vision in the RE. BCVA in the RE had decreased to 6/18. There was recurrence of the lesions in the RE which was delineated well as hyper AF lesions on FAF and corresponding EZ disruption on OCT (Figure 3a). Lesions resolved after another course of oral steroids and he remained stable (Figure 3b).

Two years later, he presented with mild blurring of vision in RE. Fundus appeared normal (Figure 4a) but scattered lesions were seen on FAF and OCT (Figure 4b, d). He was treated with topical steroids. Follow up FAF and OCT (Figure 4 c,e) confirmed disappearance of the lesions

He came back recently in October 2023 with complaints of defective vision in OD noticed 2 weeks after an episode of viral fever. Fundus examination revealed whitish lesions, more evident nasally. MMI (Figure 5) showed multiple hypo fluorescent lesions, better delineated on ICGA with corresponding EZ disruption on OCT. Laboratory tests including CBC, C-RP, ESR, S. ACE, and Quantiferon TB gold test were all negative. HRCT chest was normal. However, Mantoux was positive with 25mm induration, for which he was advised pulmonology consultation. He came back only 3 weeks later with the pulmonologist's opinion to start systemic steroids under cover of ATT. As the lesions had resolved by then, we decided to observe and repeat imaging after 3 months. He was reevaluated in March 2024 and repeat MMI (Figure 6) showed complete disappearance of lesions on ICGA and restoration of EZ on OCT. He is kept under follow up.

### Discussion

MEWDS is a rare posterior uveitis with an annual incidence of 0.22 per 100,000. It is mostly seen in young woman and presents with characteristic white spots in the fundus with other commonly documented findings on MMI (2). The disease often presents with a viral prodrome followed by acute visual loss and good recovery without treatment (2, 3, 4)

This case demonstrates some atypical features associated with MEWDS. On initial presentation, apart from the subtle white lesions in peripapillary region, scattered large yellow white lesions were noted in the mid periphery, suggestive of MEWDS overlapping with MFC. Kang et al have reported on clinical spectrum of MEWDS overlapping with multifocal choroiditis (4). In their 10-year retrospective review of 34 cases, 21% had combined MFC, either in the same eye or in the fellow eye, suggesting a connection between the 2 conditions. Atypical cases had a thicker choroid which was not observed in our patient. The authors hypothesize that a silent choroidal inflammation may trigger a deeper choroidal inflammation or an outer retinal inflammatory syndrome.

Case series on atypical MEWDS without white dots have been documented (5). As the name indicates, white dots are evanescent and may not be present when patient consults after some delay. All three patients in that study presented with classic MEWDS symptoms, had foveal granularity, mild disc swelling and focal EZ disruption on OCT. However, no characteristic lesions were seen on FA, ICGA and FAF. In our patient, during the third recurrence, even though our patient complaint of blurred vision, there was no white lesions noted on fundus examination. However, FAF picked up activity. This emphasize the importance of FAF and OCT which are noninvasive and extremely useful in the diagnosis and follow up of eyes with minimal activity.

Our patient had four episodes of recurrence in seven years. Though we treated him with oral steroid initially, later recurrences were just observed and the disease resolved without developing any complications. Chronic recurrent MEWDS case series has been reported in the past (6). Classic clinical findings noted in their study was granularity in the macula, white dots, and optic disc changes. Despite the recurrences,

their patients still retained visual acuity of 20/20. Other authors have reported complications like chorioretinal scar and choroidal neovascularization in recurrent cases (7, 8, 9).

TST (tuberculin skin test) positivity does not distinguish between latent or active tuberculosis, but an induration of 15 mm or more is considered positive even with no risk factors for tuberculosis (10). A positive TST test should be followed by symptoms assessment, physical exam, and chest radiograph. In our case, even though Mantoux was highly positive, other investigations were negative. Pulmonologist opinion was obtained and was advised ATT only if systemic steroids were contemplated. Nicolau et al reported a case of presumed TB with MEWDS like presentation, treated and responded well with anti-tubercular therapy (11). The presence of atypical WDS findings in patients should raise the possibility of undiagnosed inflammatory, infectious or neoplastic disease. A possibility of TB cannot be excluded in our case and in future recurrences, treatment with ATT can be considered.

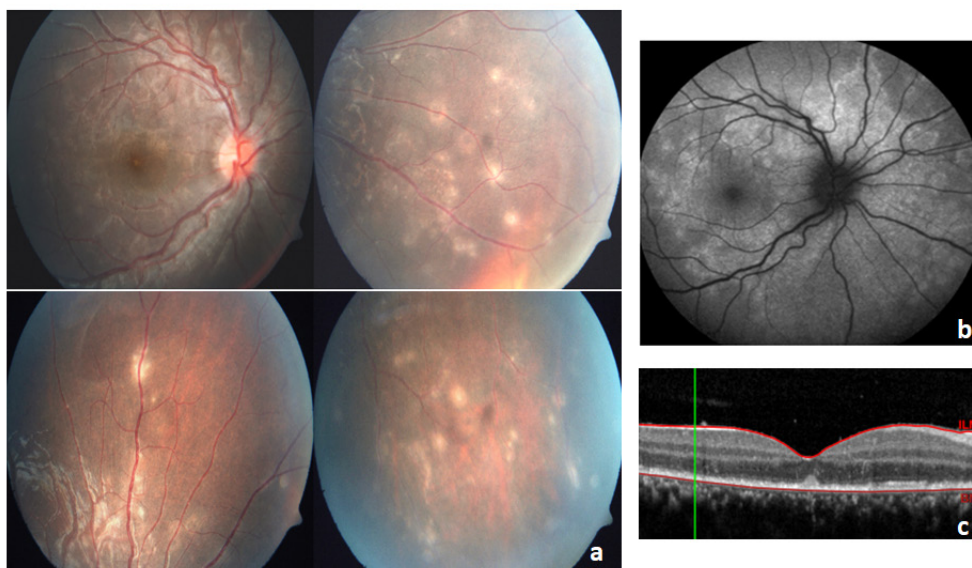


Figure 1. Multimodal imaging of right eye at presentation (a) Color fundus photo showing clear media with subtle white lesions along the arcades. The lesions in nasal and superior mid periphery are prominent as seen in Multifocal Choroiditis. (b) FAF showing hyper auto fluorescent lesions. (c) OCT showing hyper reflective foci in the outer retinal layer and hyperreflective dome-shaped lesion that extend into the ellipsoid zone. Cells in the posterior vitreous face can be noted

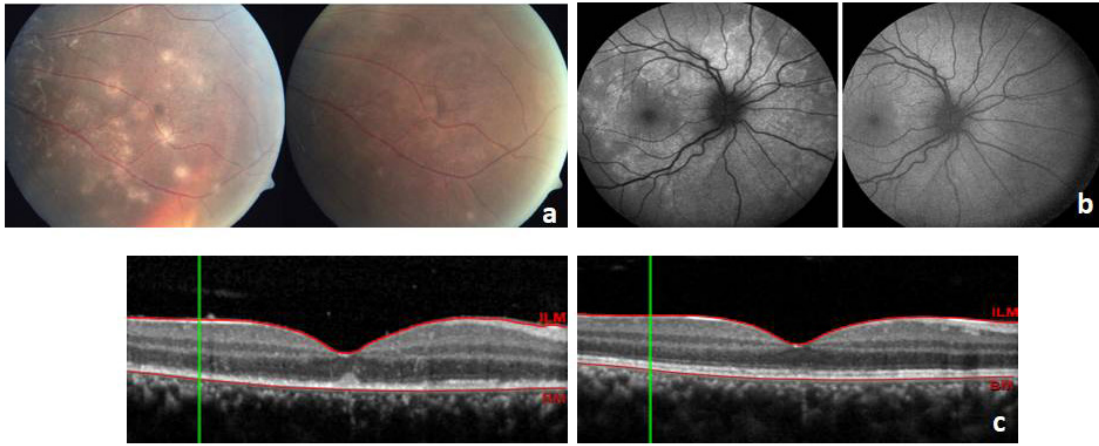


Figure 2: (a) Fundus photo showing the disappearance of lesion following steroid therapy. (b) FAF showing the disappearance of hyper fluorescence in the affected area. (c) OCT demonstrating normal outer retinal layers

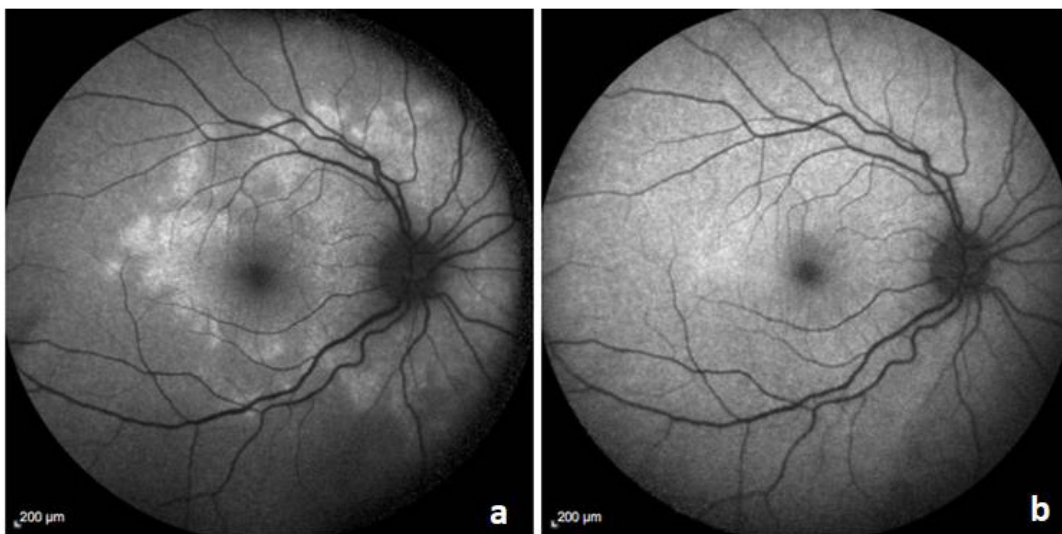


Figure 3: (a) Reappearance of lesion clearly seen on FAF following cessation of steroid therapy. (b) FAF showing a normal retina after retreatment with oral steroids

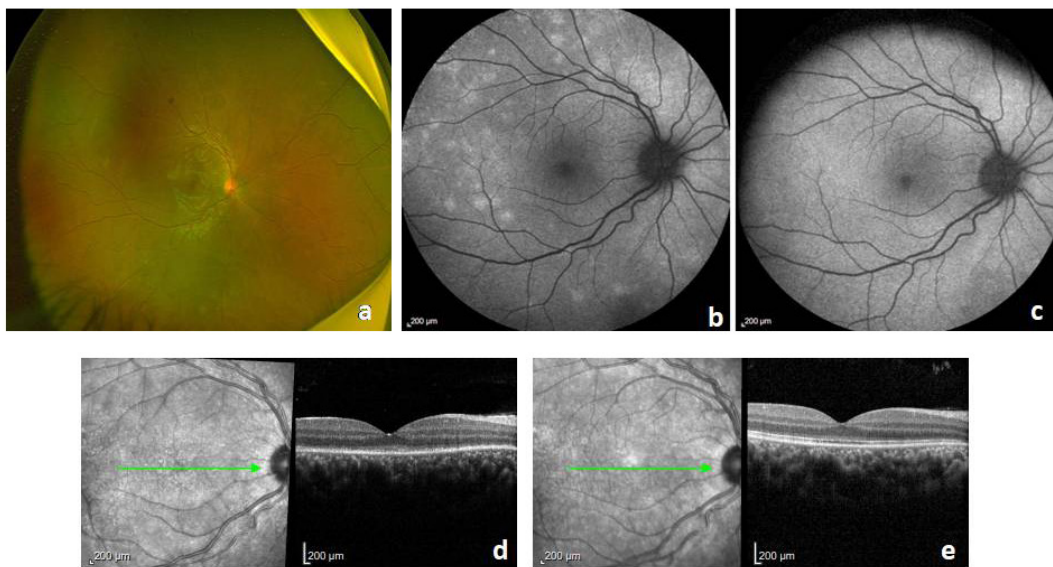


Figure 4: (a) Optos ultra wide field image of right eye appears normal. (b) FAF showing few scattered lesions in the posterior pole. (c) FAF showing disappearance of lesions with topical steroid. (d,e) Pre and post treatment OCT also shows resolution of activity.

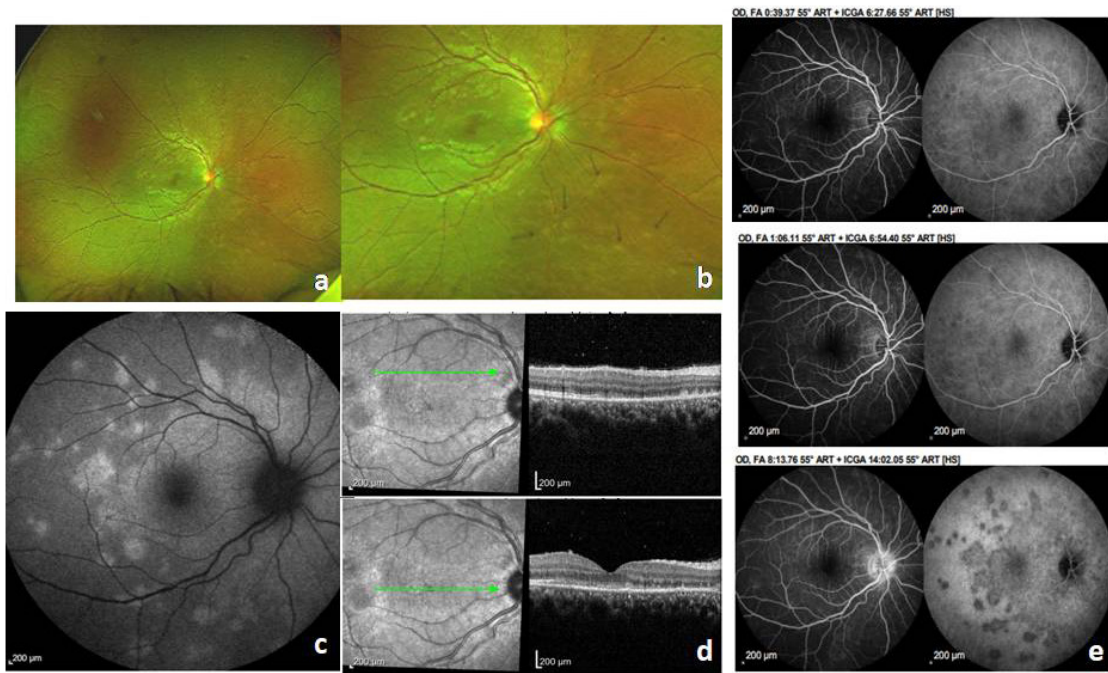


Figure 5: (a) Optos of right eye with multiple discrete faint white lesions, (b) lesions predominantly on the nasal retina (black arrows). (c) Pattern of distribution evident on FAF. (d) OCT sections passing through superior retina and fovea showing outer retinal hyper reflective lesions with EZ disruption (e) Early, mid and late phase images of FFA and ICGA showing lesions more prominent on ICGA than FFA which is suggestive of a choroidal involvement

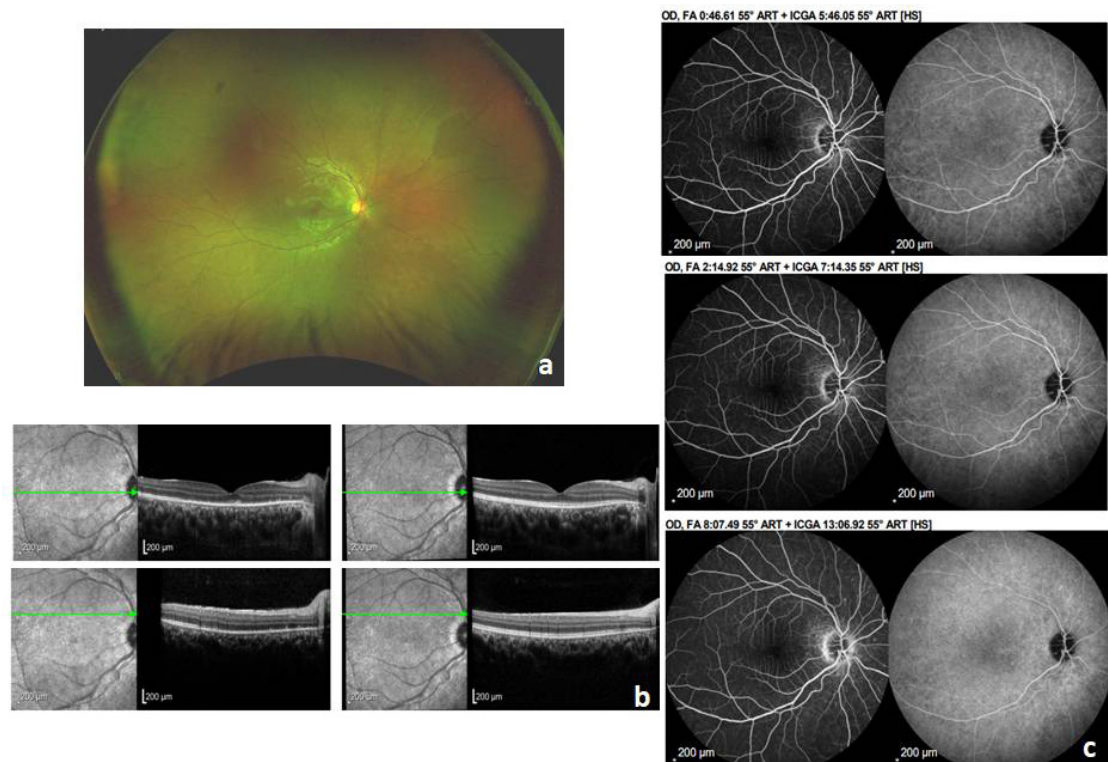


Figure 6: Follow up Optos, OCT, FFA and ICG demonstrating disappearance of all the lesions with no activity.

## References

1. Kang HG, Kim TY, Kim M, Byeon SH, Kim SS, Koh HJ, Lee SC, Lee CS. Expanding the Clinical Spectrum of Multiple Evanescent White Dot Syndrome with Overlapping Multifocal Choroiditis. *Ocul Immunol Inflamm*. 2022; 30:81-89
2. Tavallali A, Yannuzzi LA. MEWDS common cold of the retina. *J Ophthalmic Vis Res*. 2017; 12:132-134
3. Standardization of Uveitis Nomenclature SUN Working Group Classification criteria for multiple evanescent white dot syndrome. *Am J Ophthalmol*. 2021; 228: 198-204
4. Papasavvas I, Mantovani A, Tugal-Tutkun I, Herbert CP. Multiple evanescent white dot syndrome (MEWDS) update on practical appraisal, diagnosis and clinicopathology; a review and an alternative comprehensive perspective. *J Ophthalmic Inflamm Infect*. 2021; 11:45
5. Shelsta HN, Rao RR, Bhatt HK, Jampol LM. Atypical presentations of multiple evanescent white dot syndrome without white dots: a case series. *Retina*. 2011; 31:973-6.
6. Tsai L, Jampol LM, Pollock SC, Olk J. Chronic recurrent multiple evanescent white dot syndrome. *Retina*. 1994; 14(2):160-3.
7. Koziellec GF, Wyhinny GJ, Jampol LM. Evolution of distinct chorioretinal scars in recurrent MEWDS. *Retina*. 2001; 21(2):180-2.
8. Mathis T, Delaunay B, Cahuzac A, Vasseur V, Mauget-Fajèsse M, Kodjikian L. Choroidal neovascularisation triggered multiple evanescent white dot syndrome (MEWDS) in predisposed eyes. *Br J Ophthalmol*. 2018 Jul; 102(7):971-976.
9. Oh KT, Christmas NJ, Russell SR. Late recurrence and choroidal neovascularization in multiple evanescent white dot syndrome. *Retina*. 2001; 21(2):182-4.
10. Levine S, Fraulino D, Krupka P, Velamakanni S. Latent tuberculosis infection in the outpatient general medicine clinic: Efficacy of a nurse-run electronic directly observed treatment program. *Prev Med Rep*. 2023 Jul 16; 35: 102321.
11. Nicolau, Z.F.M., Araújo, D.L., Nakayama, L.F. et al. White dot syndrome in a patient with presumed ocular tuberculosis: a case report. *Int J Retin Vitr* 8, 25 (2022).

## APMPPE and Relentless Placoid: What's in a Name



**Dr. Anita Agarwal, MD**  
Vitreoretinal consultant  
West Coast Retina in San Francisco  
Adjoint Professor of Ophthalmology, Vanderbilt  
Eye Institute in Nashville, USA  
[anita.agarwal@vumc.org](mailto:anita.agarwal@vumc.org)



**Dr. Georgia Kaidonis Kamboj, MD, PhD**  
Vitreoretinal fellow,  
West Coast Retina in San Francisco, USA.

The first cases of Acute Posterior Multifocal Placoid Pigment Epitheliopathy (APMPPE) were described by Gass in 1968<sup>1</sup>. Each case had similar features; patients were young, with bilateral acutely decreased vision and yellow placoid lesions. The placoid lesions resolved spontaneously within one to two months, with clearing starting centrally within each lesion. Vision improved as the lesions resolved. He described characteristic findings on fluorescein angiography (FA), reporting that placoid lesions were hypofluorescent early with progressive staining. Following resolution of the lesions, FA revealed a mottled hyperfluorescence which he attributed to defects in the retinal pigment epithelium (RPE), and scattered non fluorescence due to pigment clumps. From this he deduced that the placoid lesions lie at the level of the RPE and superficial

choroid, thus naming the entity APMPPE. Gass hypothesized that the etiology of the RPE changes may be related to an acute inflammatory response in the setting of recent infection or toxic injury to the RPE and choroid. This was based on the transient nature of the lesions suggesting that a chronic progressive disease is less likely.

Understanding the pathophysiology of APMPPE has evolved with the advancement of imaging techniques. Ischemia of the inner choroid secondary to inflammation is one explanation for the natural history of this condition<sup>2</sup>. Indocyanine green (ICG) imaging of placoid lesions shows hypofluorescence suggesting choroidal hypoperfusion<sup>3,4</sup>. Optical Coherence Tomography Angiography (OCTA) shows progressive flow deficits at the level of the inner choroid consistent with reduced perfusion of the choriocapillaris<sup>5</sup>. Inner choroidal thickening

and infiltration can be appreciated on OCT in the acute phase, with subsequent resolution, further supporting a transient choroiditis with compression of the choriocapillaris from inflammatory infiltration of the superficial choroid. <sup>6</sup> In addition, thickening of the ellipsoid zone and hyperreflectivity of the outer nuclear layer is characteristic of acute placoid lesions on OCT, and suggests acute outer retinal inflammation <sup>2</sup>. Subretinal fluid is sometimes present and in extreme cases serous detachment and bacillary layer detachment can develop representing a more severe inflammatory response <sup>2</sup>. Distinct separation between photoreceptors and the RPE is seen early in the course of the lesions on OCT and can persist as the lesions heal <sup>7</sup>. Reconstitution of the choriocapillaris has recently been demonstrated with OCTA in patients with APMPE, suggesting that an acute, reversible insult to the choriocapillaris is responsible <sup>8</sup>. This is in line with Gass' original hypothesis.

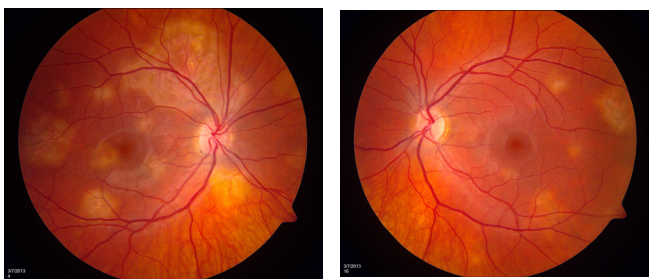

Figure 1 & 2. A 22-year-old female with bilateral creamy placoid lesions in the posterior pole 2-3 weeks post mild viral upper respiratory tract symptoms.

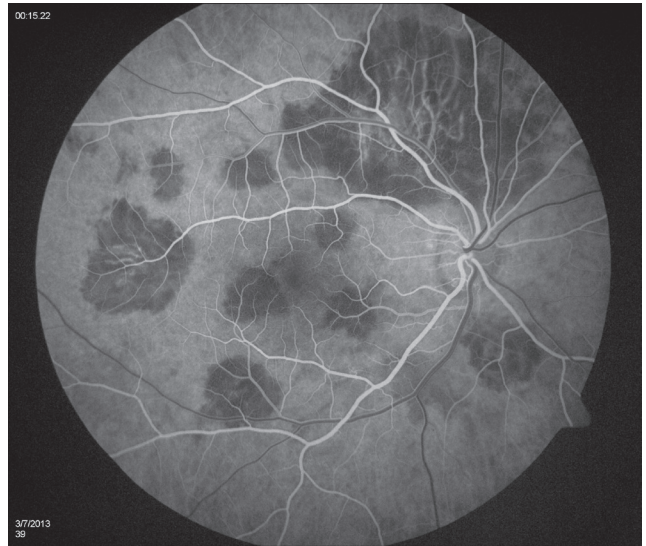

Figure 3. Right eye early phase FA shows hypofluorescence of the placoid lesions suggesting reduced flow in the choriocapillaris due to inflammatory cell infiltration of the superficial choroid and choriocapillaris.

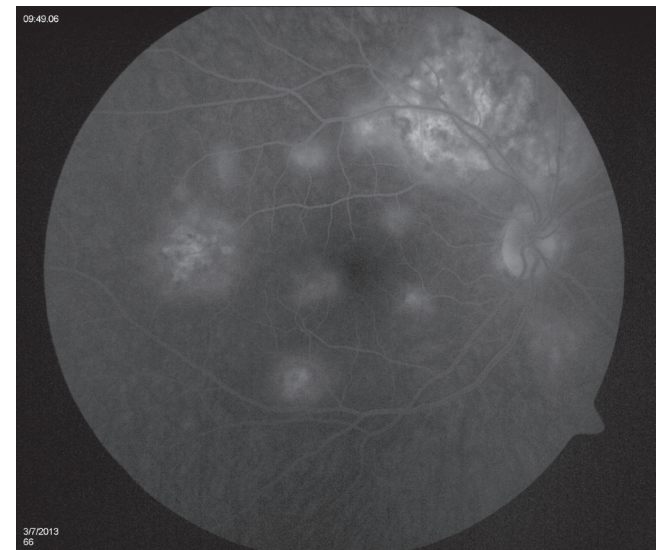

Figure 4. Late phase FA shows even hyperfluorescence of the placoid lesions in the right eye. The left eye showed similar features.

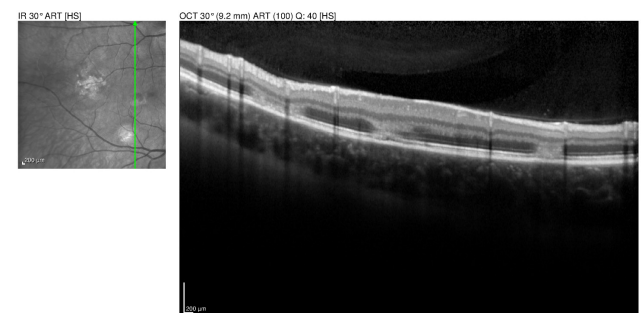


Figure 5. B scan OCT of the lesions in the right eye showing ground glass appearance of the underlying choriocapillaris and superficial choroid due to inflammatory infiltration with thickening of the RPE and hyperreflectivity of the outer nuclear layer and ellipsoid line from secondary inflammation of the adjacent structures.

Placoid lesions are observed in several disorders including persistent placoid maculopathy, serpiginous choroiditis, Tubercular serpiginous-like choroiditis and acute syphilitic posterior placoid chorioretinitis <sup>2</sup>. One of the features that differentiates between different placoid disorders is the distribution and progression of lesions. In 2000 Jones et al. published a series of <sup>6</sup> patients with placoid lesions similar to APMPE and serpiginous choroiditis, but smaller in size, with a more extensive distribution of lesions extending anterior to the equator and with a prolonged clinical course <sup>9</sup>. They named this entity relentless placoid chorioretinopathy (RPC). The condition has also been referred to as ampiginous choroiditis. The largest series to date by Jyotirmay et al. includes 26 patients <sup>10</sup>.

Clinical characteristics of patients with RPC have been described in published case series <sup>9,10</sup>. This entity affects young patients (median age 34), with a male predominance. Sudden painless blurring of vision and floaters are the most frequent presenting complaints <sup>9,10</sup>. Yellow placoid lesions in the midperiphery are most commonly the first to appear with later progression involving the periphery and macula. The chorioretinopathy can evolve to over fifty lesions scattered throughout the posterior pole and periphery. This distribution and size of the lesions is distinct from both APMPE and serpiginous choroiditis <sup>2,9</sup>. Typically, there are bilateral active lesions at presentation. There have been six unilateral cases reported in the literature although in most cases the contralateral eye showed some element of inflammation (without distinct placoid lesions) and a significant proportion later developed lesions in the fellow eye at subsequent follow-up <sup>11</sup>. In some cases, lesions can appear characteristic of APMPE or serpiginous choroiditis at initial presentation but then

show progression and recurrence over months to years which is atypical for these conditions <sup>12</sup>. Vitritis, anterior chamber reaction, papillitis and vasculitis are usually absent. A single case of retinal vein occlusion diagnosed three months after onset of RPC has been reported <sup>13</sup>. Both APMPE and RPC have been associated with cerebral vasculitis and stroke <sup>14,15</sup>. A relapse rate of 35%-65% has been reported with new active lesions appearing either adjacent to old scarred lesions or at a new site <sup>10</sup>. The disease burns out within 2-5 years. Visual acuity outcomes depend on the stage at which treatment begins, with treatment initiated early in the course associated with stability of vision in about 75% of patients <sup>10</sup>. Subretinal exudates and progressive subretinal fibrosis rarely occur but can result in poor visual outcomes <sup>10,16</sup>.

Multimodal imaging is helpful in diagnosing and monitoring RPC for relapse. Acute lesions have findings similar to the placoid lesions in APMPE. OCT in the acute stage shows hypo reflectivity of the interdigitation zone, hyperreflectivity of the outer nuclear layer, external limiting membrane disruption, RPE thickening and infiltration of choriocapillaris <sup>17-19</sup>. Subretinal fluid and pigment epithelial detachment have also been reported <sup>19</sup>. Later, progressive thinning and loss of outer retinal layers and RPE with RPE clumping is seen <sup>17,18</sup>. There can be some restoration of the outer retina after healing. Veronese et al. reported fundus autofluorescent findings of active lesions and identified a specific pattern with three concentric zones of different autofluorescence (a central round area of hypoautofluorescence followed by a narrow hyperautofluorescence circular zone, followed by a faint wide hypoautofluorescence ring) that they named the cockade sign <sup>20</sup>. They further correlated this pattern with OCT findings involving the outer nuclear layer, RPE and inner choroid. FA characteristics of active

lesions also show a concentric pattern with central hypofluorescence from loss of choriocapillaris and hyperfluorescent margins in the early phase, with late staining<sup>10</sup>. Analysis of choriocapillaris flow with OCTA supports the inner choroid as the primary site of disease pathogenesis in both APMPE and RPC with secondary damage to the photoreceptors<sup>21</sup>.

APMPPE often occurs following a febrile, flu-like illness, and there has been some association with infections such as adenovirus and coxsackievirus<sup>22-24</sup>. HLA-A3 and HLA-C7 positivity has been noted in patients with widespread pan retinal APMPE<sup>25</sup> and are thought to increase an individual's susceptibility to developing disease following adenoviral exposure<sup>26</sup>. There have also been reports of onset of APMPE following various vaccinations<sup>2</sup>. This suggests that the etiology of APMPE may be secondary to a self-limited immune response to a viral antigen. The association with cerebral vasculitis also supports an autoimmune etiology. A single case of RPC reported in the literature occurred following COVID-19 vaccination<sup>27</sup>. Interestingly, this patient had multiple recurrences coinciding with subsequent COVID-19 infection as well as after respiratory infections<sup>27</sup>. This raises the question of whether RPC is also secondary to a specific viral antigenic trigger, but with recurrent exposures causing reactivation, or to antigenic cross-reactivity and non-specific immune activation with multiple relapses.

Early retinal findings from models of viral retinitis have been compared with the acute findings seen in APMPE and RPC. One such model, the von Szily animal model, involves inoculation of HSV into the ciliary body cleft of one eye and observing delayed retinitis in the contralateral eye<sup>28</sup>. Viral transmission via retrograde axonal transport through the optic nerve and into the

retina is postulated to occur, with resultant disruption of axoplasmic flow, formation of axonal spheroids and passage of the virus to the photoreceptors and RPE. Axonal spheroids have been shown to resolve with restoration of axoplasmic flow and this may be the mechanism behind placoid lesion resolution. The early placoid-like changes in this retinitis model show many similarities to imaging findings seen in APMPE and RPC. Outer nuclear layer hyperreflectivity, RPE disruption and focal separations between RPE and Bruch's membrane are seen in this model. Choriocapillaris thickening and infiltration with inflammatory cells (but not viral particles) has also been noted in the von Szily model and correlates with the development of retinal lesions. These observations support the theory that an inciting viral illness can be the initial trigger for APMPE and RPC.

The progressive and recurrent nature of RPC however is thought to involve an autoimmune mediated response. This is supported by the systemic immunosuppressive treatment that is required to achieve remission. Treatment with systemic steroids is considered first line for this disease, but the addition of immunosuppressive therapy is needed to prevent recurrence and progression<sup>29</sup>. A small case series showed no improvement in disease control after corticosteroid treatment alone versus observation<sup>30</sup>. Fifty percent of patients were able to maintain remission with oral prednisone and azathioprine in the case series presented by Jyotirmay et al.<sup>10</sup>. More recent studies have shown success in obtaining quiescence after steroid taper with other immunosuppressive and steroid sparing agents including adalimumab,<sup>31</sup> infliximab,<sup>29</sup> tocilizumab,<sup>29</sup> and cyclosporine<sup>32</sup>. Intravitreal triamcinolone has shown some benefit both in conjunction with adalimumab<sup>31</sup> and as monotherapy in a pregnant woman<sup>33</sup>. A case reported by Luo et al. showed

success in achieving remission following treatment with intravitreal methotrexate after progression despite systemic and peribulbar steroids<sup>34</sup>. This patient was then treated with oral methotrexate as ongoing therapy. Mycophenolate has been used in the treatment of a patient with RPC with associated cerebral vasculitis<sup>15</sup>.

The classification of RPC as a distinct entity is based on the clinical appearance of lesions and their course. Firstly, mid-peripheral and peripheral lesions seen in RPC, do not occur in serpiginous choroiditis or APMPE. Further, the size of the lesions in RPC are much smaller than both serpiginous and APMPE, and the lesions are recurrent unlike in APMPE. However, when considering the imaging findings and the possible etiology of APMPE and RPC, there is significant overlap. There is evidence to suggest an underlying viral trigger for both APMPE and RPC and it is plausible that RPC recurs secondary to antigenic cross-reactivity or repeated exposure to the virus. Further validation of this hypothesis may require the use of metagenomic deep sequencing to detect the presence of viral particles within retinal placoid lesions.

#### References:

1. Gass JDM. Acute Posterior Multifocal Placoid Pigment Epitheliopathy. *Arch Ophthalmol* 1968;80:177–185.
2. Marchese A, Agarwal AK, Erba S, et al. Placoid lesions of the retina: progress in multimodal imaging and clinical perspective. *Br J Ophthalmol* 2022;106:14–25.
3. Dhaliwal RS, Maguire AM, Flower RW, Arribas NP. Acute posterior multifocal placoid pigment epitheliopathy. An indocyanine green angiographic study. *Retin (Phila, Pa)* 1993;13:317–25.
4. Howe LJ, Woon H, Graham EM, et al. Choroidal Hypoperfusion in Acute Posterior Multifocal Placoid Pigment Epitheliopathy An Indocyanine Green Angiography Study. *Ophthalmology* 1995;102:790–798.
5. Dolz-Marco R, Sarraf D, Giovinazzo V, Freund KB. OPTICAL COHERENCE TOMOGRAPHY ANGIOGRAPHY SHOWS INNER CHOROIDAL ISCHEMIA IN ACUTE POSTERIOR MULTIFOCAL PLACOID PIGMENT EPITHELIOPATHY. *Retin Cases Brief Rep* 2016;11:S136–S143.
6. Mrejen S, Sarraf D, Chexal S, et al. Choroidal Involvement in Acute Posterior Multifocal Placoid Pigment Epitheliopathy. *Ophthalmic Surg, Lasers Imaging Retin* 2016;47:20–26.
7. Scarinci F, Fawzi AA, Shaarawy A, et al. LONGITUDINAL QUANTITATIVE EVALUATION OF OUTER RETINAL LESIONS IN ACUTE POSTERIOR MULTIFOCAL PLACOID PIGMENT EPITHELIOPATHY USING OPTICAL COHERENCE TOMOGRAPHY. *Retina* 2017;37:851–857.
8. Lee JG, Spaide RF. RECONSTITUTION OF THE CHORIOCAPILLARIS IN ACUTE POSTERIOR MULTIFOCAL PLACOID PIGMENT EPITHELIOPATHY. *Retin Cases Brief Rep* 2024;18:87–90.
9. Jones BE, Jampol LM, Yannuzzi LA, et al. Relentless placoid chorioretinitis: A new entity or an unusual variant of serpiginous chorioretinitis? *Arch Ophthalmol (Chic, Ill : 1960)* 2000;118:931–8.
10. Jyotirmay B, Jafferji SS, Sudharshan S, Kalpana B. Clinical Profile, Treatment, and Visual Outcome of Ampiginous Choroiditis. *Ocul Immunol Inflamm* 2010;18:46–51.
11. Kutluturk I, Agarwal A, Shulman S, et al. The Clinical Characteristics of Unilateral Placoid Pigment Epitheliopathies. *Ocul Immunol Inflamm* 2020;29:1072–1079.
12. Chan X, Amoroso JR, Hoang QV, Jung JJ. The Spectrum of Relentless Placoid and Acute Posterior Multifocal Placoid Pigment Epitheliopathy (APMPPE): Multimodal Imaging Analysis. *Retin cases brief Rep* 2023.
13. Gupta RR, laboni DSM, Seamone ME. Relentless Placoid Chorioretinitis With Branch Retinal Vein Occlusion and Secondary Peripheral Retinal Neovascularization. *J Vitre Dis* 2020;5:173–176.
14. Hwang ES, Bell JE, Quigley EP, et al. Stroke Due to Cerebral Vasculitis in a Patient with Relentless Placoid Chorioretinitis. *Ocul Immunol Inflamm* 2018;26:921–923.
15. Yeh S, Lew JC, Wong WT, Nussenblatt RB. Relentless placoid chorioretinitis associated with central nervous system lesions treated with mycophenolate mofetil. *Arch Ophthalmol (Chic, Ill : 1960)* 2009;127:341–3.
16. Wu CY, Brooks HL, Davis JL. Subretinal Exudation and Fibrosis in Relentless Placoid Chorioretinitis. *Am J Ophthalmol* 2022;243:e3–e4.
17. Baskaran P, Anthony E. Commentary: Multimodal imaging of relentless placoid chorioretinitis. *Indian J Ophthalmol - Case Rep* 2021;1:678.

18. Ayachit A, Joshi M, Yadav N, et al. Sequential imaging in a case of relentless placoid chorioretinitis. *Indian J Ophthalmol - Case Rep* 2021;1:675.
19. Amer R, Florescu T. Optical coherence tomography in relentless placoid chorioretinitis. *Clin Exp Ophthalmol* 2008;36:388–390.
20. Veronese C, Marcheggiani EB, Tassi F, et al. Early Autofluorescence Findings of Relentless Placoid Chorioretinitis. *Retina* 2014;34:625–627.
21. Klufas MA, Phasukkijwatana N, Iafe NA, et al. Optical Coherence Tomography Angiography Reveals Choriocapillaris Flow Reduction in Placoid Chorioretinitis. *Ophthalmol Retin* 2017;1:77–91.
22. Thomson SPS, Roxburgh STD. Acute posterior multifocal placoid pigment epitheliopathy associated with adenovirus infection. *Eye* 2003;17:542–544.
23. Azar P, Gohd RS, Waltman D, Gitter KA. Acute posterior multifocal placoid pigment epitheliopathy associated with an adenovirus type 5 infection. *Am J Ophthalmol* 1975;80:1003–5.
24. Li AL, Palejwala NV, Shantha JG, et al. Long-term multimodal imaging in acute posterior multifocal placoid pigment epitheliopathy and association with coxsackievirus exposure. *PLoS ONE* 2020;15:e0238080.
25. Baxter KR, Opremcak EM. Panretinal acute multifocal placoid pigment epitheliopathy: a novel posterior uveitis syndrome with HLA-A3 and HLA-C7 association. *J Ophthalmic Inflamm Infect* 2013;3:29.
26. Kasuga I, Hogg JC, Paré PD, et al. Role of genetic susceptibility to latent adenoviral infection and decreased lung function. *Respir Med* 2009;103:1672–1680.
27. Dutt DD, Lam J, Richards J. Bilateral Relentless Placoid Chorioretinitis Following Pfizer-BioNTech COVID-19 Vaccination: Specific Antigenic Trigger or Nonspecific Immune Activation? *Ocul Immunol Inflamm* 2023;ahead-of-print:1–6.
28. Steptoe PJ, Pearce I, Beare NAV, et al. Proposing a Neurotropic Etiology for Acute Posterior Multifocal Placoid Pigment Epitheliopathy and Relentless Placoid Chorioretinitis. *Front Ophthalmol* 2022;1:802962.
29. Zaheer HA, Odden J, Gagrani M, et al. Relentless placoid chorioretinitis: A review of four cases in pediatric and young adult patients with a discussion of therapeutic strategies. *Front Pediatr* 2022;11:885230.
30. Steptoe PJ, Pearce I, Beare NAV, et al. Clinical Outcomes of Observed and Treated Acute Posterior Multifocal Placoid Pigment Epitheliopathy and Relentless Placoid Chorioretinitis. *Ocul Immunol Inflamm* 2023:1–7.
31. Porteny JR, Witkin AJ. Relentless Placoid Chorioretinitis Responsive to Intravitreal Triamcinolone and Systemic Adalimumab. *Retin Cases Brief Rep* 2023.
32. Uraki T, Namba K, Mizuuchi K, et al. Cyclosporine and prednisolone combination therapy as a potential therapeutic strategy for relentless placoid chorioretinitis. *Am J Ophthalmol Case Rep* 2019;14:87–91.
33. Roth DB, Ballantine S, Mantopoulos D, et al. RELENTLESS PLACOID CHORIORETINITIS. *Retin Cases Brief Rep* 2017; Publish Ahead of Print:NA;
34. Luo L, Chen W-B, Zhao M-W, Miao H. Systemic combined with intravitreal methotrexate for relentless placoid chorioretinitis: A case report. *World J Clin Cases* 2022;10:13115–13121.

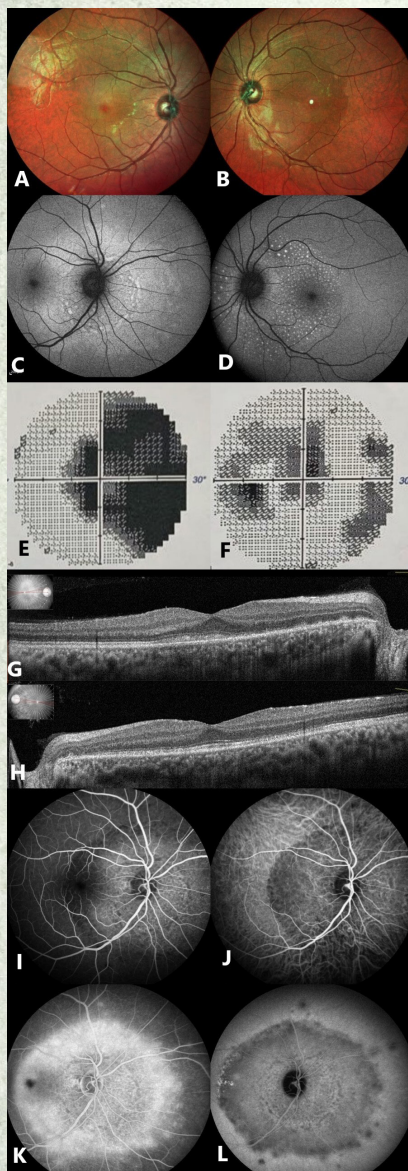


## Image Contest Winner

### Multimodal Imaging in Acute Zonal Occult Outer Retinopathy (AZOOR)



**Dr. Shweta Parakh**, MS, FICO, MRCSEd,  
Consultant, Drishti Eye Hospital, Dehradun  
[dr.shweta.parakh@gmail.com](mailto:dr.shweta.parakh@gmail.com)



A 30-year-old-male, complaining of bilateral scotoma, presented with an apparently normal fundus in the right eye (OD) (A) and mild retinal pigment epithelium (RPE) alteration at the posterior pole in the left eye (OS)

(B). Short wave fundus autofluorescence revealed diffuse peripapillary hyperautofluorescence with scalloped edges OD depicting early AZOOR

(C) and speckled peripapillary and perifoveal hyperautofluorescence OS in a typical trizonal pattern, suggestive of intermediate AZOOR

(D). Greyscale on perimetry showed a deep wedge-shaped temporal scotoma OD

(E) and an ill-defined central scotoma with enlargement of blind spot OS

(F). Spectral domain optical coherence tomography (SD-OCT) illustrated trizonal outer retinal changes seen as patchy disruption of ellipsoid zone more prominent in OD

(G) than OS

(H). Fundus fluorescein angiography (FFA) OD showed early peripapillary hyperfluorescence (I) and intense late staining

(J). Indocyanine green angiography (ICGA) OD revealed early

(K) and late peripapillary hypofluorescence

(L). Similar FFA and ICGA findings were noted in OS as well. The patient responded well to treatment with oral prednisolone in tapering dose over 4 weeks.

# The Enigma of MEWDS



**Dr. Francesco Pichi, MD**

Staff Physician, The Eye Institute at Cleveland Clinic Abu Dhabi, Associate Professor, Case Western Reserve University, Cleveland, Ohio, USA  
*ilmiticopicchio@gmail.com*

**M**ultiple evanescent white dot syndrome (MEWDS) was first described by Jampol et al. in 1984. (1) It is a self-limiting disease that manifests as unilateral, in most cases, multifocal, yellow-white retinal dots and spots in the posterior pole toward the mid periphery. (2) The clinical symptoms are photopsia, blurred vision, or a blind spot in the periphery of the visual field, which correlates with a temporal scotoma. (3) This disease affects young patients between the ages of 20 and 40, with a median age of 27, and can be preceded by a viral flu episode. It is more common in females, and it is related to myopia. (4) The pathophysiology is currently not elucidated; in the past, it was regarded as a condition affecting the outer retina due to hyperfluorescent spots seen on fluorescein angiography (FA). (1,5) With the acquisition of different tools, Agrawal et al. 2013 evaluated the role of indocyanine green angiography (ICGA) in patients with posterior uveitis and reported in MEWDS patients, multiple late hypofluorescence lesions that colocalize with the spots explaining that these lesions are due to

choroidal ischemia. (6) Nevertheless, Pichi et al. (2016) reported a retrospective case series that evaluated 36 patients with MEWDS who underwent multimodal imaging including optical coherence tomography angiography (OCTA) in which all patients showed a normal choriocapillaris which suggests a possible photoreceptor pathology. (7) These findings are associated with the disruption observed in the ellipsoid zone and outer segments, as evidenced by OCT and ICGA. (8,9) Pellegrini et al. evaluated 16 patients with MEWDS and reported in the acute stage of MEWDS, the subfoveal choroidal thickness (CT), total choroidal area, and choroidal vascularity index (CVI) were significantly higher in affected eyes compared to fellow eyes ( $371.2 \pm 101.8$  vs.  $317.1 \pm 90.3$   $\mu\text{m}$ ,  $p = .001$ ;  $2.826 \pm 0.686$  vs.  $2.524 \pm 0.674$   $\text{mm}^2$ ,  $p = .014$ ;  $69.49 \pm 3.51$  vs.  $68.27 \pm 3.41\%$ ,  $p = .044$ , respectively). However, in the recovery stage, these parameters significantly decreased in eyes with MEWDS, with subfoveal CT, total choroidal area, and CVI reducing to  $333.4 \pm 90.5$   $\mu\text{m}$ ,  $p = .007$ ;  $2.592$

$\pm 0.570 \text{ mm}^2$ ,  $p = .002$ ; and  $67.31 \pm 2.74\%$ ,  $p = .014$ , respectively. These outcomes suggested MEWDS is due to a primary choriocapillaritis. (10)

Some articles suggested that a predisposed immune dysregulation could be associated with some vaccination-related cases, such as hepatitis B, hepatitis A, meningococcus, human papillomavirus, or after a coxsackie virus exposure or varicella infection. (11,12)

The clinical features are a unilateral compromise, but some articles reported bilateral or asymmetric compromise in around 10% of patients. (13) Ocular findings are mild iritis in the involved eye, variable vitritis, blurred optic disc, and multiple yellow-white dots and spots approximately 100 to 200  $\mu\text{m}$  located in the posterior pole toward the mid periphery; in those cases without dots, foveal granularity appears (14). With time, these dots disappear without any sequelae or are replaced by pigment mottling. (15) In multimodal imaging, FA in the early phases shows hyperfluorescent dots that resemble a wreath-like pattern correlating with the lesions on clinical fundus photography; however, those lesions are more on FA compared with clinical fundus examination; with the progress of angiogram patchy staining located in the retina and retinal pigment epithelium (RPE), hyperfluorescent disc and peripheral leakage and non-cystoid leakage in the macula in the late phase is seen. (16) On fundus autofluorescence, numerous hyperautofluorescent lesions are observed and disappear after bleaching, which correlates with the findings on clinical fundus photography (17) The ICGA shows no abnormalities of the choroidal vessels in the early phase; however, hypofluorescent lesions are visibly located around the optic disc, posterior pole, and mid-periphery in the late phase. (6) According to these findings, some studies reported possible ischemia at

the level of inner choroidal vessels but is not identified in the early phase of ICGA. (18)

On OCT, these spots are visualized as disruption of the ellipsoid zone, with hyperreflective accumulations in the outer retina and retinal pigment epithelium (RPE) irregularities; these irregularities are correlated with the findings on FA. On the other hand, in cases of recurrent MEWDS, the OCT shows thinning of the outer nuclear layer. (19,20) A study reported by Pichi et al. (2016) has cast doubt on choriocapillaritis as the cause of MEWDS; their findings indicate that OCTA doesn't reveal any abnormalities in choriocapillaris circulation, challenging the conventional understanding of MEWDS. (7) Nonetheless, Lages et al. (2018) considered that non-perfusion and choriocapillaris hypoperfusion are the cause of the features in MEWDS, at the same time, they suggested that the absence of signs on OCTA doesn't mean the absence of perfusion in the choriocapillaris and hypofluorescence observed on ICGA cannot be attributed to the absence of ICG fixation, as pathological regions typically demonstrate ICG fixation, dismissing this hypothesis. (21) On adaptive optics scanning laser ophthalmoscopy (AOSLO), Onishi et al. evaluated seven eyes of patients with MEWDS, where hyperreflective lesions correlate with the infrared granularity findings. (22) Although the lesions situated in the periphery are disruptions in the ellipsoid zone, identified as "spots," these have been identified as areas devoid of photoreceptor outer segments using AOSLO. (23) (Table 1)

This disease's clinical course and prognosis are good; the studies reported recovery in 3 -10 weeks as a self-limited disease. (24) Bosello et al. conducted a retrospective study involving 51 eyes with MEWDS, where the percentage of eyes that recovered to

0.0 LogMar was 80.3% (41 eyes); the study also noted that young patients with initial poor visual acuity were more likely to have an incomplete recovery of visual acuity. (25) Some studies reported overlapping of MEWDS with other diseases, such as punctate inner choroidopathy (PIC) and multifocal choroiditis (MFC), involving at the same time both eyes or unilaterally. (26) Russell et al. evaluated a retrospective case series involving 22 eyes with classical findings of MEWDS with numerous white-grayish outer retinal spots correlating with hyperautofluorescent spots on FAF and disruption of the ellipsoid zone on OCT, in which the most masqueraded disease was syphilis (six eyes), followed by primary vitreoretinal lymphoma ( five eyes ) and then less frequently tuberculosis (one eye). (8) Essilfie et al. reported 17 cases with secondary MEWDS, of which 15 eyes showed a late onset of MFC. In most cases, visual acuity was 20/20, except for two cases with macular choroidal neovascularization (CNV). (27) Additional complications include peripapillary CNV and focal choroidal excavation, which manifest months or even years after the resolution of the disease. (28)

In conclusion, MEWDS is a distinctive and predominantly unilateral condition characterized by multifocal yellow-white retinal dots and spots, primarily affecting young individuals. While the precise pathophysiological mechanisms remain incompletely understood, advancements in imaging technologies have provided valuable insights into choroidal and retinal changes associated with MEWDS. Despite initial theories suggesting outer retinal involvement, recent evidence points towards potential choriocapillaris pathology. Clinical manifestations include photopsia, blurred vision, and peripheral visual field defects, with notable imaging findings on fluorescein angiography (FA), optical coherence tomography (OCT), and indocyanine green angiography (ICGA). Although MEWDS generally follows a self-limiting course with favorable visual outcomes, complications such as choroidal neovascularization and focal choroidal excavation may arise later. Furthermore, MEWDS may overlap with other ocular conditions, posing challenges in diagnosis and management. Ongoing research efforts are crucial for elucidating the underlying mechanisms and optimizing therapeutic strategies for MEWDS.

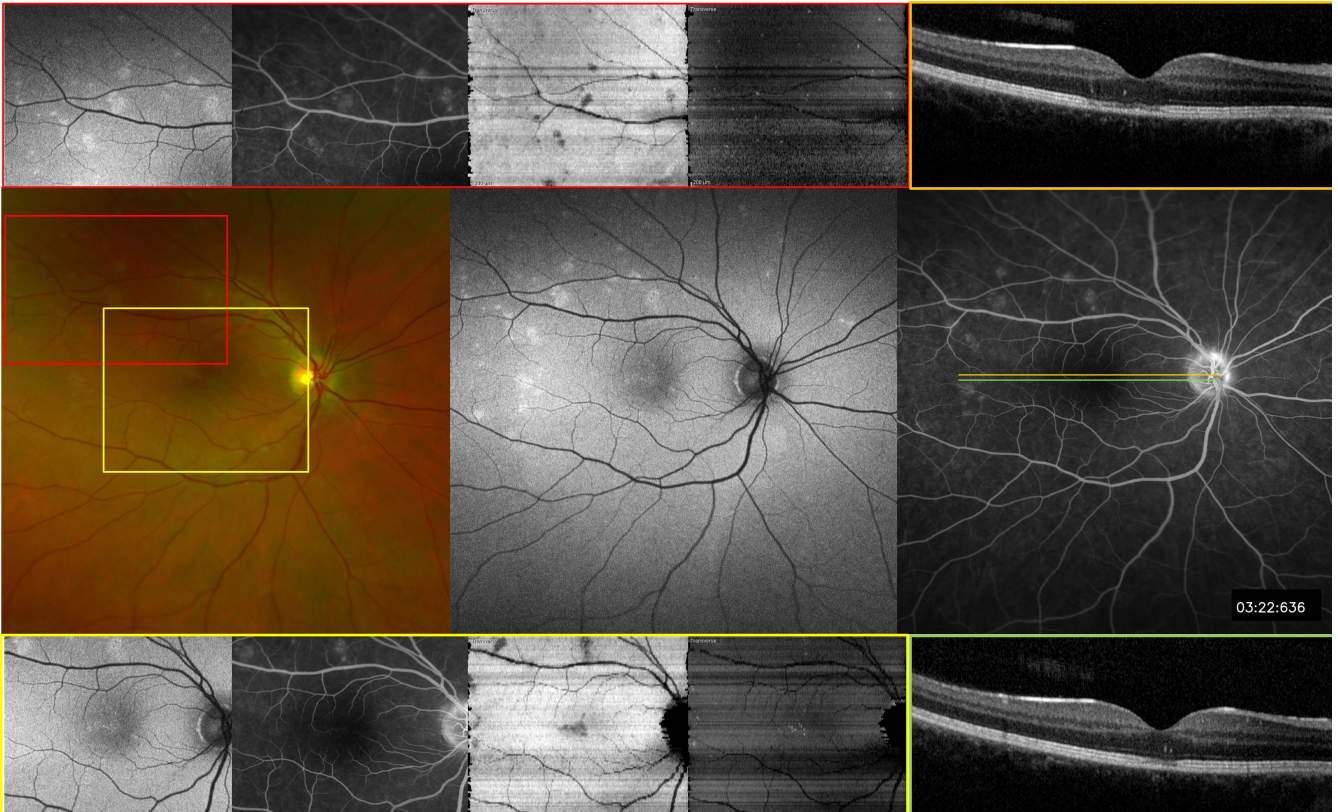
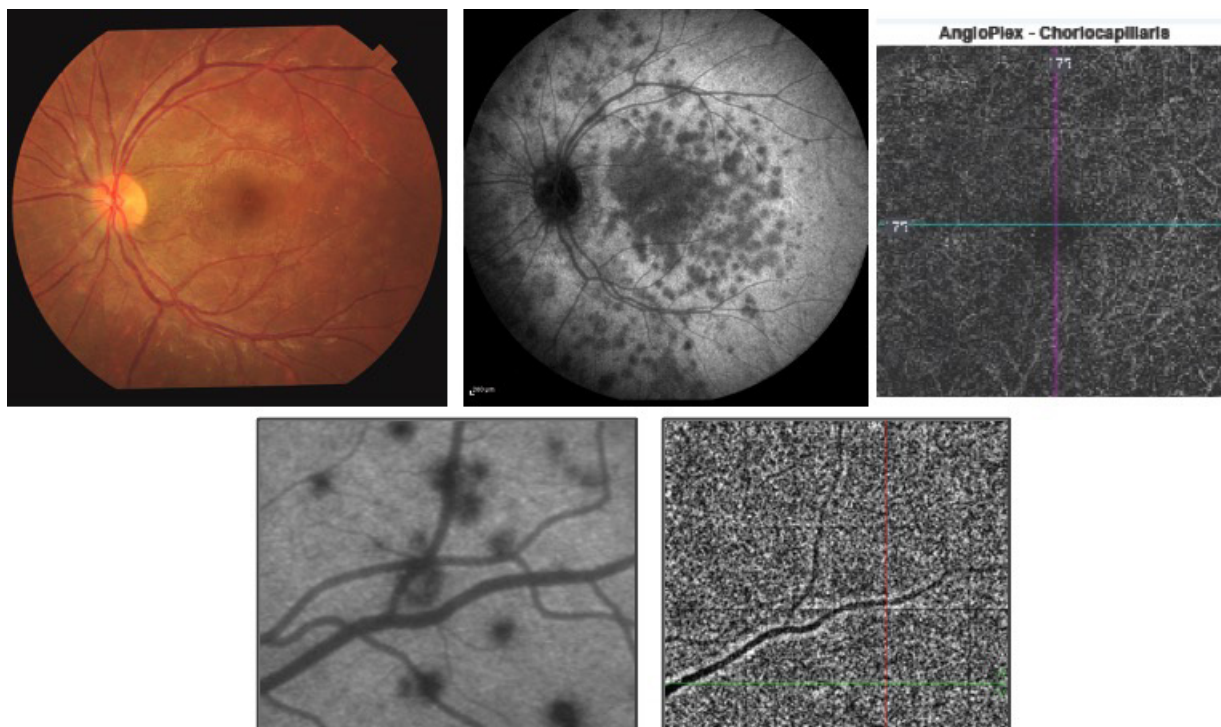


Figure 1

The fundus photograph (middle row, left) shows classical white spots which are hyper-autofluorescent (middle row, center) and stain with a wreath-like pattern on FA (middle, right).

The top row shows en face OCT segmented at the level of the ONL and the ellipsoid along the supero-temporal arcade. The bottom row shows the same slices in the macular area. The en-face scans sliced at the level of the ONL show multiple hyperreflective dots in the foveal area and along the arcades, lesions that could not be detected on fundus examination. Spectral domain optical coherence tomography scanning through these hyperreflective ONL "dots" (orange and green square) confirms their location in the ONL. Note these lesions are hyperreflective ovals with an underlying intact external limiting membrane

The en-face slices at the level of the ellipsoid show hyporefective spots. SD-OCT through the "spots" shows attenuation of the ellipsoid band corresponding to the "spots" and hypertrophy of the underlying retinal pigment epithelium.



**Figure 2**  
 The white spots of MEWDS are hypo-fluorescent on ICGA (top row, center). However, this is not real choriocapillaris ischemia, as highlighted by OCTA (top row, right) that doesn't show any flow void. This is confirmed by a peripheral scan (bottom row) where lesions are visible in ICG but not on OCTA. MEWDS doesn't affect the choriocapillaris but causes RPE alterations that prevent that layer from binding with the indocyanine dye, and thus giving the appearance of hypofluorescent spots on ICGA.

Table 1. Characteristics of multimodal imaging in MEWDS	
Imaging	Features
Fundus Autofluorescence (FAF)	Hyperautofluorescent areas (spots) corresponding with the spots.
Fluorescein Angiography (FA)	Early phase: numerous hyperfluorescent spots located in the middle and deep retina with an early “wreath-like pattern,” Late phase: late staining of the lesions and optic disc leakage Diffuse non-cystoid leakage in the macula Resolution stage: Windows defect in the macula
Indocyanine green Angiography (ICGA)	Early phase: No abnormalities in the choroidal vessels Late Phase: Multiple hypofluorescent lesions more than FA
Spectral Domain OCT	Focal disruption of the ellipsoid zone, irregularity in the retinal pigment epithelium, and hyperreflective area. Recurrences: Thinning of the outer nuclear layer

Modified from: Ramakrishnan, M. S., Patel, A. P., Melles, R., & Vora, R. A. (2021). Multiple evanescent white dot syndrome: findings from a large northern California cohort. *Ophthalmology Retina*, 5(9), 850-854.

## References

1. Jampol LM, Sieving PA, Pugh D, et al. Multiple evanescent white dot syndrome. I. Clinical findings. *Arch Ophthalmol.* 1984;102:671e674.
2. Quillen, D. A., Davis, J. L., Gottlieb, J. L., Blodi, B. A., Callanan, D., Chang, T., & Equi, R. A. (2004). The white dot syndromes. *American Journal of Ophthalmology.* <https://doi.org/10.1016/j.ajo.2004.01.053>
3. Tavallali, A., & Yannuzzi, L. A. (2017). MEWDS, common cold of the retina. *Journal of Ophthalmic & Vision Research*, 12(2), 132.
4. Papisavvas, I., Mantovani, A., Tugal-Tutkun, I. et al. Multiple evanescent white dot syndrome (MEWDS): update on practical appraisal, diagnosis, and clinicopathology; a review and an alternative comprehensive perspective. *J Ophthal Inflamm Infect* 11, 45 (2021). <https://doi.org/10.1186/s12348-021-00279-7>
5. Sieving PA, Fishman GA, Jampol LM, Pugh D (1984) Multiple evanescent white dot syndrome. II. Electrophysiology of the photoreceptors during retinal pigment epithelial disease. *Arch Ophthalmol* 102(5):675–679
6. Agrawal, R. V., Biswas, J., & Gunasekaran, D. (2013). Indocyanine green angiography in posterior uveitis. *Indian journal of ophthalmology*, 61(4), 148–159.
7. Pichi F, Srivastava S, Chexal S, et al. (2016) En face optical coherence tomography and optical coherence tomography angiography of multiple evanescent white dot syndrome. *Retina* 36:S178–S188
8. Russell, J.F., Pichi, F., Scott, N.L. et al. Masqueraders of multiple evanescent white dot syndrome (MEWDS). *Int Ophthalmol* 40, 627–638 (2020). <https://doi.org/10.1007/s10792-019-01223-4>
9. Pellegrini M, Veronese C, Bernabei F, Lupidi M, Cerquaglia A, Invernizzi A, Zicarelli F, Cimino L, Bolletta E, Vagge A, Ciardella AP. Choroidal vascular changes in multiple evanescent white dot syndrome. *Ocul Immunol Inflamm* 2021. *Ocul Immunol Inflamm.* 2021;29(2):340–345. doi: 10.1080/09273948.2019.1678650.
10. Goyal, S., Nazarian, S. M., Thayi, D. R., Hammond, F., & Petrovic, V. (2013). Multiple evanescent white dot syndrome following recent influenza vaccination. *Canadian Journal of Ophthalmology*, 48(5), e115–e116.
11. Ramakrishnan MS, Patel AP, Melles R, Vora RA (2021) Multiple evanescent white dot syndrome: findings from a large northern California cohort. *Ophthalmol Retina* 5(9):850–854.
12. Marsiglia M, Gallego-Pinazo R, Cunha de Souza E, et al. (2016) Expanded clinical spectrum of multiple evanescent white dot syndrome with multimodal imaging. *Retina* 36:64–74
13. Ramakrishnan MS, Patel AP, Melles R, Vora RA (2021) Multiple evanescent white dot syndrome: findings from a large northern California cohort. *Ophthalmol Retina* 5(9):850–854.
14. Agarwal, A., Pichi, F., Invernizzi, A., Grewal, D. S., Singh, R. B., & Upadhyay, A. (2023). Stepwise approach for fundus imaging in the diagnosis and management of posterior uveitis. *Survey of Ophthalmology*, 68(3), 446–48
15. Mantovani A, Giani A, Herbort CP, Staurenghi G. Interpretation of fundus autofluorescence changes in choriocapillaris: a multi-modality imaging study. *Graefes Arch Clin Exp Ophthalmol.* 2016;254(8):1473–9.
16. Takahashi A, Saito W, Hashimoto Y, Ishida S. Multiple evanescent white dot syndrome associated with retinal vasculitis. *Int Med Case Rep J.* 2015;8:209–213.
17. Battaglia Parodi M, Iacono P, Falcomatà B, Bolognesi G, Bandello F. Near-infrared fundus autofluorescence in multiple evanescent white-dot syndrome. *Eur J Ophthalmol.* 2015 Jan-Feb;25(1):43–6. doi: 10.5301/ejo.5000534.
18. Obana A, Kusumi M, Miki T. Indocyanine green angiographic aspects of multiple evanescent white dot syndrome. *Retina* 1996;16(2):97–104.
19. Pereira, F., Lima, L. H., de Azevedo, A. G. B., Zett, C., Farah, M. E., & Belfort, R. (2018). Swept-source OCT in patients with multiple evanescent white dot syndrome. *Journal of Ophthalmic Inflammation and Infection*, 8, 1–5.
20. Mantovani A, Invernizzi A, Staurenghi G, Herbort CP Jr. Multiple Evanescent White Dot Syndrome: A Multimodal Imaging Study of Foveal Granularity. *Ocul Immunol Inflamm.* 2019;27(1):141–147. doi: 10.1080/09273948.2017.1353104.
21. Lages, V., Mantovani, A., Papadia, M., & Herbort, C. P. (2018). MEWDS is a true primary choriocapillaris, and basic mechanisms do not seem to differ from other choriocapillaris entities—*Journal of current ophthalmology*, 30(4), 281.

22. Onishi AC, Roberts PK, Jampol LM, et al. Characterization and correlation of "Jampol Dots" on adaptive optics with foveal granularity on conventional fundus imaging. *Retina* 2019;39(2): 235–46.
23. Labriola LT, Legarreta AD, Legarreta JE, Nadler Z, Gallagher D, Hammer DX, Ferguson RD, Iftimia N, Wollstein G, Schuman JS (2016) Imaging with multimodal adaptive-optics optical coherence tomography in multiple evanescent white dot syndrome: the structure and the functional relationship. *Retin Cases Brief Rep* 10(4):302–309.
24. Mirza, R. G. and L. M. Jampol (2013). Chapter 76 - White Spot Syndromes and Related Diseases. *Retina (Fifth Edition)*. S. J. Ryan, S. R. Sadda, D. R. Hinton, et al. London, W.B. Saunders: 1337-1380.
25. Bosello F, Westcott M, Casalino G, Agorogiannis G, Micciolo R, Rees A, Pavesio C. Multiple evanescent white dot syndrome: clinical course and factors influencing visual acuity recovery. *Br J Ophthalmol*. 2022 Jan;106(1):121-127.
26. Kuznetcova T, Jeannin B, Herbort CP (2012) A case of overlapping choriocapillaritis syndromes: multimodal imaging appraisal. *J Ophthalmic Vis Res* 7(1):67–75
27. Essilfie J, Bacci T, Abdelhakim AH, Ramtohol P, Turchi F, Freund KB, Yannuzzi LA (2021) Are there two forms of multiple evanescent white dot syndrome? *Retina Publish Ahead of Print*. <https://doi.org/10.1097/IAE.0000000000003288>
28. Hashimoto Y, Saito W, Noda K, Ishida S. Acquired focal choroidal excavation associated with multiple evanescent white dot syndrome: observations at onset and a pathogenic hypothesis. *BMC Ophthalmol*. 2014;14(1):135.



## Case Contest Winner

### A Case of Retinal Pigment Epitheliitis Complicated by a CNVM and is it Primarily a Disease of the Choriocapillaris?



**Dr. Shahana Mazumdar, MS, DNB,**  
Consultant, ICARE Eye Hospital and PG Institute, Noida  
[shahana.mazumdar@gmail.com](mailto:shahana.mazumdar@gmail.com)

A 37 years healthy female optometrist working with us noticed sudden onset of a central scotoma in her right eye. Her vision had dropped to 6/18, N6 with an inferonasal scotoma extending to the centre. There was no metamorphopsia. The Contrast was 1.52 and the Amsler chart recorded the off centre inferonasal scotoma. There was no prior fever or infection.

On examination her macula showed a subtle small hypopigmented lesion ST to fovea, foveal reflex was maintained ( Fig 1A). It was on imaging that the magnitude of the problem became apparent. The OCT showed disruption of the ellipsoid and interdigitation zones at the fovea and perifovea and some hyperreflective lesions that showed increased transmission of laser corresponding to the hypopigmented lesion seen clinically. The infrared (IR) image showed a patch of low reflectivity ( Figure 1C). BAF showed no abnormality. ICGA showed a hypofluorescent patch at the fovea persisting till late phases with adjacent small hyperfluorescent vessel (Figure 2). FFA showed subtle small area of hyperfluorescence ST to foveal centre (Figure 2). The ORCC slab of the OCTA showed an area of flow void at fovea (Figure 1B).

She was diagnosed as Retinal Pigment Epitheliitis and kept under observation. Her central scotoma and vision started improving after 4-7 days but the inferonasal scotoma persisted. However the extent of the hyporeflective area on IR imaging increased (Figure 3) and correspondingly the disruption of outer retinal layers enlarged in size and a small focal choroidal excavation developed on the OCT (Figure 1 D). However reassuringly the area of CC flow void decreased on OCTA and the vision was maintained. She was maintained on close follow-up.

After 10 days an area of SHRM started developing along (Figure 1E) with a vascular tuft seen on OCTA in the flow void area. On developing metamorphopsia with a small fluid cyst in inner retina the presence of a cnvm was confirmed and she was given two anti vegf injections with a gap of 1 month. 6 weeks after the second injection her vision, IR and OCT changes were better ( Figure 1F). But the flow void on OCTA and a smaller IN scotoma persisted.

The last examination was recently at 8 months. Vision and contrast are normal. She is symptomatically alright.

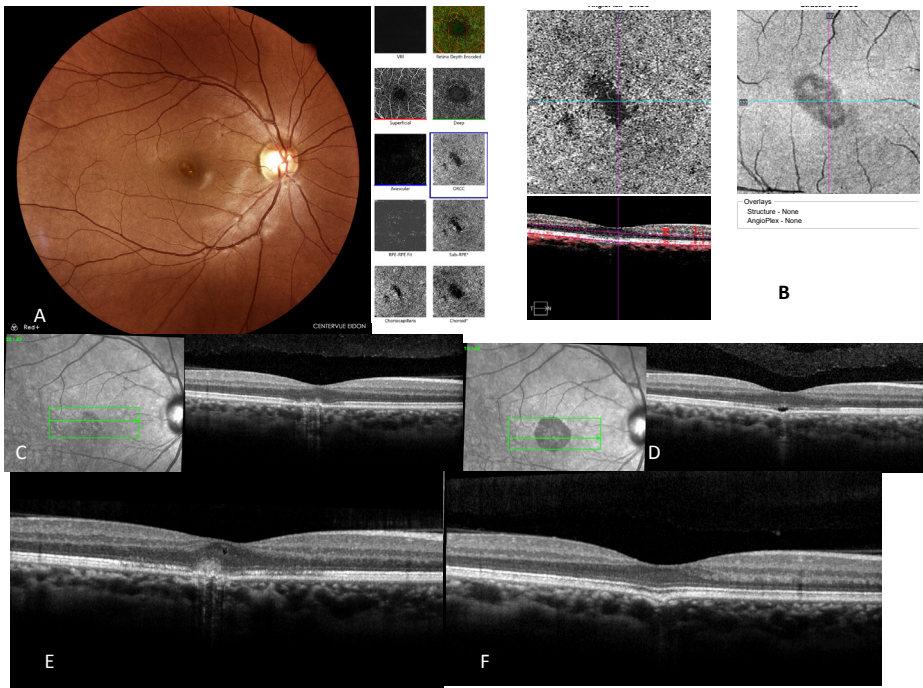


Figure 1

- A) Fundus photo showing small hypopigmented lesion superotemporal to the fovea.
- B) OCT- ORCC slab showing a flow void area of the Choriocapillaris and a corresponding hyporeflective patch on enface.
- C) First OCT macula- subfoveal disruption of the ellipsoid and interdigitation zones with some hyperreflective lesions corresponding to the hypopigmented area seen clinically with increased transmission of laser at those points. The IR image showed a patch of hyporeflectivity.
- D) OCT macula after a week- increase in extent of the disruption along with a small focal excavation. The IR image also showed an increase in size of the hyporeflective lesion.
- E) OCT macula- subretinal hyperreflective material and small intraretinal fluid seen superotemporal to fovea.
- F) Resolving OCT features 6 weeks after two anti vegf injections with a small excavation present.

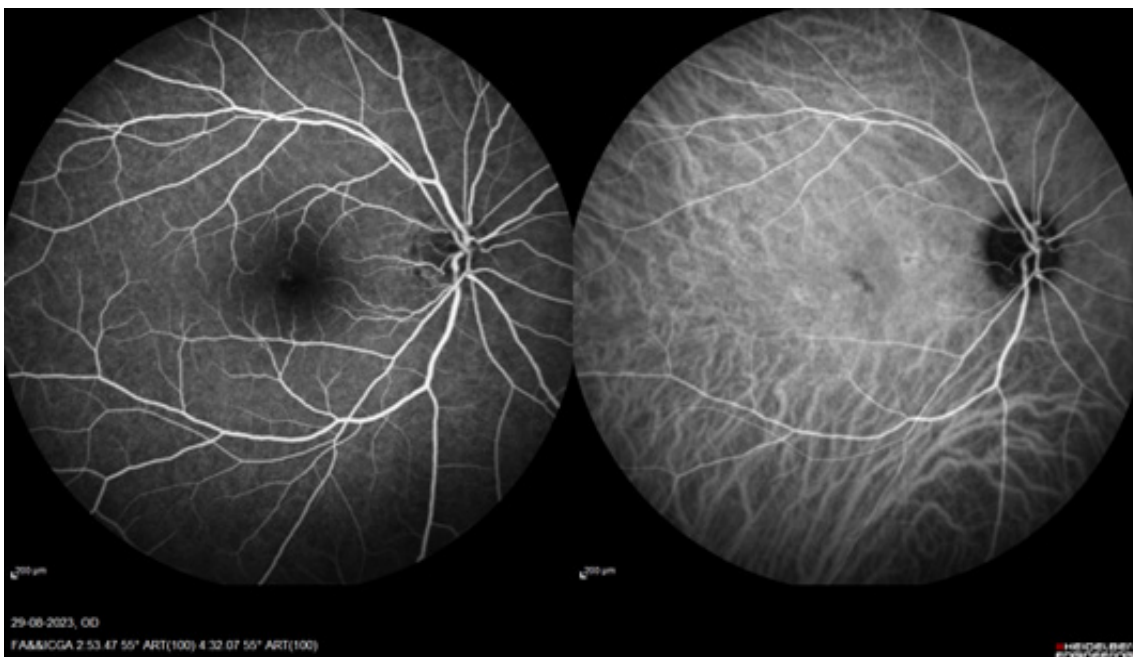

Figure 2

FFA- showed very subtle hyperfluorescence superotemp to fovea. ICGA showed early hypofluorescence at the fovea which persisted till the late phases.

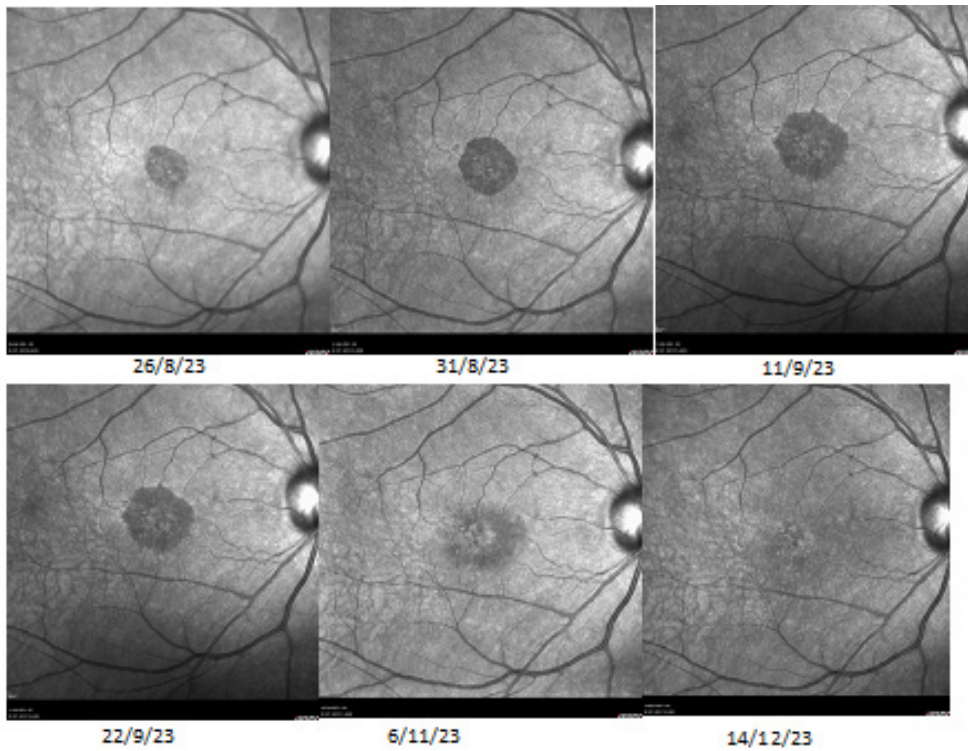


Figure 3

IR images highlighting the timeline and location of the pathology seen as a hyporeflective lesion that increased in size over 4 weeks and gradually resolved over the next 3 months.

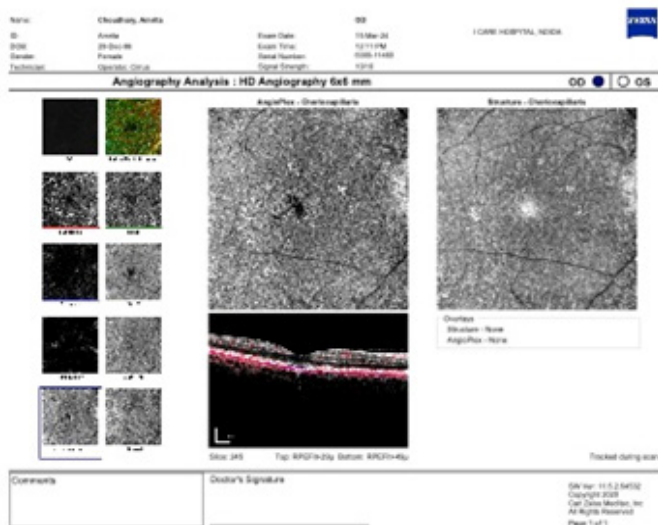
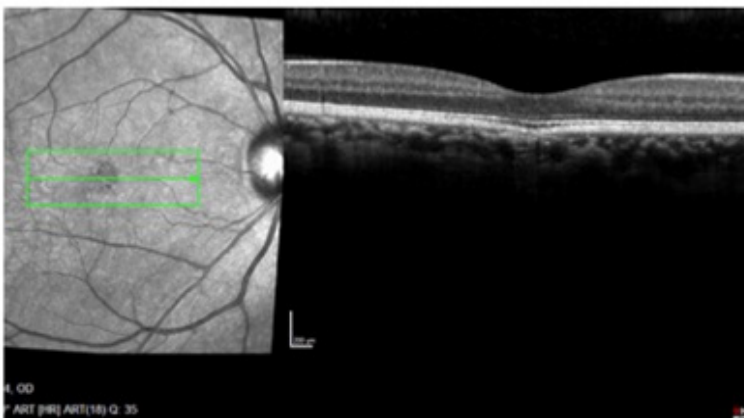


Figure 4

OCT macula showed almost complete normalization of the outer retinal layers with a mild choroidal excavation and OCTA showed a persistant patch of CC flow void though it was smaller in size.



## Discussion

Salient features of the case are as follows: Clinical features are subtle but the pathology becomes vivid on imaging.

The features are best seen on OCTA/IR/OCT. The maximum pathology seems to be at the choriocapillaris level showing ischemia with secondary changes of the overlying RPE and outer retinal layers.

The ischemia/inflammation was severe enough to drive a CNVM which resolved rapidly with 2 anti vegf injections.

The disease itself was self limiting and not preceded by any other incident.

The RPE disease resolved before the choriocapillaris flow void area which is still persistent even after 8 months though smaller in size.

RP Epithelitis or Krill's disease is known to be a self limiting affection of the RPE of unknown etiology typically seen in healthy young adults who present with sudden onset scotoma. It has been thought to be a pathology centred at the RPE level with a normal choroid.

Our case seems to exhibit several features typical of RPEpithelitis but differs in the degree of choriocapillaris (CC) involvement. Our patient had early CC flow voids that halted in progression even though the RPE continued to show progression. Soon after the onset, a choroidal neovascular membrane was formed possibly aggravated by the CC ischemia and inflammation. The RPE resolved within 3 months but the CC flow voids have persisted for 8 months at the last follow up.

# The Spectrum of PIC and MFC



**Dr. Anup Kelgaonkar, MS**

Consultant, LV Prasad Eye Institute, Bhubaneswar.  
[anupnk2008@gmail.com](mailto:anupnk2008@gmail.com)

## Introduction

**M**ultifocal choroiditis (MFC) and punctate inner choroidopathy (PIC) are often considered a spectrum of a similar disease affecting the superficial choroid, deep choroid, retinal pigment epithelium with or without the affection of the outer retina.

The dearth of clinical guidelines and availability of advanced imaging techniques in the bygone years had us perplexed regarding diagnosis and management of these spectrum of disorders, but the advent of new multimodal imaging options and an enrichment in the clinical experience regarding handling these entities over the years have made us wiser.

### Pot-pourri of terminologies:

Various terminologies have been used for both entities, namely Krill's' disease, multifocal inner choroiditis, presumed ocular histoplasmosis syndrome (POHS),

multifocal inner choroiditis with panuveitis. Multifocal choroiditis is an umbrella term caused by infectious, inflammatory, or infiltrative conditions, including tuberculosis, histoplasmosis, syphilis, brucellosis, coccidiomycosis, candidiasis, sarcoidosis, vitreoretinal lymphoma, and other granulomatous diseases. When these underlying conditions are ruled out, a diagnosis of idiopathic MFC (iMFC) is considered.

PIC term has been used to describe mild localized cases restricted to the macular region without vitritis. Despite ongoing debate regarding the distinction between iMFC and PIC, certain authors consider PIC synonymous with iMFC.

Literature review regarding iMFC presentations gives varied terminologies like recurrent multifocal choroiditis, multifocal choroidopathy, disseminated

inner choroiditis, pseudo- POHS and haemorrhagic macular choroidopathy. A very severe and rare inflammatory choroiditis termed as progressive subretinal fibrosis, characterised by the presence of whitish fibrotic subretinal lesions that progressively enlarge and merge together, may refer to severe cases of iMFC.

**Clinical manifestations:** The clinical pattern of PIC is one of the clinical diagnosable one. Round, multiple, punched out lesions are seen predominantly at the macula. Many of these lesions are pigmented scars involving the outer retina, RPE and inner choroid at the presentation visits. The fresh lesions are however dull appearing and difficult to appreciate clinically. These are slightly yellowish, inner choroidal elevated lesions. Fresh lesions can be diagnosed better with multimodal imaging involving fundus fluorescein angiography, optical coherence tomography and autofluorescence. The associated signs of inflammation with PIC are few. Vitritis, optic disc involvement is rare. Choroidal neovascular membranes are commonly associated with PIC. Appearance of an intraretinal or subretinal haemorrhage or a greyish lesion near the old PIC lesions is one of the clinically differentiating features of PIC. The new lesions often heal with variable scarring, atrophy of the outer retina, RPE and inner choroid along with pigmentation on treatment. PIC has been classically seen in eyes with myopia with predominance in women. Generally, the disease is bilateral, although it could be asymmetrical. The lesions are commonly multifocal and rarely unifocal lesions are seen. The size of most of the smaller size lesions are 2-3 times that of first blood vessels, around 80-120 microns. The medium and large sized lesions could be around one thirds to one half disc diameter; rarely lesions of the size of the optic disc are known.

Linear streaks or Schlaegel lines are commonly seen in young women with high and rapidly progressive myopia, often in conjunction with other PIC/iMFC lesions. Secondary CNV occurs in up to 83% of PIC/iMFC lesions and is reported as the most common cause of vision loss in these patients.

While the PIC lesions are predominantly limited to the macula; the extent of lesions in MFC can be much wider. The midperiphery and peripheral affection could be seen. While the macular affection and multifocality are common in both the tuberculosis and the sarcoid; inferior half affection of the choroid seen as inferior hypo lesions is commonly seen in the ocular sarcoidosis.

MFC lesions can often have associated disc edema, retinal vasculitis, cystoid macular edema. Vitritis and anterior uveitis are possible associations of MFC lesions in cases of multifocal choroiditis with panuveitis or MCP.

**Classification Criteria:** The Standardization of Uveitis Nomenclature (SUN) working group machine learning based diagnostic criteria for PIC includes the presence of small (125  $\mu$ m), oval or round-shaped, multifocal choroidal inflammatory lesions in the posterior pole, with or without involvement of the mid-periphery. Additionally, minimal or absent anterior chamber and vitreous inflammation are observed.

Criteria for iMFC include the presence of large (>125  $\mu$ m), oval or round-shaped, multifocal choroidal, inflammatory lesions with punched-out atrophic chorioretinal scars. These lesions are found in the mid-periphery or far-periphery, with or without the involvement of the posterior pole, and exhibit evidence of vitreous inflammation.

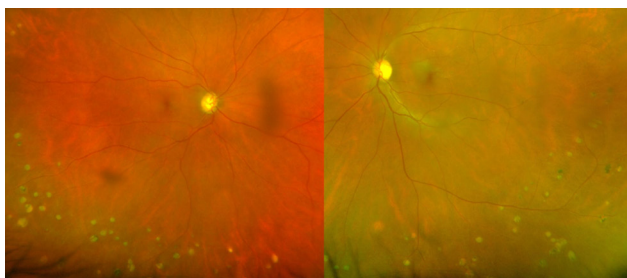


Figure 1: Case of bilateral multifocal choroiditis, showing peripheral lesions

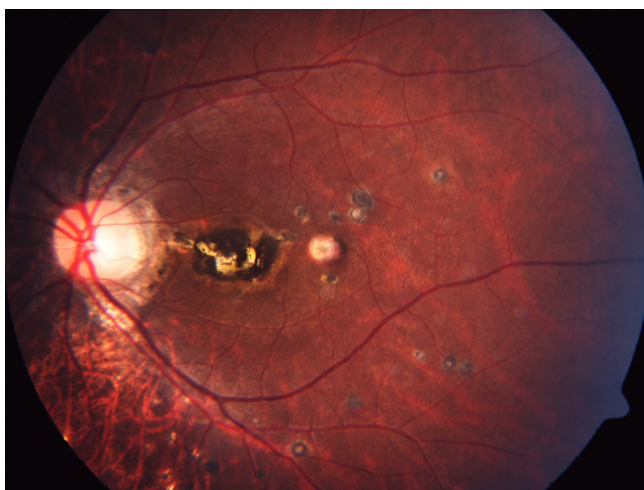


Figure 2: case of PIC with multiple punched out pigmented scars at the macula and outside arcades along with scarred CNVM at the centre.

**Imaging characteristics:** OCT has been defining imaging investigations to image the depth of the PIC lesions. In the initial stage of the disease an infiltration or hyper reflective foci are seen in the inner choroid involving choriocapillaris and partly the Sattler's layer. This inner choroidal involvement in later stages after resolution can lead to variable atrophy and thinning. The RPE can have a nodular elevation, double layer sign with internal hyper reflectivity and/or RPE elevation in the initial stages. After resolution the RPE is seen to be atrophic with retinal thinning. The outer retina is often affected with degeneration or distortion of the ellipsoid layer. A variable outer retinal atrophy after resolution of the lesions has been described.

OCT in multifocal choroiditis is often used to differentiate the partial thickness

lesions from the full thickness ones and differentiation of the large dilated choroidal vessels from the choroidal granulomas. A 5-stage classification system of PIC/iMFC lesions is used in literature showing a sequential progression from choroidal infiltration to sub-RPE nodule, chorioretinal nodule, regression, and retinal herniation. Newly recognized OCT features include focal hyporefectivity and loss of the normal choroidal architecture below the active lesion, splitting of the RPE/Bruch's membrane (BrM), and a posterior deflection of the BrM.

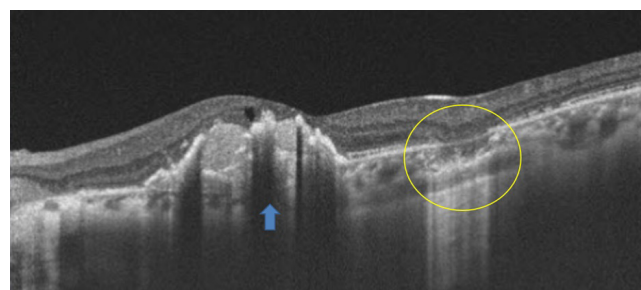


Figure 3: The case of PIC (figure 2) the CNVM is seen as a scar with back shadowing (blue arrow) while the punched out temporal lesions (yellow circle) is seen to have outer retinal atrophy with loss of ONL, ellipsoid and thinning of RPE.

OCTA is especially important in cases with suspicion of CNVM amidst the scars at the macula. OCTA gives a distinct edge over fluorescein angiography in imaging neovascular membranes as the leakage and staining of the dye in the areas of lesions often masks the appearance of a CNVM. It shows a lacy network of vessels in the outer retina on en-face slabs and blood flow signal on corresponding B-scans. Neo vascular flow often persists during disease quiescence, so its presence may not prove disease activity. OCTA may show shrinkage of the CNV network following injections of anti-vascular endothelial growth factor (VEGF) agents and it may enable the detection of centripetal restoration of the choriocapillaris flow signal after immunosuppressive therapy.

FFA of the choroidal lesions in MFC when they are fresh and new show early phase fluorescence while the late phase shows iso fluorescence if partial thickness choroidal and hypo fluorescence if full thickness choroidal. Old scars or atrophic areas often shows hyper fluorescence due to staining. FFA in PIC shows variable hyperfluorescence of the old scars and the fresh lesions. The new lesions might have early round hypo fluorescence leading to a late iso or hyper fluorescence.

Inactive PIC/iMFC lesions are hyperfluorescent in all phases due to RPE window defects. Secondary CNV can be detected on FA as a well-demarcated area of hyperfluorescence in early frames followed by late leakage.

Autofluorescence is one of the predominantly used investigations in PIC. The old scars and the healed lesions are seen to be punched out hypoautofluorescent lesions. While the new lesions appear to be hyperautofluorescent due to affection of the RPE and RPE changes including thickening, nodularity and elevation. Autofluorescence in MFC often has a similar pattern of hyper AF lesions in the new lesions while mottling and hypo AF of the old lesions. Multiple reported patterns range from discrete hyper-FAF halos surrounding active lesions to patchy hyper-FAF lesions, peripapillary hyper-FAF rings, or more diffuse zonal hyper-FAF.

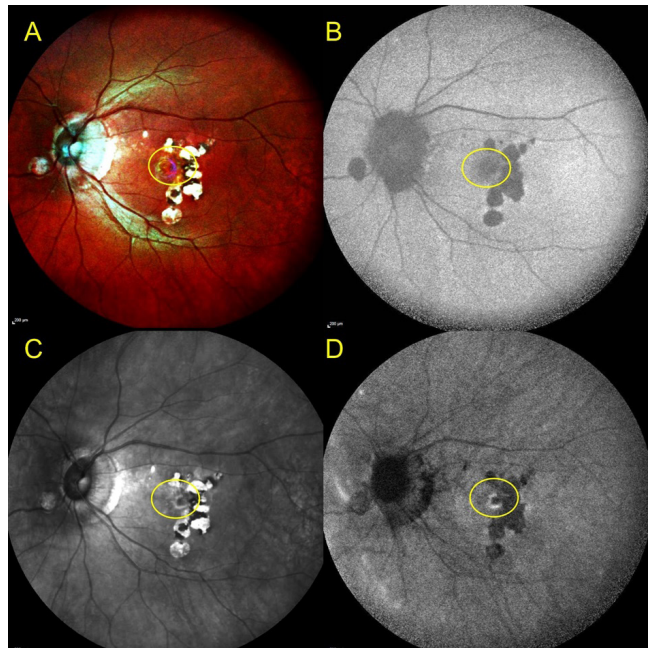


Figure 4: Multiple PIC Lesions are seen at macula (A) with a new lesion (yellow circle) at the fovea. The lesions are ill defined to not be seen on blue autofluorescence (B). The infra-red imaging and the infra-red autofluorescence however highlights the lesion.

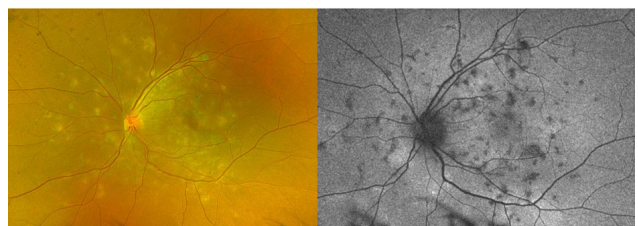


Figure 5: A case of multifocal choroiditis showing hypoautofluorescence of the old lesions and hyperautofluorescence of the new lesions on blue autofluorescence.

### Complications and sequelae:

The PIC lesions are known to heal with accelerated scarring and atrophy within weeks to months. Cystoid macular edema is known which might require additional treatment. The RPE atrophy and outer retinal thinning that ensues after the healing is the reason for significant visual loss. The RPE atrophy can progress to areas beyond the areas of the lesions itself. Choroidal neovascular membranes are common complications in cases of PIC. Rarely recurrences of the lesion's months to years after initial presentation is known.

MFC lesions depending on the etiology can have variable complications of optic disc affection leading to atrophy or pallor, macular scarring, macular pigmentation, CNVM or macular edema.

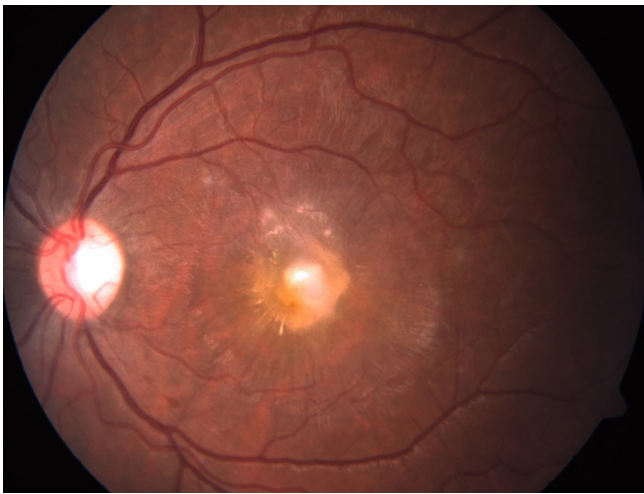

Figure 6: Inflammatory CNVM at the centre is seen along with outer retinal lesions superior to the fovea. Most of these lesions are healed ones.

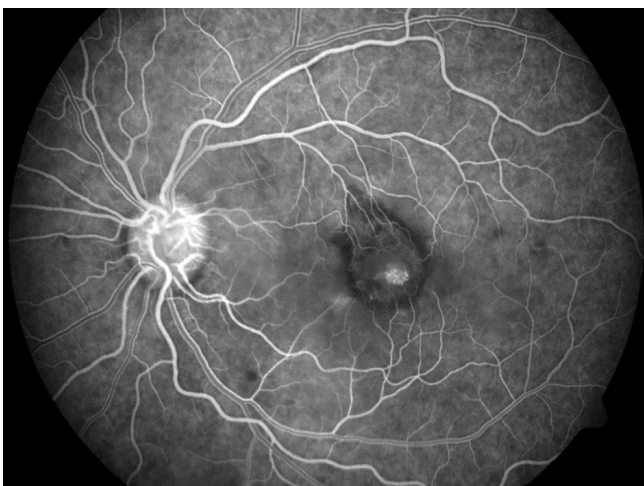


Figure 7: The early lacy pattern of the CNVM along with multiple hypo lesions at the macula in a case of inflammatory CNVM.

## Treatment modalities

### 1. Oral steroids.

PIC and non-infectious MFC is managed initially with oral corticosteroids in order to initiate healing of the choroidal lesions. The requirement of oral steroids in MFC could often be more in view of vitreous, optic disc, retinal vascular affection as opposed to limited outer retinal and inner choroidal lesions in PIC.

### 2. Systemic immunosuppression

PIC and non-infectious MFC often require a prolonged period of immunosuppression given the recurrent and blinding nature of the disease. Systemic immunosuppressive agents have been used in both the groups of diseases though the duration of treatment remains undefined and controversial.

### 3. Periocular and intravitreal injections

#### Steroids:

- ☞ Periocular steroids like trans-septal subtenon triamcinolone acetonide.
- ☞ Intravitreal Dexamethasone implant
- ☞ Intravitreal triamcinolone acetonide (rare)

Periocular or intravitreal steroids can often be employed in cases of cystoid macular edema in cases of PIC and MFC. Additionally, these injections can be used as adjuvants to systemic medication in cases of refractory/persistent inflammation, flare ups, adverse effects of systemic therapy or limitations in giving systemic steroids due to diabetes, etc.

#### Anti-VEGF:

Intravitreal anti-VEGFs are often needed in addition to systemic therapy, being offered for the cases of PIC and MFC when they develop CNVMs. The inflammatory CNVMs often require a lesser number of injections as compared to the cases of age-related macular degeneration CNVMs.

## References:

1. Ahnood, D., Madhusudhan, S., Tsaloumas, M. D., Waheed, N. K., Keane, P. A., & Denniston, A. K. (2017). Punctate inner choroidopathy: A review. *Survey of ophthalmology*, 62(2), 113–126. <https://doi.org/10.1016/j.survophthal.2016.10.003>
2. Campos, J., Campos, A., Mendes, S., Neves, A., Beselga, D., & Sousa, J. C. (2014). Punctate inner choroidopathy: a systematic review. *Medical hypothesis, discovery & innovation ophthalmology journal*, 3(3), 76–82.
3. Amer, R., & Lois, N. (2011). Punctate inner choroidopathy. *Survey of ophthalmology*, 56(1), 36–53. <https://doi.org/10.1016/j.survophthal.2010.03.009>
4. Standardization of Uveitis Nomenclature (SUN) Working Group (2021). Classification Criteria for Multifocal Choroiditis With Panuveitis. *American journal of ophthalmology*, 228, 152–158. <https://doi.org/10.1016/j.ajo.2021.03.043>
5. Singh, R. B., Perepelkina, T., Testi, I., Young, B. K., Mirza, T., Invernizzi, A., Biswas, J., & Agarwal, A. (2023). Imaging-based Assessment of Choriocapillaris: A Comprehensive Review. *Seminars in ophthalmology*, 38(5), 405–426. <https://doi.org/10.1080/08820538.2022.2109939>
6. Karska-Basta, I., Pocij-Marciak, W., Żuber-Łaskawiec, K., Markiewicz, A., Chrzyszcz, M., Romanowska-Dixon, B., & Kubicka-Trzaska, A. (2024). Diagnostic Challenges in Inflammatory Choroidal Neovascularization. *Medicina (Kaunas, Lithuania)*, 60(3), 465. <https://doi.org/10.3390/medicina60030465>
7. Karti, O., Ipek, S. C., Ates, Y., & Saatci, A. O. (2020). Inflammatory Choroidal Neovascular Membranes in Patients With Noninfectious Uveitis: The Place of Intravitreal Anti-VEGF Therapy. *Medical hypothesis, discovery & innovation ophthalmology journal*, 9(2), 118–126.
8. Vianna RN, Ozdal PC, Fiho JP et al. Long-term follow-up of patients with multifocal choroiditis and panuveitis. *Acta Ophthalmol Scand* 2004;82:748–53.
9. Lee CS, Lee AY, Forooghian F, Bergstrom CS, Yan J, Yeh S. Fundus autofluorescence features in the inflammatory maculopathies. *Clin Ophthalmol* 2014;8:2001–12.
10. Thorne JE, Wittenberg S, Jabs DA, et al. Multifocal choroiditis with panuveitis: incidence of ocular complications and loss of visual acuity. *Ophthalmology* 2006;113:2310–6.
11. Cicinelli MV, Ramtohl P, Marchese A, Bandello F, Bailey Freund K, Miserocchi E, Jampol LM. Latest advances in white spot syndromes: New findings and interpretations. *Prog Retin Eye Res*. 2023 Nov;97:101207



## Image Contest Winner

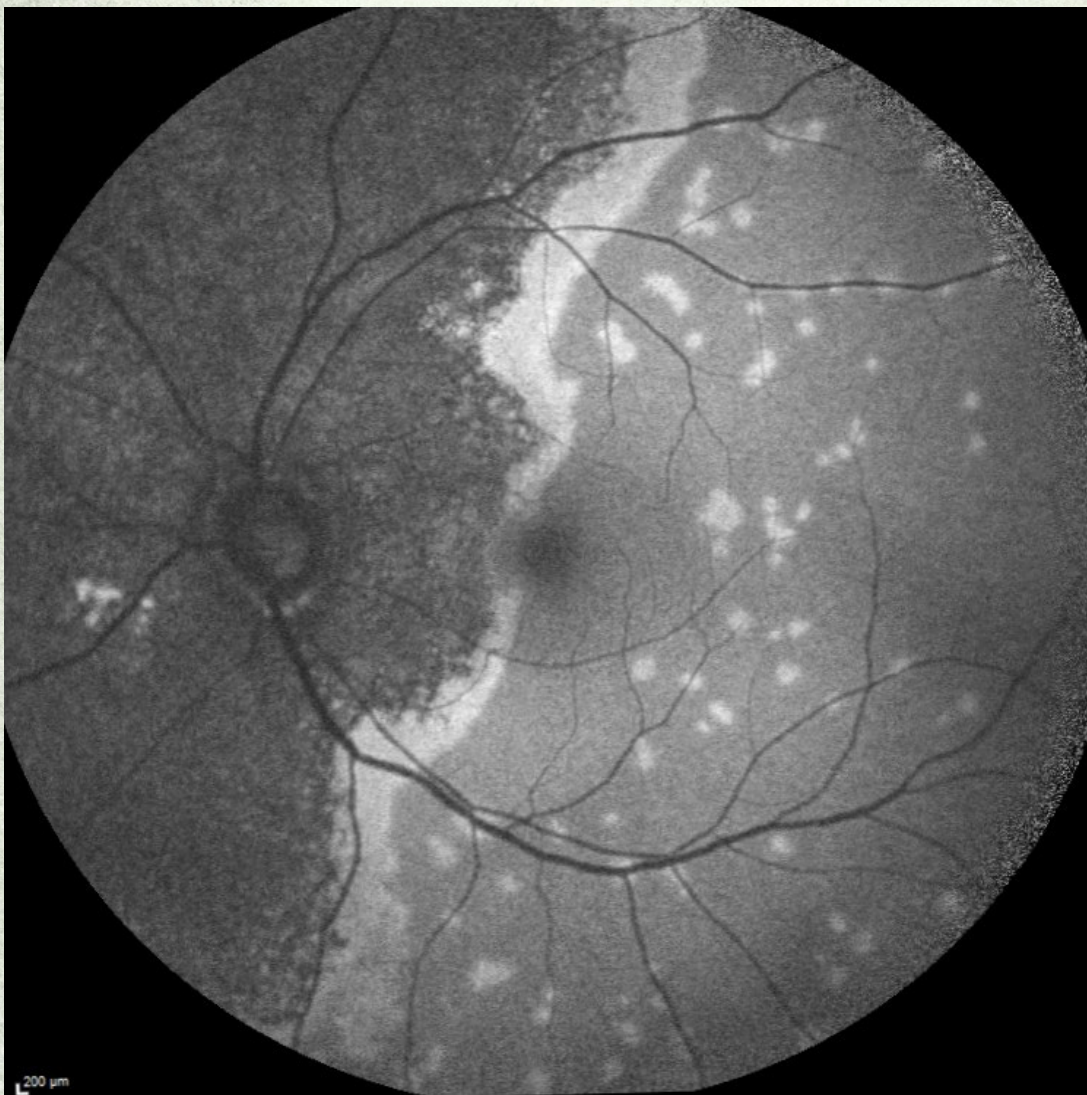### Navigating the Nexus: Exploring AZOOR and MEWDS in Tandem



**Dr. Radhika Sriram, DNB**

Uvea fellow, Narayana Nethralaya, Bengaluru

*radhikasriram01@gmail.com*



## The Three Zones of AZOOR



**Dr. Raaja Ganesh M**, MBBS, MS (Ophthal), FMRF  
Associate consultant in Medical Retina  
Sankara Nethralaya, Chennai



**Dr. Rajiv Raman**, MS, DNB, FRCS'Ed, DSc  
Senior Consultant, Sankara Nethralaya, Chennai  
[rajivpgraman@gmail.com](mailto:rajivpgraman@gmail.com)

### What is AZOOR?

As the name suggests, Acute Zonal Occult Outer Retinopathy (AZOOR) is an outer retinopathy that occurs in a particular zone of the retina, especially around the optic disc, with acute onset symptoms of photopsia and visual field defects. It was first described by J. Donald M. Gass in 1992(1). AZOOR is a progressive disease with the initial presentation of a relatively normal fundus appearance. It gradually progresses to outer retinal/retinal pigment epithelium (RPE) atrophy, arteriolar narrowing, and eventually choroidal atrophy. There will be corresponding areas of visual field loss along with specific electroretinogram (ERG) abnormalities. It is usually unilateral, though bilateral presentations are also not uncommon.

AZOOR is a part of the white dot syndrome. The actual cause of the disease is still not identified, but recent studies revealed that it could be viral or immune-mediated.

Patients with AZOOR can present in two phases of clinical scenarios - in the acute phase, or in the subacute/ chronic phase.

In the acute phase, the predominant symptoms include photopsias, sudden visual loss especially of the central vision. However, in the subacute/ chronic phase, the predominant symptoms are mainly peripheral visual field defects.

The disease has been regarded to be associated with viral infection, though no specific viruses have been isolated. Many patients who developed AZOOR have a viral illness in the preceding period of visual loss. AZOOR has also been associated with autoimmune diseases(2,3). To support the autoimmune hypothesis, a study by Forooghian et al. (4) demonstrated the presence of anti-retinal antibodies in almost all patients in the study group. Anti-retinal antibodies like recoverin, -enolase, carbonic anhydrase II, and collapsin response-mediated protein 5 (CRMP5) have been found in patients with AZOOR. However, as anti-retinal antibodies are not a very specific indicator of autoimmune disease, the pathogenesis remains unclear. Though the pathogenesis is still not very well understood, immune suppression and oral steroids remain the mainstay of treatment for patients with AZOOR.

## Multimodal Imaging in AZOOR

Imaging plays a crucial role in diagnosing and managing patients with AZOOR. Fundus photo or imaging is done to document and follow-up the disease. In the early stages, the fundus often looks normal. It rapidly progresses to the appearance of a grey-white line of demarcation at the junction of the normal retina and the affected retina. This area is usually along the posterior pole and involves the disc.

of patients with AZOOR. It is invariably the most crucial investigation with some pathognomonic findings. Fundus autofluorescence demonstrates the presence of lipofuscin in the retinal pigment epithelial cells. The excessive presence of lipofuscin indicates increased metabolism in the RPE, which in turn translates to the stressed-out RPE, detected as hyper-autofluorescence. Similarly, an atrophic RPE has no metabolic activity and thus lacks the presence of lipofuscin which is detected as hypo-autofluorescence.

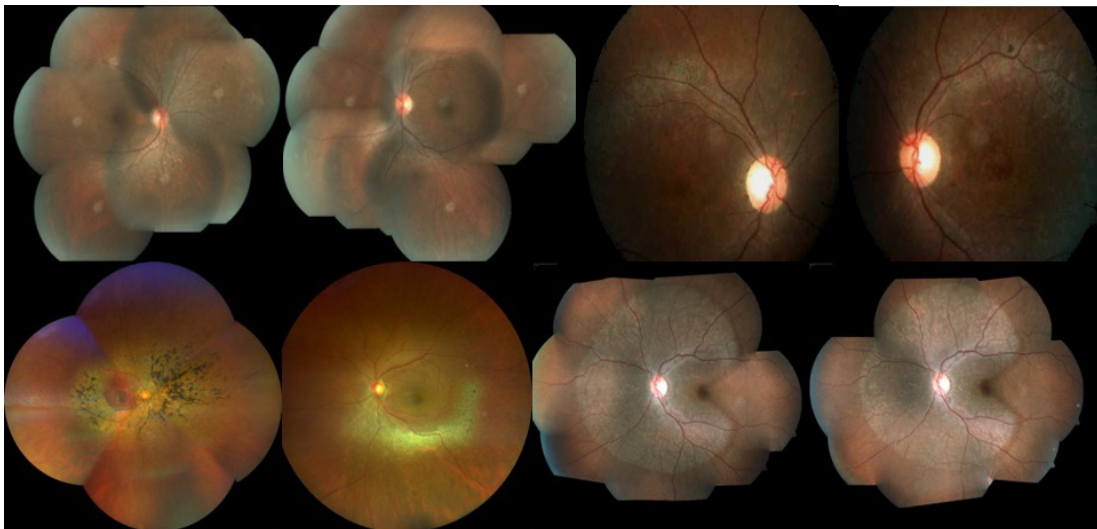

Figure 1: Varied clinical presentations of AZOOR

shows the varied retinal presentations of AZOOR. Hence, this has to be differentiated from acute idiopathic blind spot enlargement syndrome (AIBSE), which mimics AZOOR. Patients with AIBSE also usually have a relative afferent pupillary defect and dyschromatopsia, unlike AZOOR, in which pupillary reactions are almost always normal(5). Usually, the transition between cases of AIBSE and AZOOR has also been reported over years. It is still being determined whether both diseases are independent entities or whether they are both various stages of the same disease(6). In the sub-acute or chronic stages of the disease, the fundus appearance has a patch of RPE atrophy around the peripapillary region.

The FAF in the initial or acute stage of the disease has an obvious demarcation line of hyper-autofluorescence in the peripapillary area. At this stage, the RPE is stressed, and the entire affected area appears as hyper-autofluorescence with a speckled pattern. This distinction can be identified much earlier than the clinical appearance of the demarcation line. As the disease progresses, the autofluorescence takes a characteristic trizonal pattern. The three zones of autofluorescence in FAF include the normal FAF in the unaffected retina, the speckled hyper-autofluorescence demarcation line at the junction of the normal and the affected retina and the hypo-autofluorescence in the affected retina in the peripapillary region representing the atrophy of the RPE.

## Fundus Autofluorescence

Fundus Autofluorescence (FAF) has a vital role in the diagnosis and follow-up




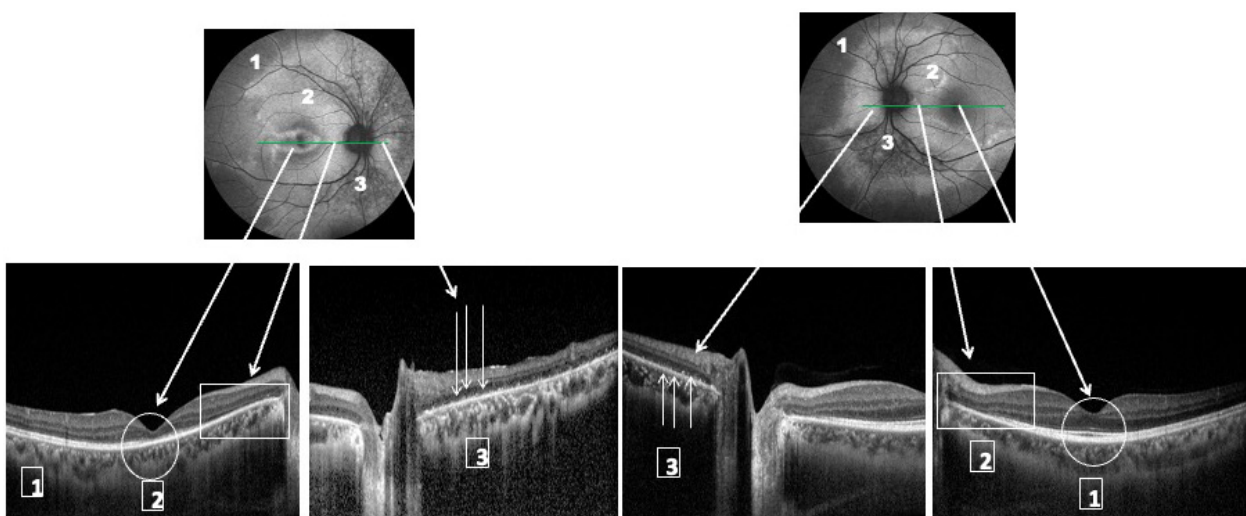
Figure 2: Trizonal pattern on autofluorescence in AZOOR

In the late stage of the disease, the entire affected retina appears as a well-defined peripapillary hypo-autofluorescent region. Since the area involved in AZOOR is typically large, a widefield fundus autofluorescence demonstrates the entire involved area much better than that seen on standard fundus autofluorescence, wherever available.

### Optical Coherence Tomography

Optical Coherence Tomography (OCT) is another modality which has features corresponding to the trizonal pattern of autofluorescence. This gives information about the structural changes occurring in the outer retina, unlike autofluorescence,

which gives information about the functional status. Apart from the retinal pigment epithelial changes, there are almost always changes in the ellipsoid layer. In the initial stages, there is disruption of the ellipsoid zone. The changes on OCT gradually progress to the typical three zones or the Trizonal pattern: Zone 1 being the normal retina, corresponds to the normal FAF, the zone 2 is the area of the beginning of the ellipsoid layer defect, which presents as multiple mound-like hyperreflective material in the sub-retinal space. This corresponds to the speckled hyper-autofluorescence of the demarcation line on FAF. Zone 3 corresponds to the area of RPE atrophy.



1: Normal, 2: EL defects 3: Area of RPE atrophy

Figure 3: Trizonal pattern on autofluorescence and OCT in AZOOR

There is also associated choroidal degeneration and thinning of the outer nuclear layer followed by the inner nuclear layer.

**Visual Fields:** Visual fields are similar in the early and the late stages of the disease showing visual field loss. In the early stages of the disease, as the disease is predominantly peripapillary, visual fields show enlargement of the blind spot. This finding is also seen in acute idiopathic blind spot enlargement syndrome, papilledema or retrobulbar optic neuritis which commonly mimic AZOOR and therefore, need to be ruled out.

### **Electrophysiology**

Electrophysiology is invariably abnormal in patients with AZOOR. The presence of the symptom of photopsia can initiate the ophthalmologist to perform an electrophysiological test for the retina to understand its function. Though clinically, the area involved in AZOOR is focal, electrophysiological evidence suggests generalized retinal dysfunction. Cases have been reported where clinical findings of AZOOR were detected only in one eye, but the electroretinogram (ERG) showed changes in both eyes(7). Typical ERG findings in AZOOR include the reduction in the amplitudes of the Dark Adapted Rod specific responses with no delay in the latency, delayed implicit times of the 30 Hz Flicker response with a corresponding reduction in the amplitudes. The pattern ERG usually shows a decrease of the P50 component with no change in the P50:N95 ratio, demonstrating a macular dysfunction. Multifocal ERG reflects a reduction in the amplitudes of the responses corresponding to the area of hypo-autofluorescence, indicating localized retinal dysfunction. The most important electrophysiological finding in AZOOR, which is not seen in other diseases, is the absence of light rise in an electro-oculogram (EOG), which indicates RPE dysfunction. The characteristic ERG finding of delayed and reduced 30 Hz Flicker response with an absent light rise on EOG clinches the diagnosis of AZOOR. However, electrophysiological testing is not done

routinely in many clinical settings because the diagnosis can easily be made on the pathognomonic findings of other commonly available imaging modalities.

### **Angiography**

Fundus Fluorescein Angiography (FFA) usually shows staining of the RPE in the affected retina which progresses to RPE window defects corresponding to the areas of RPE atrophy. Indocyanine green angiography (ICGA) may show a trizonal pattern in which the zone 1 shows a normal fluorescence – outside the affected area, zone 2 shows late extra choroidal leakage and zone 3 shows hypo-fluorescence corresponding to the atrophy of choriocapillaris.

### **Prognosis and Treatment**

Since the pathogenesis of the disease is poorly understood, several treatments like systemic corticosteroids and immunosuppressive therapy have been tried in patients with AZOOR but there is no consensus regarding the effectiveness of the treatment. Spontaneous remissions of the disease without treatment have also been reported. The prognosis of the disease remains poor as the visual field defects are permanent and the disease is progressive.

### **Differential Diagnosis**

The diagnosis of AZOOR can be made easily by the characteristic findings on multimodal imaging. However, there are certain mimickers of the disease, especially in the early stages when the characteristic trizonal pattern has still not set in. The differentials include retrobulbar optic neuritis, which has relative afferent pupillary defects and normal fundus appearance with a normal fundus autofluorescence. The OCT will also be relatively normal, unlike the ellipsoid layer defects seen in the early stages of AZOOR.

Acute retinal pigment epitheliitis (ARPE) is another differential diagnosis where there are OCT changes of RPE hyper-reflectivity

and ellipsoid layer changes, but the affected area is usually in the foveal or parafoveal region, unlike the peripapillary region in AZOOR. ARPE is self limiting, shows rapid resolution and vision returns to normal once the disease resolves, unlike AZOOR where there are long-standing or persistent visual field defects corresponding to the affected retina.

Multiple Evanescent white dot syndrome (MEWDS) is characterized by the presence of yellow-white dots in the deeper layers of the retina in the posterior pole and spots in the mid periphery, which are hyper-autofluorescent on FAF. There is no demarcation line, unlike AZOOR, and is usually self-limiting with good visual recovery.

	AZOOR	AIBSE	ARPE	MEWDS
<b>Clinical Presentation</b>	Photopsias, visual field defects (peripheral in late stage)	Relative afferent pupillary defect, dyschromatopsia, enlarged blind spot	Foveal/parafoveal involvement, rapid resolution of symptoms	Photopsias, dyschromatopsia, paracentral scotoma
<b>Clinical Fundus Appearance</b>	Initially normal, later grey white demarcation line, and then atrophy	Normal fundus with mild optic disc abnormalities	Fine pigment stippling with yellow-white halo in the macular region	Yellow-white dots in posterior pole and mid-periphery region
<b>Autofluorescence (FAF)</b>	Trizonal pattern (hyper-autofluorescent demarcation line, hypo-autofluorescence in affected retina)	Normal FAF	Hyper-autofluorescence due to RPE changes	Hyper-autofluorescent dots on FAF
<b>OCT Appearance</b>	Trizonal pattern, Ellipsoid layer defects, RPE atrophy corresponding to hypo-AF pattern of affected retina	Normal	RPE changes, ellipsoid layer defects corresponding to FAF pattern	White dots in deeper retinal layers, hyper-reflectivity on OCT
<b>Visual Fields</b>	Enlarged blindspot, central or paracentral scotoma	Enlarged Blind Spot	Decreased central threshold	Enlarged blindspot, central or paracentral scotoma
<b>Electrophysiology</b>	Reduced amplitudes of DA Rod Specific responses with normal latency, delayed implicit times of 30Hz flicker, reduced P50 with normal P50:N95 ratio, reduced Ardens ratio on EOG	Decreased peri-foveal responses on mf-ERG	Decreased foveal responses on mf-ERG, Reduced Ardens ratio on EOG	Reduced a wave amplitude, reversible reduction of Ardens ratio on EOG
<b>Course and Prognosis</b>	Progressive outer retinal/RPE atrophy, persistent visual field defects	Self-limiting with spontaneous resolution of symptoms	Rapid resolution with return to normal vision upon resolution	Self-limiting with good visual recovery
<b>Differentiation</b>	Trizonal pattern helps differentiate from other retinal disorders	Normal fundus appearance, disease course distinguishes	Location of affected area (peripapillary vs. foveal/parafoveal) and course	Fundus appearance and course of disease differentiate from AZOOR

## Conclusion

AZOOR is a predominantly unilateral disease of young women with presumed inflammatory or auto-immune pathology. It is easily diagnosed with multimodal imaging, with the characteristic Trizonal pattern on fundus autofluorescence and OCT. It is essential to differentiate AZOOR from other diseases in the same spectrum.

## Bibliography

1. Tavallali A, Yannuzzi LA. Acute Zonal Occult Outer Retinopathy; Revisited. *J Ophthalmic Vis Res.* 2015;10(3):211–3.
2. Gass JD, Agarwal A, Scott IU. Acute zonal occult outer retinopathy: a long-term follow-up study. *Am J Ophthalmol.* 2002 Sep;134(3):329–39.
3. Elsevier Asia Bookstore [Internet]. [cited 2024 Mar 5]. Ryan's Retina: 7th edition | Edited by Srinivas R. Sadda | ISBN: 9780323722131. Available from: <https://www.asia.elsevierhealth.com/ryans-retina-9780323722131.html>
4. Forooghian F. Prevalence of Antiretinal Antibodies in Acute Zonal Occult Outer Retinopathy: A Comprehensive Review of 25 Cases. *Am J Ophthalmol.* 2017 Jul;179:210–1.
5. Volpe NJ, Rizzo JF, Lessell S. Acute idiopathic blind spot enlargement syndrome: a review of 27 new cases. *Arch Ophthalmol Chic Ill 1960.* 2001 Jan;119(1):59–63.
6. Yang JY, Rizzo J, Sobrin L. AIBSE, AZOOR and MEWDS: Longitudinal Clinical Comparison and Documentation of Conversion. *Invest Ophthalmol Vis Sci.* 2022 Jun 1;63(7):2528-A0097.
7. Francis PJ, Marinescu A, Fitzke FW, Bird AC, Holder GE. Acute zonal occult outer retinopathy: towards a set of diagnostic criteria. *Br J Ophthalmol.* 2005 Jan;89(1):70–3.



## Case Contest Winner

### Connecting the White Dots to Reveal What Lies Beneath!



**Dr. Nidhi Dubey**, DO DNB FAICO  
Consultant, Sankara Eye Hospital, Bengaluru  
[nidhiparagdubey@gmail.com](mailto:nidhiparagdubey@gmail.com)

We present a case of 23 year old male who came with c/o metamorphopsia in Left eye since 1 week. The only other significant history was that of high myopia in family.

On examination, his BCVA was 6/9(p) in RE and 6/24(p) in LE with a subjective refraction as follows:

RE : -17.00DS/-0.75DC \*180 6/9p

LE: -18.00DS/-2.50DC \*180 6/24p

Anterior segment findings were within normal limits.

Fundus examination showed the patient had a myopic fundus with peripapillary atrophy. Left eye showed two depigmented punched out lesions at macula, one superior to fovea and other inferotemporal to fovea.

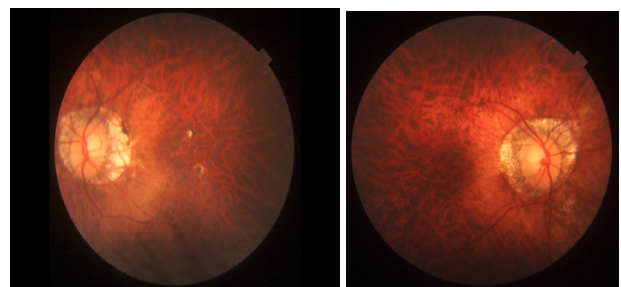


Figure 1. : Fundus photo of both eyes at presentation.

Radial OCT was done for both the eyes. The OCT of left eye passing through both the lesions was done as shown in figure 2. The OCT findings in the right eye was within normal limits (figure 3).

An FFA + ICG angiography was planned for the patient and findings were consistent with a diagnosis of PIC as shown in figure 5.

A diagnosis of Punctate inner choroidopathy was made and patient was started on oral steroids in tapering dose starting at 80mg/ day.

On subsequent follow up, patient was symptomatically better, and the steroids were tapered. The PIC lesions showed resolution and the OCT image at 3 weeks follow up is shown in figure 6. vision in RE was 6/9(p) and LE was 6/12.

The patient presented 7 weeks later with worsening scotoma. The OCT of the left eye at this visit is shown in figure 7 and the corresponding OCTA in figure 8. A diagnosis of active CNVM was made and patient was given Intravitreal Ranibizumab.

Post injection the vision improved to 6/9. The post injection OCT is as shown in figure 9.

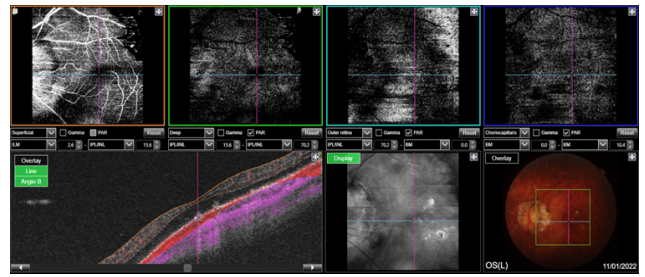


Figure 4: showing OCTA of Left Eye which did not show any network on outer retinal slab.

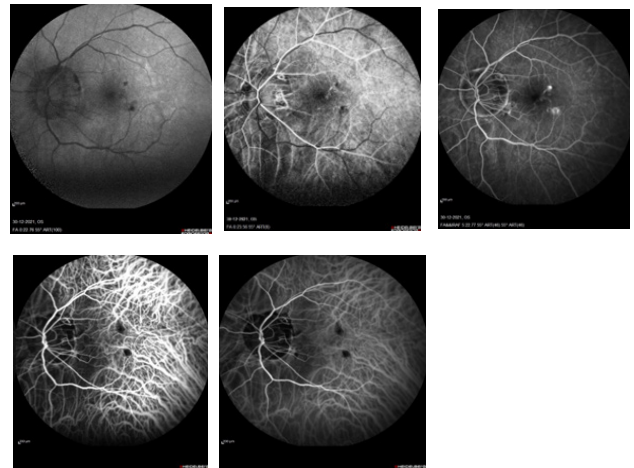

Figure 5: 5a. shows FFA – early phases showed hypofluorescence and late phases showed hyperfluorescence of the lesions.

5b. shows corresponding ICGA of the left eye which showed hypofluorescence in all phases of the angiography.

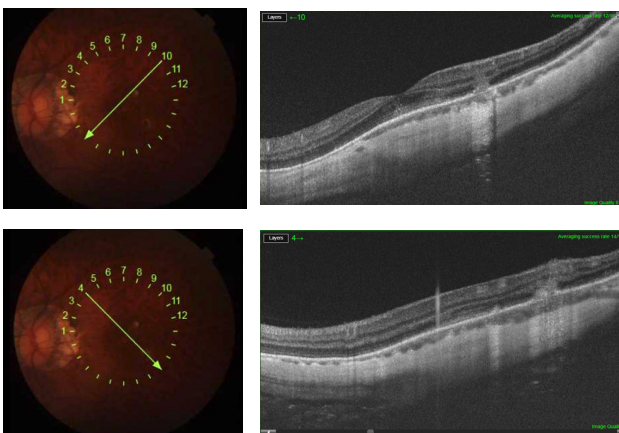


Figure 2a. : OCT through lesion superior to fovea showing hyperreflective dots and fuzziness in outer retina at fovea.

Figure 2b.: OCT through lesion inferotemporal to fovea.

Both lesions showed hyperreflectivity overlying area of loss of ellipsoid zone and RPE hyper transmission as below

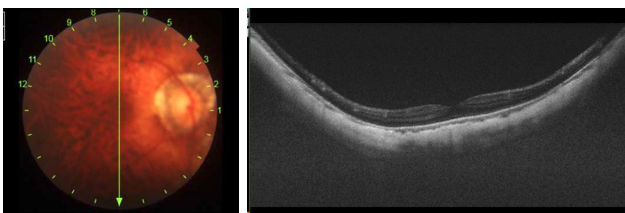


Figure 3: showing OCT of Right Eye which was found to be normal.

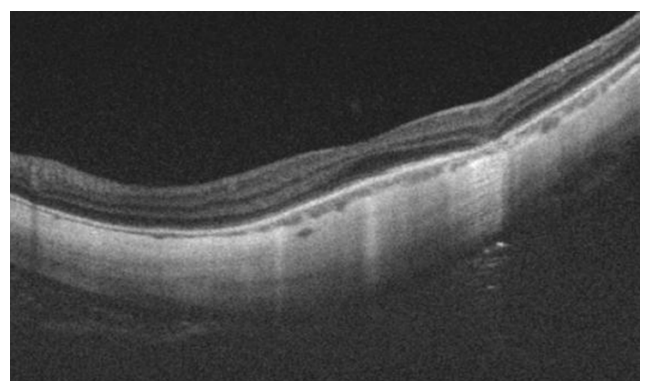


Figure 6. : OCT of the left eye at 3 weeks follow up showing resolution of PIC lesions - decrease in hyperreflectivity of outer retinal layer at fovea which was noted earlier at the initial visit. Hypertransmission was also noted to be increased

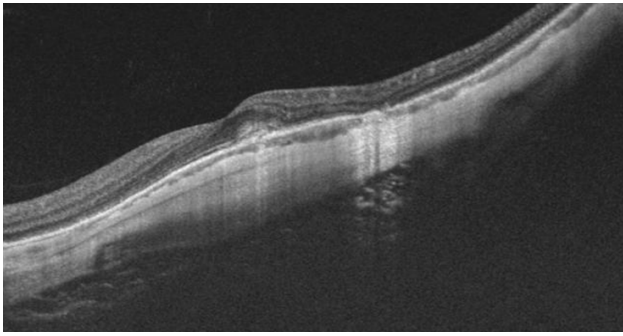


Figure 7. : OCT of the left eye at 7 weeks follow up with RPE elevation with subretinal hyperreflectivity in outer retinal layers and below the RPE.

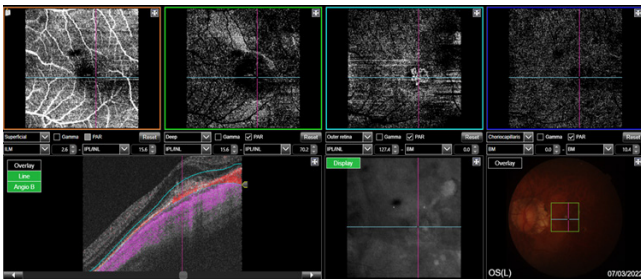


Figure 8: OCTA of the left eye at 7 weeks follow up with branched vascular network seen in outer retinal slab

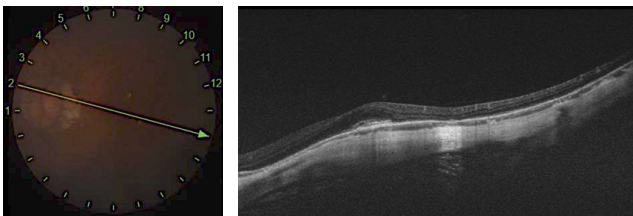


Figure 9: post injection OCT of the left eye.

## Conclusion:

PIC is commonly seen in young myopes. Myopes are also at a risk of developing myopic CNVM. With the current advent of multimodal imaging having enhanced our understanding of structural and functional characteristics of retinal anatomy and pathology, it has become possible to differentiate etiology of CNVM in myopic patients with PIC. The presence of CNVM in myopes results in hypo reflective back shadowing behind the lesion, whereas in inflammatory PIC lesions, as in our case, there is iso- or hyper transmission below the hyperreflective material, as has been described in literature<sup>1</sup>.

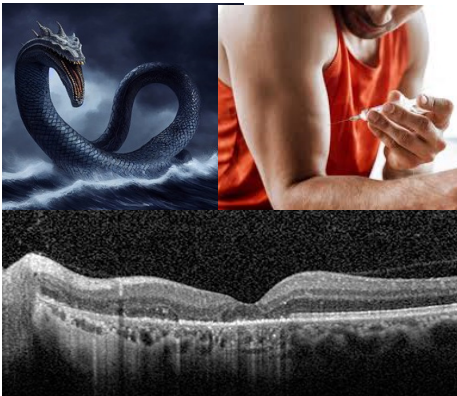## References:

1. Agarwal A, Handa S, Marchese A, Parrulli S, Invernizzi A, Erckens RJ, Berendschot TTJM, Webers CAB, Bansal R, Gupta V. Optical Coherence Tomography Findings of Underlying Choroidal Neovascularization in Punctate Inner Choroidopathy. *Front Med (Lausanne)*. 2021 Dec 22;8:758370. doi: 10.3389/fmed.2021.758370. PMID: 35004727; PMCID: PMC8727437.

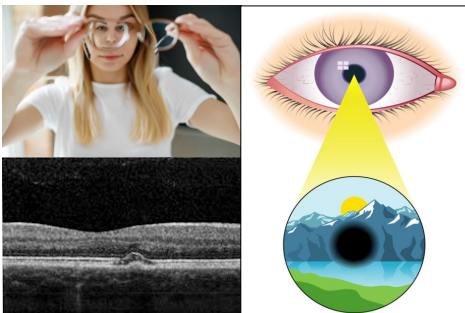
# Out of the Box: Puzzle Corner



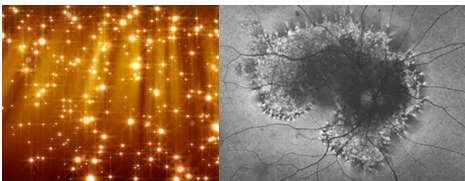
**Dr. Dhaivat Shah, MS, DNB, FMRF**  
Joint Medical Director, Choithram Netralaya, Indore.  
*dhaivatkshah@gmail.com*



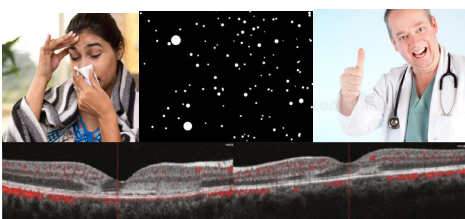
**1. GUESS THE DISEASE**




**2. GUESS THE DISEASE**



**3. GUESS THE DISEASE**



**4. GUESS THE DISEASE**



**5. GUESS THE DISEASE**

## The Decade Gone By: Recent Literature Review



**Dr. Vidya Mooss, DNB**

Consultant Medical Retina and Uvea Prabha Eye Clinic and  
Research Centre, Bengaluru  
*vidmooss123@gmail.com*

**T**he White Dot Syndromes (WDS), previously known as "multifocal inflammatory chorioretinopathies", represent a collection of inflammatory chorioretinal conditions with unknown etiology that affect the outer retina, retinal pigment epithelium (RPE), or choroid, either singly or in combination, and may involve one or both eyes and is seen mostly in people aged 20 to 60 years (1). The disorders classified under this umbrella term are simply based on the resembling appearance of the fundus features and also due to the lack of imaging modalities to image the choroid in the past. The advent of ICGA in the mid-1990s, allowed researchers to investigate the choroid more precisely and understand the clinico-pathological mechanisms of choroidal inflammatory diseases. ICGA allowed to sort out diseases predominantly involving the choroidal stroma, (Vogt-Koyanagi-Harada, birdshot retinochoroiditis) and those that involved predominantly the choriocapillaris (MEWDS, APMPE, MFC and SC).

Over the past decade, significant advancements have been made in understanding the pathogenesis, clinical spectrum, and treatment options for WDS, leading to improved patient outcomes.

For this review, a comprehensive search of the PUBMED database was conducted using keywords such as "white dot syndromes," "acute posterior multifocal placoid pigment epitheliopathy (APMPPE)," "serpiginous choroiditis," "multiple evanescent white dot syndrome (MEWDS)," "punctate inner choroidopathy (PIC)," "Multifocal choroiditis(MFC)" and "Acute zonal occult outer retinopathy (AZOOR)." The search was limited to articles published in the past 10 years (January 2014-December 2023) to ensure inclusion of the most recent research and clinical findings on WDS. The reference lists of selected articles were also reviewed to identify additional relevant studies. A total of 73 articles were included in this review.

## **Multiple Evanescent White Dot Syndrome (MEWDS)**

MEWDS was first described in 1984 as a unilateral, acute-onset, evanescent condition that presents with small clusters of discrete white dots most prominent in the perifoveal region and associated with a granular appearance of the fovea. Several publications, past and present, classified MEWDS in the subgroup of primary inflammatory choriocapillaropathies. (2,3) However, recent reports indicate that the choriocapillaris are intact on OCTA. Hence these reports concluded that the only damaged structure was the outer retina.(4-8) In 2016, Pichi et al proposed the concept of primary "photoreceptoritis, where they proposed that the disease primarily involves the photoreceptors' inner and outer segments.(4)

Recent studies using adaptive optics scanning laser ophthalmoscopy (AOSLO) and en-face OCT reconstructions have confirmed that MEWDS primarily affects the outer segments of photoreceptors, with relatively preserved inner segments.(4,9,10) Advanced SD-OCT prototypes with higher axial resolution have suggested possible primary involvement of the interdigitation zone (IZ) during the acute phase (11) However, this theory was opposed by Lages et al who proposed that since MEWDS is an end-capillary disease with very slow flow in tiny capillaries, lack of abnormalities in OCT-A is because the lack of sensitivity of OCT-A in detecting fine choriocapillaris non-perfusion areas, while ICGA is able to detect non-perfusion by showing ICG hypofluorescence. (12)

Khochtali et al demonstrated that choriocapillaris dropout were seen depending on the extent/severity of involvement when analysed by swept source OCT-A. (13) Moreover, there is a variability in the degree of choriocapillaris involvement in MEWDS depending on the severity.(13,14)

Additionally, a subset of cases termed 'MEWDS-like' reactions has been described in more recent literature, occurring in conjunction with other ocular pathologies, possibly exposing retinal, RPE, and Bruch membrane antigens to the immune system. Various terms have been used to describe these reactions, including secondary MEWDS, epiMEWDS, and acute retinopathy. (15-20)

## **Acute Posterior Multifocal Placoid Pigment epitheliopathy (APMPPE)**

First described by Gass in 1968, APMPPE is characterized by multiple whitish-yellow inflammatory lesions at the outer retina, RPE, and choroid (21) The etiological mechanisms proposed by various studies include association with infective disease (viral prodrome), positive TB immunological tests, autoimmune disorders, HLA B7 and DR2 association and association with vaccinations. (22-24)

It was initially thought that the primary pathology is at the level of RPE. However, multimodal imaging techniques have shown that it is currently included in the group of choriocapillaritis diseases. Although the ophthalmic findings may reflect RPE involvement, accumulating evidence indicates that the primary lesion is beneath the RPE and choroidal perfusion is affected. Outer retinal damage is secondary

to ischemic changes in the choriocapillaris. (21,25-27) Hence some authors suggest use of the term choroidopathy rather than epitheliopathy.(28) Recent studies have also described choriocapillaris reperfusion using OCTA, where they observed reperfusion in centripetal pattern from the outer edge of the APMPE lesions.(26,29)

The common denominator of primary inflammatory choriocapillaropathies is the dysfunction of the choriocapillaris perfusion of variable severity with grading from small end-capillary nonperfusion in MEWDS to progressively more proximal capillary involvement in MFC, APMPE and SC. (30) Treatment of APMPE also remains controversial. Currently corticosteroids are recommended in vision threatening lesions and where systemic manifestations are present.

Xeri et al showed in their case series that untreated patients with APMPE can have a favourable outcome.(31) However other recent studies reported incomplete visual recovery even after treatment. (32)

### **Serpiginous choroiditis (SC)**

The prevalence rates of SC in Southeast Asian countries were found to be higher than in other parts of the world. A possible role of various infectious etiologies has been implicated in the relative higher incidence of SC in these regions. (33, 34, 35, 36)

During the COVID-19 pandemic, cases of choroiditis/ SC have been reported in patients infected with COVID-19, supporting the theory that viral infections may play a role in triggering chorioretinal inflammation in susceptible individuals (37)

Occlusion of choriocapillaris has been attributed to the etiopathogenesis of SC. The various mechanisms suggested for this are immune-mediated vasculitis and the role of endothelial injury caused by a vasculitis-induced vaso occlusion.

Serpiginous like choroiditis is believed to be due to immunological reaction by M. tuberculosis, which is believed to be sequestered in the RPE. The term “serpignoid” and “multifocal serpignoid choroiditis (MSC)” have also been used to refer this clinical entity.(38)

In a study conducted in North India, Bansal and colleagues utilized multiple molecular techniques, including multitargeted polymerase chain reaction (PCR) analysis, Gene Xpert MTB/RIF assay, and the line probe assay (MTB DR plus assay), to isolate mycobacterial DNA from vitreous fluid samples obtained during diagnostic pars plana vitrectomy in patients with active MSC and latent tuberculosis. This highlighted the role of autoimmunity in the pathogenesis of ocular tuberculosis. (39) Autoreactive T cells were isolated from vitreous samples of patients with tubercular uveitis, including those with MSC. These T cells demonstrated resistance to activation-induced cell death, suggesting a complex interplay between autoimmunity and infection in the context of ocular tuberculosis. (40)

### **Multifocal choroiditis and Punctate inner choroidopathy**

MFC and PIC was initially described as two separate entities, where the difference being only the size and location of lesions and presence/absence of vitritis. MFC and PIC share similar clinical presentations, such as field defects, photopsias, scar appearance, peripapillary location, tendency toward

bilateral involvement, and frequent development of CNVM.( 41) Some of the recent literature consider PIC synonymous with MFC. (42) A study by Spaide et al. found no distinguishing features in outer retinal and sub-RPE involvement between MFC and PIC on imaging modalities and hence concluded that eyes with active disease are treated similarly regardless of classification as MFC/ PIC, suggesting little clinical utility in differentiation. (43)

With the use of SSOCT, the newly recognized OCT features include focal hyporefectivity and loss of the normal choroidal architecture below the active lesion, splitting of the RPE/ Bruch's membrane, posterior deflection of the bruch's membrane, and intraretinal cavitation in the restoration stage. (44) These findings support the hypothesis that the inflammatory process primarily affects the RPE/Bruchs complex. However, the exact site of inflammation remains unknown, and it is uncertain whether inflammation originates from the RPE/Bruchs complex or the choriocapillaris. The contribution of the choroid to the pathogenesis of PIC/MFC is also uncertain.

EDI OCT has revealed focal variations in choroidal thickness, with acute lesions demonstrating choroidal thickening and resolved lesions showing choroidal thinning. (45) In patients with active inflammatory lesions, OCTA can provide valuable insights by revealing choroidal flow voids that tend to normalize when the inflammation subsides. (46) OCTA also helps detect CNVM, as active PIC/MFC lesions and secondary CNV can present similar findings on OCT and FA.(47,48). Additionally, OCTA enables the detection of centripetal restoration of the choriocapillaris flow signal after immunosuppressive therapy.(49,50)

Association of PIC/MFC lesions with pachychoroid spectrum has been described in recent literature, where they used the term "punctate inner pachychoroidopathy". The authors hypothesized that abnormal choroidal venous outflow predispose to or enhance local inflammation.(42)

Cicinelli et al. described active PIC like lesions in patients with other chorioretinal diseases (Pseudoxanthoma elasticum, angioid streaks, rod-cone dystrophy, ARMD, chorioretinal rupture, toxoplasmic retinochoroiditis, and Stargardt disease) where it is called secondary PIC. Secondary PIC differs from primary in age, gender, laterality, prodromes, and refractive errors. (51)

### **Acute Zonal Occult Outer Retinopathy (AZOOR)**

AZOOR is a rare inflammatory disease primarily affecting young myopic females, characterized by dysfunction of the outer retina.(52) It is hypothesized that the inflammatory ocular manifestations may result from a combination of genetic predisposition to autoimmune diseases, environmental triggers, and immune pathways.(53)

AZOOR is thought to be part of a broader range of diseases with overlapping features, including MEWDS, Acute Idiopathic Blindspot Enlargement Syndrome (AIBSE), and Acute Macular Neuroretinopathy (AMN). However, the absence of a specific fundus biomarker has made it difficult to precisely define AZOOR, leading to variability in the cases reported in the literature. As a result, AZOOR has become a general term for chorioretinal diseases with uncertain causes of visual loss.

In the original description of AZOOR by Gass, 90% of the patients had normal fundus findings. However several imaging characteristics have been described recently. Outer retinal thinning, EZ loss, and RPE irregularities on OCT, diffuse hyperautofluorescence or coarse granular regions of mixed hyper and hypo autofluorescence are the various OCT features described. (53)

In an effort to improve the diagnosis of AZOOR using multimodal imaging findings, Mrejen et al. proposed a new classification system that focuses on identifying significant, progressive retinal changes involving the outer retina, retinal pigment epithelium (RPE), and choroid, where the clinical presentation can be either early/acute or subacute/chronic. (54) In early (acute) presentation patients will have acute symptoms and a macular-sparing zonal defect with little reduction in visual acuity and a normal-appearing fundus. FAF imaging reveals diffuse patchy hyperautofluorescence, which may progress over time. In subacute/chronic form, most eyes exhibit a demarcating line between the involved and uninvolved retina, which is best visualized in FAF imaging, showing marked hyperautofluorescence. OCT shows diffuse loss of photoreceptors within the zonal defect, with relative preservation at the fovea. Subacute forms show progression which was defined by an expansion of the demarcating line and enlargement of the lesion size. It can be seen from posterior pole to peripheral fundus, sometimes even involving the entire fundus, and there will be disruption of the inner and outer retina and severe damage or loss of the RPE and the choroid.

This subacute form demonstrates a trizonal pattern in multimodal imaging (FAF, SD-OCT and ICG). In FAF, normal AF is seen

outside the lesion(zone 1), speckled AF within the lesion (zone 2) and hypo AF seen inside due to chorioretinal atrophy(zone3). SD-OCT shows normal appearance outside the AZOOR lesion (zone1). There is presence of multifocal material in the subretinal space resembling subretinal drusenoid deposits inside the lesion(zone 2). Photoreceptor, RPE, and choroidal atrophy is seen in the more advanced or long-standing area of the lesion (zone 3). ICGA shows normal appearance outside lesion (zone1), AZOOR lesion area shows minimal late extra choroidal leakage (zone 2) and hypofluorescence corresponding to choriocapillaris atrophy (zone 3).

En-face OCTA images reveal hyper-reflective dot structures leading to a "starry-sky" appearance in the outer retinal slab. These hyper-reflective dots represent degenerating photoreceptor segments. (55) Recent studies on AOSLO reveal cone loss with increased spacing in the regions corresponding to EZ/IZ abnormalities and visual field loss.(56,57)

The diagnosis of AZOOR involves ruling out other related conditions such as autoimmune retinopathies and syphilitic outer retinopathy. Autoimmune retinopathy often presents with a broader area of outer retinal loss than AZOOR, without signs of inflammation. Syphilitic outer retinopathy may exhibit phlebitis on FFA in the active outer retinitis area, which can help differentiate it from AZOOR. Therefore, patients suspected of having AZOOR should be tested for syphilis. (52,58) Ultra-widefield fundus color and FAF imaging can be particularly useful in distinguishing AZOOR from inherited retinal dystrophies. (59)

There are a few reports of CNVM complicating the course of AZOOR, which are treated with intravitreal anti-VEGF agents. However, some authors have observed progression of AZOOR during anti-VEGF treatment.(60) It remains unclear whether the progression is accelerated by anti-VEGF treatment or is attributable to the natural course of the disease.

Currently, no definitive treatment for AZOOR has been established. While systemic corticosteroids have been used with varying success, intravitreal injections of sustained-release corticosteroid devices have shown promise in inactivating the active edge in AZOOR (61). Antivirals and systemic immunosuppressants have also been employed with mixed results.(42,62)

### **Ampiginous choroiditis or Relentless Placoid Chorioretinitis (RPC):**

Relentless placoid chorioretinitis (RPC) first described by Jones et al in 2000, is a rare chronic, relapsing inflammatory disease of RPE and choroid. RPC is included in the spectrum of choriocapillaritis. Due to its similarities with SC and APMPE, it is also termed as ampiginous choroiditis.(63,64) Its differentiating features from these 2 entities are the location (anterior and posterior to equator) and number of lesions (usually >50 lesions). Presence of active and healed lesions at the same time with a prolonged and relapsing course is described as the hallmark of RPC. (38)

Infectious or autoimmune factors are thought to be the contributing pathogenic mechanisms involved. Hwang et al in their recent report showed that, systemic illnesses like thyroiditis and cerebral vasculitis can be associated with RPC.(65) During the COVID-19 pandemic, cases of choroiditis, APMPE, SC, and RPC have been reported

in patients infected with COVID-19, which may further support the theory that viral infections may play a role in triggering chorioretinal inflammation in susceptible individuals. (66-68)

The clinical course is prolonged with recurrences occurring months to years after the initial presentation. (63,69) Study by Klufas et al based on OCTA has shown that the inner choroid is the primary site of disease pathogenesis in RPC, similar to that seen in APMPE. The primary involvement of choriocapillaris leads to secondary damage to RPE and outer retina. They concluded that monitoring changes in choroidal flow with OCTA may provide an important biomarker of active disease and therapeutic response. (70)

Dolz-Marco compared macular retinal and choroidal thickness in the eye with RPC and compared it with unaffected fellow eye. They found that there was no significant difference between the two eyes. They hypothesized that this characteristic may help in the differential diagnosis with serpiginous choroiditis, where there are severe atrophic changes in retina as well as in the choroid. This relative sparing of the choroid in RPC may be related to the degree of the inflammatory reaction on the tissue. (71)

Oral/ intravitreal/periocular steroids and various immunomodulatory and biologic agents have been used to treat RPC either alone or in combination.(69,72,73) Zaheer et al in their case series noted that relapses of RPC were found among patients on MMF and interferon-alpha-2a and they concluded that the use of anti-TNF-alpha (adalimumab, infliximab) treatment and anti-IL-6 tocilizumab may be useful to obtain quiescence of RPC.(63)

## References

1. Crawford CM, Igboeli O. A review of the inflammatory chorioretinopathies: the white dot syndromes. *International Scholarly Research Notices*. 2013;2013.
2. Herbort CP Jr, Mantovani A, Tugal-Tutkun I, Papasavvas I (2021) Classification of Non-Infectious and/or Immune Mediated Choroiditis: A Brief Overview of the Essentials. *Diagnostics (Basel)* 11(6):939.
3. Papasavvas I, Mantovani A, Tugal-Tutkun I, Herbort CP Jr. Multiple evanescent white dot syndrome (MEWDS): update on practical appraisal, diagnosis and clinicopathology; a review and an alternative comprehensive perspective. *J Ophthalmic Inflamm Infect*. 2021 Dec 18;11(1):45.
4. Pichi F, Srivastava SK, Chexal S, et al. En face optical coherence tomography and optical coherence tomography angiography of multiple evanescent white dot syndrome: new insights into pathogenesis. *Retina*.2016;36(suppl 1):S178eS188)
5. Pereira F, Lima LH, de Azevedo AGB, Zett C, Farah ME, Belfort R Jr (2018) Swept-source OCT in patients with multiple evanescent white dot syndrome. *J Ophthalmic Inflamm Infect* 8(1):16.
6. Yannuzzi NA, Swaminathan SS, Zheng F, Miller A, Gregori G, Davis JL, Rosenfeld PJ (2017) Swept-source OCT angiography shows sparing of the Choriocapillaris in multiple evanescent white dot syndrome. *Ophthalmic Surg Lasers Imaging Retina* 48(1):69–74.
7. Marsiglia M, Gallego-Pinazo R, Cunha de Souza E et al (2016) Expanded clinical spectrum of multiple evanescent white dot syndrome with multimodal imaging. *Retina* 36(1):64–74
8. Zicarelli F, Mantovani A, Preziosa C, Staurenghi G (2020) Multimodal imaging of multiple evanescent white dot syndrome: a new interpretation. *Ocul Immunol Inflamm* 28(5):814–820
9. Labriola, L.T., Legarreta, A.D., Legarreta, J.E., Nadler, Z., Gallagher, D., Hammer, D.X., Ferguson, R.D., Iftimia, N., Wollstein, G., Schuman, J.S., 2016. Imaging with multimodal adaptive-optics optical coherence tomography in multiple evanescent white dot syndrome: the structure and functional relationship. *Retin. Cases Brief Rep*. 10, 302–309.
10. Onishi, A.C., Roberts, P.K., Jampol, L.M., Nesper, P.L., Fawzi, A.A., 2019. Characterization and correlation of "Jampol dots" on adaptive optics with foveal granularity on conventional fundus imaging. *Retina* 39, 235–246.
11. Spaide, R.F., Lally, D.R., 2021. High resolution spectral domain optical coherence tomography of multiple evanescent white dot syndrome. *Retin. Cases Brief Rep*.
12. Lages V, Mantovani A, Papadia M, Herbort CP. MEWDS is a true primary choriocapillaritis and basic mechanisms do not seem to differ from other choriocapillaritis entities. *J Curr Ophthalmol*. 2018 Nov 15;30(4):281-286.
13. Khochtali S, Dridi T, Abroug N, Ksiao I, Lupidi M, Khairallah M (2020) Swept-Source Optical Coherence Tomography Angiography Shows Choriocapillaris Flow Reduction in Multiple Evanescent White Dot Syndrome. *J Curr Ophthalmol* 32(2):211–215
14. Wang JC, Laíns I, Sobrin L, Miller JB (2017) Distinguishing white dot syndromes with patterns of choroidal Hypoperfusion on optical coherence tomography angiography. *Ophthalmic Surg Lasers Imaging Retina* 48(8):638–646.
15. Cicinelli MV, Hassan OM, Gill MK, Goldstein D, Parodi MB, Jampol LM (2021) A multiple evanescent white dot syndrome-like reaction to concurrent retinal insults. *Ophthalmol Retina* 5(10):1017–1026
16. Gliem M, Birtel J, Muller PL et al (2019) Acute retinopathy in pseudoxanthoma elasticum. *JAMA Ophthalmol* 137(10):1165–1173
17. Mathis T, Delaunay B, Cahuzac A, Vasseur V, Mauget-Faysse M, Kodjikian L (2018) Choroidal neovascularisation triggered multiple evanescent white dot syndrome (MEWDS) in predisposed eyes. *Br J Ophthalmol* 102(7):971–976
18. Burke TR, Addison PKF, Pavesio CE (2022) Multifocal evanescent white dot syndrome-like phenotypes associated with inflammatory and myopic choroidal neovascularization. *Ocul Immunol Inflamm* 30(7–8):1707–1714
19. Ong AY, Birtel J, Charbel Issa P (2021) Multiple evanescent white dot syndrome (MEWDS) associated with progression of lacquer cracks in high myopia. *Klin Monatsbl Augenheilkd* 238(10):1098–1100
20. Essilfie J, Bacci T, Abdelhakim AH et al (2022) Are there two forms of multiple evanescent white dot syndrome? *Retina* 42(2):227–235

21. Testi I, Vermeirsch S, Pavesio C. Acute posterior multifocal placoid pigment epitheliopathy (APMPPE). *J Ophthalmic Inflamm Infect*. 2021 Nov 1;11(1):31.
22. Saleh M (2020 Feb) Placoid pigment epitheliopathy and serpiginous choroiditis. *J Fr Ophthalmol* 43(2):e55–e66.
23. Branisteanu D, Bilha A, Rom J (2015) Acute posterior multifocal placoid pigment epitheliopathy following influenza vaccination. *Ophthalmol*. 59(1):52–58
24. Gonome T, Suzuki Y, Metoki T, Takahashi S, Nakazawa M (2016) Acute posterior multifocal placoid pigment epitheliopathy and granulomatous uveitis following influenza vaccination. *Am J Ophthalmol Case Rep* 4:60–63.
25. R. Dolz-Marco, D. Sarraf, V. Giovinazzo, and K. B. Freund, "Optical coherence tomography angiography shows inner choroidal ischemia in acute posterior multifocal placoid pigment epitheliopathy," *Retinal Cases & Brief Reports*, vol. 11, pp. S136–S143, 2017.
26. T.R. Burke, C.J. Chu, S. Salvatore et al., "Application of OCT angiography to characterise the evolution of chorioretinal lesions in acute posterior multifocal placoid pigment epitheliopathy," *Eye*, vol. 31, no. 10, pp. 1399–1408, 2017.
27. R. Kinouchi, N. Nishikawa, A. Ishibazawa, and A. Yoshida, "Vascular rarefaction at the choriocapillaris in acute posterior multifocal placoid pigment epitheliopathy viewed on OCT angiography," *International Ophthalmology*, vol. 37, no. 3, pp. 733–736, 2017
28. A. Y. Zhang, I. C. Han, and M. F. Goldberg, "Renaming of acute posterior multifocal placoid pigment epitheliopathy (APMPPE) to acute multifocal placoid choroidopathy (AMPC)," *JAMA Ophthalmology*, vol. 135, no. 3, p. 185, 2017
29. Oliveira MA, Simão J, Martins A, Farinha C. Management of Acute Posterior Multifocal Placoid Pigment Epitheliopathy (APMPPE): Insights from Multimodal Imaging with OCTA. *Case Rep Ophthalmol Med*. 2020 Mar 13;2020:7049168.
30. Papasavvas I, Mantovani A, Herbort CP Jr. Acute Posterior Multifocal Placoid Pigment Epitheliopathy (APMPPE): A Comprehensive Approach and Case Series: Systemic Corticosteroid Therapy Is Necessary in a Large Proportion of Cases. *Medicina (Kaunas)*. 2022 Aug 8;58(8):1070.
31. Xerri O, Salah S, Monnet D, Brézin AP. Untreated Acute Posterior Multifocal Placoid Pigment Epitheliopathy (APMPPE): a case series. *BMC Ophthalmol*. 2018 Mar 20;18(1):76.
32. Thomas BC, Jacobi C, Korporal M, Becker MD, Wildemann B, Mackensen F. Ocular outcome and frequency of neurological manifestations in patients with acute posterior multifocal placoid pigment epitheliopathy (APMPPE). *J Ophthalmic Inflamm Infect*. 2012 Sep;2(3):125-31.
33. Jones NP. The Manchester uveitis clinic: The first 3000 patients – epidemiology and casemix. *Ocul Immunol Inflamm* 2015;23:118-26.
34. Fanlo P, Heras H, Pérez D, Tiberio G, Espinosa G, Adan A, et al. Profile of patients with uveitis referred to a multidisciplinary unit in Northern Spain. *Arch Soc Esp Oftalmol* 2017;92:202-9
35. Rahman Z, Ahsan Z, Rahman NA, Dutta Majumder P. Pattern of uveitis in a referral hospital in Bangladesh. *Ocul Immunol Inflamm* 2018;26:893-6.
36. Llorenç V, Mesquida M, Sainz de la Maza M, Keller J, Molins B, Espinosa G, et al. Epidemiology of uveitis in a Western urban multiethnic population. The challenge of globalization. *Acta Ophthalmol* 2015;93:561-7
37. Providência J, Fonseca C, Henriques F, Proença R. Serpiginous choroiditis presenting after SARS-CoV-2 infection: a new immunological trigger? *Eur J Ophthalmol*. (2022) 32(1):Np97–Np101.
38. Dutta Majumder P, Biswas J, Gupta A. Enigma of serpiginous choroiditis. *Indian J Ophthalmol*. 2019 Mar;67(3):325-333.
39. Bansal R, Sharma K, Gupta A, Sharma A, Singh MP, Gupta V, et al. Detection of Mycobacterium tuberculosis genome in vitreous fluid of eyes with multifocal serpiginoid choroiditis. *Ophthalmology* 2015;122:840-50.
40. Tagirasa R, Parmar S, Barik MR, Devadas S, Basu S. Autoreactive T cells in immunopathogenesis of TB
41. Gilbert RM, Niederer RL, Kramer M, Sharief L, Sharon Y, Bar A, Lightman S, Tomkins-Netzer O. Differentiating Multifocal Choroiditis and Punctate Inner Choroidopathy: A Cluster Analysis Approach. *Am J Ophthalmol*. 2020 May;213:244-251.
42. Cicinelli MV, Ramtohul P, Marchese A, Bandello F, Bailey Freund K, Miserocchi E, Jampol LM. Latest advances in white spot syndromes: New findings and interpretations. *Prog Retin Eye Res*. 2023 Nov;97:101207.


43. Spaide RF, Goldberg N, Freund KB. Redefining multifocal choroiditis and panuveitis and punctate inner choroidopathy through multimodal imaging. *Retina*. 2013 Jul-Aug;33(7):1315-24.
44. Abdelhakim, A.H., Yannuzzi, L.A., Freund, K.B., Jung, J.J., 2021. Differential response to glucocorticoid immunosuppression of two distinct inflammatory signs associated with punctate inner choroidopathy. *Retina* 41, 812–821.
45. Zarranz-Ventura, J., Sim, D.A., Keane, P.A., Patel, P.J., Westcott, M.C., Lee, R.W., Tufail, A., Pavesio, C.E., 2014. Characterization of punctate inner choroidopathy using enhanced depth imaging optical coherence tomography. *Ophthalmology* 121, 1790–1797.
46. Zahid, S., Chen, K.C., Jung, J.J., Balaratnasingam, C., Ghadiali, Q., Sorenson, J., Rofagha, S., Freund, K.B., Yannuzzi, L.A., 2017. Optical coherence tomography angiography of chorioretinal lesions due to idiopathic multifocal choroiditis. *Retina* 37, 1451–1463.
47. Baumal, C.R., de Carlo, T.E., Waheed, N.K., Salz, D.A., Witkin, A.J., Duker, J.S., 2015. Sequential optical coherence tomographic angiography for diagnosis and treatment of choroidal neovascularization in multifocal choroiditis. *JAMA Ophthalmol*. 133, 1087–1090.
48. Duthheil, C., Korobelnik, J.F., Delyfer, M.N., Rougier, M.B., 2018. Optical coherence tomography angiography and choroidal neovascularization in multifocal choroiditis: a descriptive study. *Eur. J. Ophthalmol*. 28, 614–621.
49. Nakao, S., Kaizu, Y., Oshima, Y., Sakamoto, T., Ishibashi, T., Sonoda, K.H., 2016. Optical coherence tomography angiography for detecting choroidal neovascularization secondary to punctate inner choroidopathy. *Ophthalmic Surg. Lasers Imag. Retina* 47, 1157–1161.
50. Thompson, I.A., Caplash, S., Akanda, M., Sabbagh, O., Choan, B., Cheng, S.K., Okeagu, C., Sen, H.N., 2021. Optical coherence tomography angiography changes in choroidal vasculature following treatment in punctate inner choroidopathy. *Ocul. Immunol. Inflamm*. 29, 944–950.
51. Cicinelli, M.V., Marchese, A., Ramtohul, P., Miserocchi, E., Introini, U., Bandello, F., Freund, K.B., Battaglia Parodi, M., 2022a. Punctate inner choroidopathy-like reactions in unrelated retinal diseases. *Retina* 42, 2099–2109.
52. Roy R, Dutta Majumder P. Current understanding of acute zonal occult outer retinopathy (AZOOR). *Indian J Ophthalmol*. 2024 Mar 8.
53. Wang M, Sadaka A, Prager T, Lee AG, Pellegrini F, Cirone D, De Simone L, Cimino L. From A... to... Z(OOR): The Clinical Spectrum of Acute Zonal Occult Outer Retinopathy. *Neuroophthalmology*. 2017 Dec 21;42(4):215-221.
54. Mrejen, S., Khan, S., Gallego-Pinazo, R., Jampol, L.M., Yannuzzi, L.A., 2014. Acute zonal occult outer retinopathy: a classification based on multimodal imaging. *JAMA Ophthalmol*. 132, 1089–1098.
55. Özyol E, Özyol P. Acute zonal occult outer retinopathy: optical coherence tomography angiography findings and treatment response. *GMS Ophthalmol Cases*. 2022 Jun 9;12:Doc16
56. Xu, Q.A., Athwal, A., Heisler, M., Ju, M.J., Vanzan, V., Ferrara, D., Sarunic, M., Navajas, E.V., 2022. Adaptive optics optical coherence tomography in a case of acute zonal occult outer retinopathy. *Retin. Cases Brief Rep*. 16, 435–438
57. Nakao, S., Kaizu, Y., Yoshida, S., Iida, T., Ishibashi, T., 2015. Spontaneous remission of acute zonal occult outer retinopathy: follow-up using adaptive optics scanning laser ophthalmoscopy. *Graefes Arch. Clin. Exp. Ophthalmol*. 253, 839–843.
58. Marchese, A., Agarwal, A.K., Erba, S., Scialdone, A., Miserocchi, E., Bandello, F., Introini, U., Jampol, L.M., Casalino, G., 2022. Placoid lesions of the retina: progress in multimodal imaging and clinical perspective. *Br. J. Ophthalmol*. 106, 14–25.
59. Cicinelli, M.V., Marchese, A., Bordato, A., Manitto, M.P., Bandello, F., Battaglia Parodi, M., 2020b. Reviewing the role of ultra-widefield imaging in inherited retinal dystrophies. *Ophthalmol. Ther*. 9, 249–263.
60. Introini U, Casalino G, Dhrami-Gavazi E, Mukkamala SK, Mrejen S, Schubert H, Cohen SY, Azzolini C, Bandello F, Chang S, Yannuzzi LA. Clinical course of acute zonal occult outer retinopathy complicated by choroidal neovascularization. *Int J Retina Vitreous*. 2018 Aug 29;4:32.
61. Vadboncoeur, J., Jampol, L.M., Goldstein, D.A., 2022. Acute zonal occult outer retinopathy: a case report of regression after an intravitreal dexamethasone (ozurdex) implant. *Retin. Cases Brief Rep*. 16, 466–469.

62. Lin, B.R., Russell, J.F., Al-Kharsan, H., Goldhardt, R., 2022. A systematic review of acute zonal occult outer retinopathy with a focus on attempted treatment modalities. *Curr. Ophthalmol. Rep.* 10, 168–178.
63. Zaheer HA, Odden J, Gagrani M, Zaguia F, Lowder C, Coca A, Rosenkranz ME, Patil-Chhablani P, Ores R, BouSSION F, Indermill C, Sahel JA, Nischal K, Goldstein DA, Errera MH. Relentless placoid chorioretinitis: A review of four cases in pediatric and young adult patients with a discussion of therapeutic strategies. *Front Pediatr.* 2023 Mar 27;11:885230.
64. Mebsout-Pallado C, Ores R, Terrada C, Dansingani KK, Chhablani J, Eller AW, et al. Review of the current literature and our experience on the value of OCTangiography in white dot syndromes. *Ocul Immunol Inflamm.* (2022) 30(2):364–78.
65. Hwang ES, Bell JE, Quigley EP, Hoesch RE, Shakoor A. Stroke due to cerebral vasculitis in a patient with relentless placoid chorioretinitis. *Ocul Immunol Inflamm.* (2018) 26(6):921–3.
66. Tom ES, McKay KM, Saraf SS. Bilateral ampiginous choroiditis following presumed SARS-CoV-2 infection. *Case Rep Ophthalmol Med.* (2021) 2021:1646364.
67. Testi I, Brandao-de-Resende C, Agrawal R, Pavesio C, Group C-VOIES. Ocular inflammatory events following COVID-19 vaccination: a multinational case series. *J Ophthalmic Inflamm Infect.* (2022) 12(1):4.
68. Olguín-Manríquez F, Cernichiaro-Espinosa L, Olguín-Manríquez A, ManríquezArias R, Flores-Villalobos EO, Kawakami-Campos PA. Unilateral acute posterior multifocal placoid pigment epitheliopathy in a convalescent COVID-19 patient. *Int J Retina Vit.* (2021) 7(1):41.
69. Uraki T, Namba K, Mizuuchi K, Iwata D, Ohno S, Kitaichi N, Ishida S. Cyclosporine and prednisolone combination therapy as a potential therapeutic strategy for relentless placoid chorioretinitis. *Am J Ophthalmol Case Rep.* 2019 Mar 23;14:87–91.
70. Klufas MA, Phasukkijwatana N, Iafe NA, Prasad PS, Agarwal A, Gupta V, et al. Optical coherence tomography angiography reveals choriocapillaris flow reduction in placoid chorioretinitis. *Ophthalmol Retina.* (2017) 1(1):77–91.
71. Dolz-Marco R, Rodríguez-Ratón A, Hernández-Martínez P, Pascual-Camps I, Andreu-Fenoll M, Gallego-Pinazo R. Macular retinal and choroidal thickness in unilateral relentless placoid chorioretinitis analyzed by swept source optical coherence tomography. *J Ophthalmic Inflamm Infect.* 2014 Oct;4(1):24.
72. Asano S, Tanaka R, Kawashima H, Kaburaki T. Relentless placoid chorioretinitis: a case series of successful tapering of systemic immunosuppressants achieved with Adalimumab. *Case Rep Ophthalmol.* (2019) 10(1):145–52.
73. Roth DB, Ballentine S, Mantopoulos D, Prenner J, Fine HF. Relentless placoid chorioretinitis: successful long-term treatment with intravitreal triamcinolone. *Retin Cases Brief Rep.* (2019) 13(2):150–3.

# Joining the Dots: Crossword



**Dr. Aditya Patil** DNB, FAICO  
 Consultant, Crystal Eye Centre, Mumbai  
*adi.pat009@yahoo.com*



## Across

3. This entity is no longer considered to be a part of White dot syndromes but rather a vascular disorder.
6. Linear streaks in midperiphery seen in PIC and idiopathic MFC.
7. Newly described phenotype of idiopathic MFC named after a flower.
8. White dot syndrome with normal choriocapillaris OCTA study.
9. Cerebral vasculitis is a dreaded association of this entity.
10. Common and important differential of infectious etiology in a case that appears like PIC.

## Down

1. Most common complication in PIC.
2. Characteristic autofluorescence pattern in late stage of AZOOR.
3. On blue AF, zone 3 in AZOOR is characterized by RPE \_\_\_\_\_.
4. Strong HLA association has been established in this bilateral disease.
5. Eponymous term for Acute retinal pigment epitheliitis.

# The Last Word: Clinical Cues and Imaging Algorithm



**Dr. Aniruddha Agarwal, MD PhD FICO**

Associate Staff Physician, Eye Institute Cleveland Clinic Abu Dhabi

Al Maryah Island, Abu Dhabi, UAE

Department of Ophthalmology, Cleveland Clinic Lerner College of Medicine of Case Western Reserve University, Cleveland, Ohio, USA

[aniruddha9@gmail.com](mailto:aniruddha9@gmail.com)

*T*he reader of this information-packed Uveitis Society of India (USI) newsletter must be well versed with the term 'White Dot Syndromes' (WDS), simply an umbrella term that encompasses all the white-grey-yellow lesions that are round-to-oval in shape scattered in the fundus, irrespective of their primary site of inflammation, pathogenesis, or natural history/complications. Herein lies the challenge in the usage of the term WDS, alternatively termed as 'White Spot Syndrome'. Historically, the term was introduced by Jampol et al to describe multiple evanescent white dot syndrome (MEWDS). However, since then, this term widely spread and encompassed several entities due to a complex interplay of autoimmune factors and often overlapping clinical appearances in different stages of the disease.

More recently, there has been a trend in the literature to decrease the emphasis on the term WDS and instead, address the individual entities by their own terms avoiding excessive overlapping. Multimodal imaging, to a great extent, has aided this

because with the help of several imaging modalities, it has become easier to define the distinguishing features of these entities and categorize them objectively. In the previous manuscripts published in this newsletter on entities such as MEWDS, serpiginous choroiditis (SC), multifocal choroiditis (MFC) and punctate inner choroidopathy (PIC), among others, it is evident that the diagnosis of these entities is primarily clinical, heavily relying on the morpho-anatomical changes rather than on the laboratory testing [except in the case of birdshot chorioretinopathy where human leucocyte antigen (HLA) A29 is relevant]. One caveat that should be added here is that other infectious/inflammatory diseases that mimic WDS must be sufficiently ruled out, including ocular tuberculosis, syphilis, and sarcoidosis, among others. In general, once a thorough clinical examination, basic laboratory investigations, and a minimal set of imaging which may include optical coherence tomography (OCT), fundus photography, autofluorescence (FAF), and dye-based angiographies such as fluorescein (FA) and indocyanine green

(ICGA), it may be sufficient to categorize the disease into one of the phenotypes.

Table 1 enlists various entities that have often been clubbed under the umbrella term of WDS, including rare diseases that may not be separately elaborated in this newsletter.

<b>Table 1: Entities included under the term ‘white dot syndromes’</b>	
Choriocapillaritis with discreet lesions	Multiple evanescent white dot syndrome (MEWDS) Multifocal choroiditis (MFC) Punctate inner choroidopathy (PIC) Presumed ocular histoplasmosis syndrome (POHS)
Choriocapillaritis with larger lesions	Acute posterior multifocal placoid pigment epitheliopathy (APMPPE) <b>placoid</b> Relentless placoid chorioretinopathy <b>placoid</b> Serpiginous choroiditis (SC) <b>serpentine</b>
Choroidal stromal diseases	Birdshot chorioretinopathy Vogt-Koyanagi-Harada disease (VKH) Sympathetic ophthalmia (SO)
Predominantly retinal/retinal epithelial diseases	Acute zonal occult outer retinopathy (AZOOR) Acute macular neuroretinopathy (AMN) Acute retinal pigment epitheliitis (ARPE) Subretinal fibrosis and uveitis (SFU)

For diagnosing WDS, two factors that play an important role are: (1) lesion evolution, and (2) time. In entities such SC and acute posterior multifocal placoid pigment epitheliopathy (APMPPE), the evolution of the lesions with time may result in changing the diagnosis especially if the disease is detected very early. SC lesions tend to grow in serpentine manner with a progressive edge, whereas APMPPE form a placoid pattern. Further, entities such as relentless placoid chorioretinitis is characterized by progressive chorioretinal involvement (creeping choroiditis), extensive scarring, retinal pigment epithelial (RPE) hypertrophy/atrophy, and near-complete destruction over time despite systemic immunosuppression. Therefore, these factors must be considered when the diagnosis is being considered.

The Standardized Uveitis Nomenclature (SUN) working group has recently provided the diagnostic criteria for various WDS using case selections and machine learning

approach to distinguish entities from other closely resembling conditions. The SUN criteria focused on the clinical picture and associated imaging findings, with supportive laboratory data for entities such as SC, MFC, PIC, MEWDS, among others. These criteria are valuable in clinical setting to help segregate the patient into one of the diseases and initiate appropriate therapy, considering the long-term prognosis and biological behaviour of the disease. However, one must be cautious since certain obscure entities (that were not compared when SUN criteria were established) may mimic these disease definitions (for instance some forms of Vogt-Koyanagi-Harada disease may resemble APMPPE with subretinal fluid accumulation). Therefore, the clinicians must be careful in interpreting and applying these criteria considering that none of the published criteria are fool proof.

The course of the diseases included in the WDS group can range from self-limiting with complete resolution (MEWDS) to recurrent and sight-threatening conditions (MFC). The “white lesions” are inflammatory in all the conditions; however, their shape, size, distribution, and imaging features are variable and can help in the differential diagnosis. In order to avoid misdiagnosis and confusion, it is important to summarize key clinical features of each of these major entities as below:

**A. Serpiginous choroiditis:** Paucifocal/multifocal ameboid/serpentine lesions with absent or minimal anterior chamber/vitreous inflammation, and early hypofluorescence with late hyperfluorescence on FA

**B. Multiple evanescent white dot syndrome:** Multifocal grey-white spots with foveal granularity, ‘wreath-like’ hyperfluorescence on FA, hyper-reflective lesions on OCT from RPE to ellipsoid/outer nuclear layer, and absent/minimal anterior chamber/vitreous inflammation

**C. Acute posterior multifocal placoid pigment epitheliopathy:** Paucifocal/multifocal plaque-like lesions (compare this to SC), with early hypofluorescence and late hyperfluorescence on FA.

**D. Multifocal choroiditis with panuveitis:** Multifocal round-to-oval lesions more than 125 microns, with punched-out atrophic scars or active lesions with minimal vitreous inflammation (possible posterior and/or peripheral involvement).

**E. Punctate inner choroidopathy:** Multifocal punctate choroidal lesions less than 250 microns, posterior pole involvement, and absent anterior chamber/vitreous inflammation

**F. Birdshot Choroidopathy:** ‘Birdshot’ lesions (multifocal cream-yellow round/oval lesions in the peripapillary area), absent/

minimal anterior chamber or vitreous inflammation, positive HLA A29 testing, and multifocal hypofluorescent spots on ICGA.

The approach to the diagnosis of these entities is as follows:

### **Step 1: Clinical assessment and fundus photography:**

As described in the preceding paragraphs, the first step towards the approach of establishing the correct diagnosis is proper clinical examination and documentation of the chorioretinal lesions, focusing on the following parameters:

- Size, shape
- Edges, margins, and depth of the lesion
- Presence of associated anterior chamber/vitreous inflammation
- Location of the lesions (posterior pole/periphery)
- Progression/active edge/healing pattern and pigmentation of the RPE

### **Step 2: Fundus autofluorescence and optical coherence tomography**

Initial fundus imaging using both FAF and OCT is valuable in establishing the right diagnosis and assessing the disease activity and complications. In MEWDS, the OCT reveals disruption of the outer retinal layers between the outer nuclear layer and the interdigitation zone with a normal-looking RPE, distinguishing this from MFC, where active lesions show a hyper-reflective dome-shaped structure that continues through the RPE into the outer retinal layers. APMPE shows thickening of the choriocapillaris with extensive RPE changes during the healing stage, and disruption of the outer retinal layers. SC shows changes similar to APMPE, but the FAF in SC is characteristic due to the healing pattern and the hyper-autofluorescent serpentine edges.

### **Step 3: Fluorescein and indocyanine green angiography**

The dye-based angiographies have a distinct role in diagnosing and monitoring WDS entities due to their characteristic appearances as outlined by various authors in the literature, and also elucidated by the SUN classification criteria. In general, ICGA has an important place in the diagnosis of WDS since several entities involve the choriocapillaris and the deeper choroid. Thus, early and late phases of the ICGA are critical in understanding the disease and its pathogenesis. In MFC, the active lesions are homogeneously hypofluorescent. The active lesions of APMPPE are hypofluorescent on ICGA both in the early and late phases when they become more evident. MEWDS lesions are usually hypofluorescent on ICGA and become very evident in the late phases. Birdshot chorioretinopathy shows characteristic multifocal hypofluorescent spots on ICGA, which may not be visible on clinical fundus photography. In birdshot chorioretinopathy, the hypofluorescent ICGA infiltrates decrease in number with appropriate systemic steroidal or immunosuppressive treatment. Thus, performing FA and ICGA provides numerous insights into the disease classification.

### **Other tools: Optical coherence tomography angiography (OCTA), near infra-red imaging, and en face imaging**

OCTA may have a role in helping to establish a diagnosis, but it is possibly a non-essential imaging examination. In MEWDS, OCTA has an important role as it shows normal choriocapillaris perfusion despite

hypofluorescent lesions on ICGA. On the other hand, OCTA shows dark dots in MFC, APMPPE and SC, distinguishing it from MEWDS. OCTA can be useful in assessing the retinal and choroidal microvascular compromise in conditions such as birdshot chorioretinopathy and SC.

OCTA is very sensitive in diagnosing choroidal neovascularization, which may be missed on routine ICGA. However, it is important to distinguish between normal choroidal vessels that become more prominent due to overlying choriocapillaris atrophy from abnormal neovascular networks on OCTA.

### **Summary and Conclusions**

The term WDS, which has been loosely applied as an umbrella term for various entities presenting with chorioretinal inflammation, has gathered lesser importance with time. In the present era of multimodal imaging, identification of individual entities has become an important part of clinical assessment and evaluation, and greatly helps the clinician in deciding the therapeutic approach. Earlier detection and disease classification helps in prognosticating the disease. In 2024, various groups, such as the International Uveitis Study Group (IUSG), are working to establish a consensus guideline for the appropriate imaging-based diagnosis of various entities included in the term 'WDS'.

## Suspected White Dot Syndrome Stepwise Approach

*Color Fundus Photo*



Possibilities: Foveal granularity (MEWDS); Multiple punched out lesions (MFC/PIC); Large creamy deep lesions (APMPPE)



*Fundus Autofluorescence and OCT*



Possibilities: Hyper-FAF lesions with intact RPE (MEWDS); Hypo-FAF lesions with hyper-FAF edge, hyper-reflective lesions in the outer retina (MFC/PIC); Patchy hyper/hypo-FAF lesions with RPE affection (APMPPE)



*FA, ICGA and OCTA*



Possibilities: Hypo to hypo on ICGA and normal OCTA (MEWDS); Hypo to hypo/iso on ICGA (MFC/PIC); Hypo to hypo on ICGA, loss of perfusion on OCTA (APMPPE)

# You Make Us Proud: Awards and Certifications

## EUVRE USICON 2023 - ABU DHABI, UAE

**Dr. G Venkataswamy Endowment Award- 2023**  
Dr. Sudha K Ganesh, Sankara Nethralaya, Chennai

---

**Prof. Amod Gupta Young Researcher Award**  
Dr. Samendra Karkhur, AIIMS Bhopal, Madhya Pradesh

---

**Dr. Narsing A Rao Award for Best Paper**  
Dr. Aditya Patil, Narayana Nethralaya, Bengaluru  
*SIMCO Study*

---

**Dr. Carl Herbort Travel Award**  
Dr. Sharanya Abraham, Sankara Nethralaya, Chennai  
*Tofacitinib in treatment-resistant uveitis in children*

---

**Dr. Carl Herbort Travel Award**  
Dr. Mayur R Moreker, Bombay Hospital Institute Of Medical Sciences, Mumbai  
*Post-fever uveo-retinal syndrome*

---

**Poster Presentation – 1<sup>st</sup> Prize**  
Dr. Sheeja Susan John, Christian Medical College, Vellore  
*Role of Psychological Stress in Non-infectious Uveitis*

---

**Poster Presentation – 2<sup>nd</sup> Prize**  
Dr. Reema Bansal, PGIMER, Chandigarh  
*A rare case of Azathioprine-(AZA) induced Alopecia totalis  
and pancytopenia in a child with bilateral panuveitis:  
Genetic predisposition due to NUDT15 mutation*

---

**Rapid Fire presentation– 1<sup>st</sup> Prize**  
Dr. Sashwanthi Mohan, Medcare Eye Centre, Dubai  
*Vascular Tango: A rare association of paracentral acute  
middle maculopathy with Behcet Disease*

---

**Rapid Fire presentation– 2<sup>nd</sup> Prize**  
Dr. Vishal Jadhav, L V Prasad Eye Institute, Bhubaneswar  
*Bilateral PORN with coexistent bilateral extensive optic neuropathy*

Dr. Jyotirmay Biswas, Sanakara Nethralaya, Chennai  
**AIOS Lifetime Achievement Award - 2023**

---

Dr. S. R. Rathinam, Aravind Eye Hospital, Madurai,  
**Best of IJO, 2023 for the original article: Leptospiral uveitis-  
"Transition from epidemic to endemic form" difficulties in laboratory confirmation**  
**Dr. KGR Nair Oration Award from Trivandrum Ophthalmic Club, 2024.**

---

Dr. Vishali Gupta, Advanced Eye Centre, PGIMER, Chandigarh,  
**C S Grover Oration Award at Uttarakhand Annual Conference 2023**

---

Dr. Anita Agarwal, West Coast Retina, San Francisco  
**1st Prof. Amod Gupta RFR Mentor of the Year Oration at the RISHI meeting and the  
Retina Fellows Retreat, Chandigarh. April 2024**

---

Dr. Reema Bansal, PGIMER, Chandigarh,  
**International Hero, AIOS 2024**

---

Dr. Kasturi Chavan, L V Prasad Eye Institute  
**Certificate of merit, AIOS ophthalmic photography competition  
on the occasion of World Sight Day 2023**

---

Dr. Natasha Radhakrishnan, Amrita Institute, Kochi,  
**Woman in Leadership award, Womens ophthalmology society  
for distinguished women ophthalmology leaders of India**  
**Distinguished Teacher of India award  
by the Federation of Ophthalmic Teachers of India**

---

Dr. Vishal Jadhav, L V Prasad Eye Institute  
**APAO-APOIS image winner, APAO 2024 Category- "Gateway to health system"  
Image titled- Cherry on the spot- multimodal imaging in glycogen storage disorder**

---

Dr. Vidya Mooss, Prabha Eye Clinic, Bengaluru  
**FAICO Uvea**

---

Dr. Ranju Kharel Sitaula  
**BP Koirala Lions Centre for Ophthalmic Studies, Institute of Medicine, Nepal  
Singapore Society of Ophthalmology Runner-Up for the Best Paper Award  
Dilemma's in Ophthalmology conference  
9<sup>th</sup> International Ophthalmology Congress, NHGEI Singapore**

# Get on Board: Uveitis Fellowship Opportunities

**Course:** Paediatric Retina and Uvea with hands on ROP screening and treatment along with uveitis diagnosis and treatment

**Institute:** Place of training: Vettom Eye Hospital, Kochi

**Duration:** 6 months

**Contact:** Dr. Natasha Radhakrishnan, 9496389999

---

**Course:** Post-doctoral fellowship course in Uveitis and Medical Retina

**Duration:** 2 years

**Institute:** Christian Medical College, Vellore

**Contact:** Dr. Sheeja Susan John (+91 9003938547), or registrar@cmcvellore.ac.in

---

**Course:** Long term fellowship in Uvea Subspeciality

**Duration:** 3 years

**Institute:** L V Prasad Eye Institute, Hyderabad,

**Contact:** Dr. Vishal Jadhav, LVPEI official website, LVPEI Education

---

**Course:** Fellowship mentored by Dr. Ranju Kharel Sitaula + Prof Sagun Narayan Joshi

**Duration:** 6 -12 months

**Institute:** BP Koirala Lions Centre for Ophthalmic Studies, Institute of Medicine, Nepal

**Contact:** bpkcos@gmail.com



To increase tear production in patients with dry eye

**Cequa**<sup>TM</sup>  
(cyclosporine ophthalmic solution) 0.09%

In Cataract and LASIK Surgery\*



**Milflodex**  
Moxifloxacin 0.5% + Dexamethasone 0.1% Eye Drops

A powerful anti-VEGF therapy to Enhance Visual Acuity

**OCEVA**<sup>TM</sup>  
Ranibizumab Solution for Injection 10 mg/mL - Vial 2.3mg/0.23mL

\*Data on File



# CMEs and Webinars under the Aegis of USI

**Uveitis Society (India)**  
WEBINAR (WEST ZONE)  
**OCULAR TOXOPLASMOSIS  
BASICS TO UPDATES**  
SUNDAY 18<sup>th</sup> JUNE 11.00 AM - 12.30 PM  
Expert: Dr. Jyotirmay Biswas  
Case Discussants: Dr. Minja C.K. (Bangalore), Dr. Avinash Pathangay (Hyderabad), Dr. Mayur Morekar (Mumbai), Dr. Partho Pratim D Majumder (Chennai)  
Journal Discussants: Dr. Mayur Morekar (Mumbai), Dr. Partho Pratim D Majumder (Chennai)  
Program Co-ordinators: Dr. Sanyak Mukherjee (Mumbai), Dr. Rohit Modi (Mumbai)

**Uveitis Society (India)**  
WEBINAR (North zone)  
**OCULAR TUBERCULOSIS**  
SUNDAY, 27<sup>th</sup> AUGUST 2023  
11.00 AM - 12.30 PM  
Experts: Prof. Anand Gupta (Chandigarh), Prof. Virendra Gupta (Chandigarh)  
Discussants: Dr. Saurabh Luthra (Delhi), Dr. Shashir Narain (Delhi), Dr. Vijay Pratap Singh Tomar (Shimla), Dr. Reema Bansal (Chandigarh)  
Moderators: Dr. Vijay Pratap Singh Tomar (Shimla), Dr. Reema Bansal (Chandigarh)

**Uveitis Society (India)**  
WEBINAR (South zone)  
**POST FEVER RETINITIS**  
SUNDAY, 19<sup>th</sup> NOVEMBER 2023  
11.00 AM - 12.30 PM  
Expert: Dr. Rathinam Sivakumar (Madurai)  
Discussants: Dr. Rohan Chawla (New Delhi), Dr. Ankush Kawali (Bangalore), Dr. Abhilasha Baharani (Hyderabad), Dr. Reesha K.R. (Angamaly)  
Moderators: Dr. Rohan Chawla (New Delhi), Dr. Ankush Kawali (Bangalore), Dr. Abhilasha Baharani (Hyderabad), Dr. Reesha K.R. (Angamaly)

**Uveitis Society (India)**  
WEBINAR Central Zone  
**VIRAL RETINITIS**  
Sunday 21<sup>st</sup> January 2024  
11.00 AM - 12.30 PM  
Expert: Dr. Jyotirmay Biswas (Chennai)  
Discussants: Dr. Kalpana Babu (Bangalore), Dr. Alay Banker (Ahmedabad), Dr. Ajok Sen (Chitrakoot)  
Moderators: Dr. Dhaivat Shah | Dr. Rashi Taori Sawal

**Uveitis Society (India)**  
WEBINAR East Zone  
**VKH Disease**  
Sunday 5<sup>th</sup> May 2024  
11.00 AM - 12.30 PM  
Expert: Dr. Jyotirmay Biswas  
Discussants: Dr. Amitabh Kumar, Dr. Dipankar Das, Dr. Santanu Mondal  
Moderators: Dr. Anindya K Majumder, Dr. Himedri Choudhury

**BENGAL UVEITIS SUMMIT 2023**  
Date: 24<sup>th</sup> December, 2023 (Sunday)  
Venue: Charaka Auditorium, Kolkata.




**IGNITE 2024 - KOCHI**  
Date: 14<sup>th</sup> January, 2024 (Sunday)  
Venue: Olive Downtown, Kochi



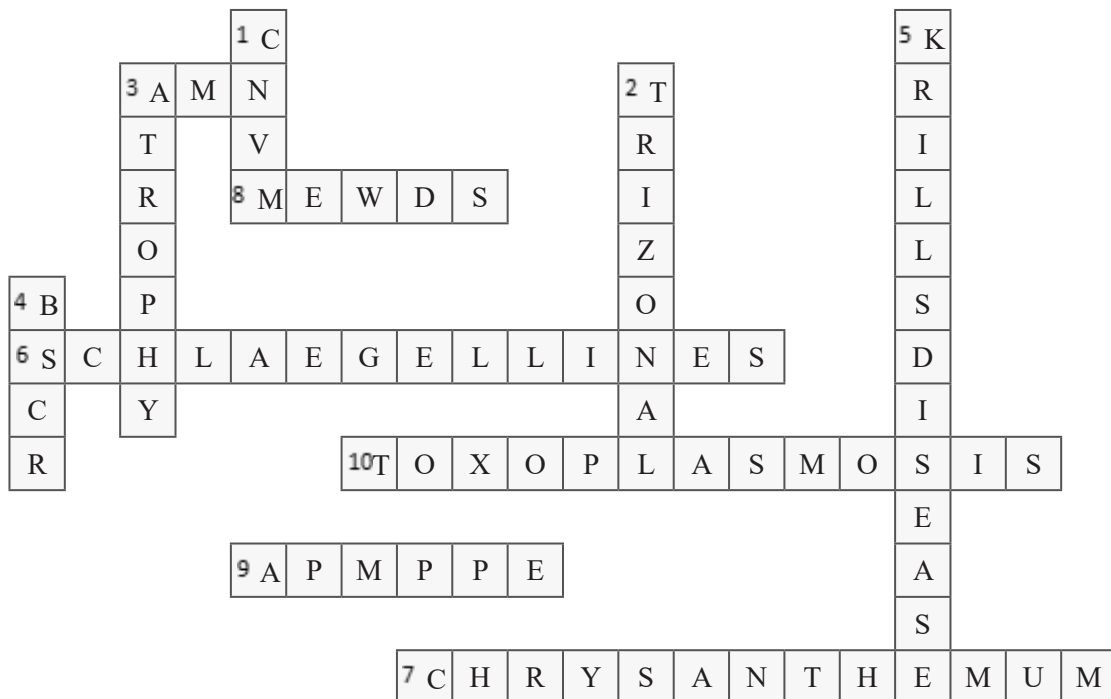


## Puzzle Answers

1. Serpiginous choroiditis
2. Punctate inner choroidopathy
3. AZOOR
4. APMPE
5. MEWDS



## Crossword Answers



### Across

3. This entity is no longer considered to be a part of White dot syndromes but rather a vascular disorder. (AMN)
6. Linear streaks in midperiphery seen in PIC and idiopathic MFC. (Schlaegellines)
7. Newly described phenotype of idiopathic MFC named after a flower. (Chrysanthemum)
8. White dot syndrome with normal choriocapillaris OCTA study. (MEWDS)
9. Cerebral vasculitis is a dreaded association of this entity. (APMPPE)
10. Common and important differential of infectious etiology in a case that appears like PIC. (Toxoplasmosis)

### Down

1. Most common complication in PIC. (CNVM)
2. Characteristic autofluorescence pattern in late stage of AZOOR. (Trizonal)
3. On blue AF, zone 3 in AZOOR is characterized by RPE \_\_\_\_\_. (Atrophy)
4. Strong HLA association has been established in this bilateral disease. (BSCR)
5. Eponymous term for Acute retinal pigment epitheliitis. (Krillsdisease)



Silver Jubilee Celebrations



Uveitis Society (India)



Advanced Eye Centre,  
PGIMER, Chandigarh.

# USICON 2024

25<sup>th</sup> Annual Conference of Uveitis Society (India)

4<sup>th</sup> - 6<sup>th</sup> October 2024, Chandigarh

Venue : The LaLiT, Chandigarh, India

[www.indianuveitis.org](http://www.indianuveitis.org)

## Organizing Committee USICON 2024

### Advisors

Prof. Amod Gupta  
Prof. Vishali Gupta

### Organizing Chairperson

Prof. Reema Bansal

### Organizing Secretaries

Dr. Deeksha Katoch  
Dr. Mohit Dogra

### Treasurer

Dr. Basavaraj Tigari

### Joint Organizing Secretary

Dr. Simar Rajan Singh

### President


Dr. Kalpana Babu

### Secretary

Dr. Sudharshan S

### Scientific Committee Chairperson

Dr. Somasheila Murthy



## Address for Communication



**Uveitis Society (India)**

C/O Hallmark Events, Maruthi ' 688, 1<sup>st</sup> Floor, 6<sup>th</sup> Main  
3<sup>rd</sup> Block, BEL layout, Vidyaranyapura, Bangalore - 560097

**Ph:** 080 - 23646880 | **Mob:** 9591732274 | 9845671462

**Email:** uveitissociety@gmail.com

*Designed by*



**[www.indianuveitis.org](http://www.indianuveitis.org)**

